BOSTON
MEDICAL LIBRARY

IN THE
Francis A. Countway
Library of Medicine
BOSTON

TUMORS OF THE COLON & RECTUM

TUMORS OF THE COLON & RECTUM

THEIR PATHOLOGY, DIAGNOSIS AND TREATMENT

BY

JEROME M. LYNCH, M.D.

Surgical Director, St. Bartholomew's Hospital, N. Y.

AND

JOSEPH FELSEN, M.D.

Attending Pathologist, St. Bartholomew's Hospital



BOSTON MEDICAL LIBRARY
IN THE
FRANCIS A. COUNTWAY
LIBRARY OF MEDICINE

PAUL B. HOEBER, INC.
NEW YORK · MCMXXV

BOSTON MEDICAL LIBRARY
IN THE
FRANCIS A. COUNTWAY
LIBRARY OF MEDICINE

Copyright, 1925
By Paul B. Hoeber, Inc.

Published November, 1925

Printed in the United States of America

16
J
3

To

MR. W. D. THORNTON

in appreciation of his
interest in this
work

PREFACE

The recognition of the frequent occurrence of unsuspected lesions in the colon and rectum has paralleled the recent advances in clinical medicine. A thorough study of every patient now includes an examination of a lower bowel. The roentgen ray and sigmoidoscope have supplemented a simple digital examination. The progress in this field, however, has up to the present been chiefly utilized by the specialist. It is our hope that the humble efforts put forth in this book will also appeal to the general practitioner, for he will always occupy a dominating position in the fields of curative and preventive medicine and will often be the sole arbiter of his patient's fate. To him we must look for an early diagnosis of tumors of the colon or rectum in order that we may attain greater success in their cure.

We have omitted a description of lymph-node involvement in the pathological specimens pictured in this book. Without a careful microscopical study of every grossly normal as well as pathological lymph-node draining a carcinomatous area of the large intestine, any statement as to the extent of lymphatic involvement would be misleading. Some examples of the difficulties involved are contained in the work of H. S. Clogg (*Practitioner*, Lond., 1904, lxii, and *Lancet*, Lond., 1908, ii), De Bovis (*Rev. de Chir.*, 1900, xxi, xxii), Hartmann (Travaux de Chirurgie (Chirurgie de l'Intestin, 1907), Pollard and Bilton (*Brit. M. J.*, Lond., 1904, i), Jamieson and Dobson (*Proc. Roy. Soc. Med.*, Lond., 1909, ii, iii). The extremely painstaking anatomical studies of the last two authors suggest that more emphasis be placed upon a careful dissection of *all* lymphatic vessels and nodes draining an affected area rather than that we attempt to rely upon gross or microscopic

examination. For this reason we have substituted in the text a detailed description of the lymphatics of the colon and rectum.

The specimens and case records, with few exceptions, are taken from the surgical and pathological departments of St. Bartholomew's Hospital. Most of the drawings were made directly from the mounted specimens and stained slides. Others were copied from gross and photomicrographs.

We wish to take this opportunity to express our appreciation of the services and cooperation rendered by Mr. John W. Fiske, superintendent of St. Bartholomew's Hospital, and Dr. Edward W. Jew, resident surgeon. To the publishers and their staff credit is due for solution of the many difficulties involved in publication; to Dr. Landsberg, artist, and Mr. Haggett, photographer, for their beautiful and painstaking work, and to Mr. Goldstein and Miss Burck of the laboratory staff for their care of the museum preparations.

Jerome M. Lynch
Joseph Felsen

New York, N. Y.
October, 1925.

CONTENTS

PAGE

PREFACE vii

CHAPTER

I. INTRODUCTION AND DEFINITION OF TERMS AND DEVELOPMENT OF THE COLON AND RECTUM 1

II. THE ANATOMY AND PHYSIOLOGY OF THE COLON AND RECTUM . 9
Descriptive Gross Anatomy. Applied Gross Anatomy. Microscopic Anatomy. Physiology.

III. PATHOLOGICAL ASPECTS OF PRIMARY EPITHELIAL TUMORS OF THE COLON AND RECTUM 31
Papilloma. Adenoma. Carcinoma. Melanoma.

IV. CLINICAL ASPECTS OF PRIMARY EPITHELIAL TUMORS OF THE COLON AND RECTUM 91
Benign Tumors. Carcinomata of the Colon and Rectum—Age, Sex, Etiology, Duration of Symptoms, Site and Extent of Tumor Mass, Symptoms and Signs, Diagnosis, Laboratory Aids, Roentgenology, Secondary Results.

V. THE SURGICAL TREATMENT OF PRIMARY EPITHELIAL TUMORS OF THE COLON AND RECTUM 143
Benign Tumors. Carcinomata—General Considerations Involved in Resection of the Intestine for Carcinoma, Preliminary Colostomy, Complete Perineal Resection of the Rectum, The Combined Operation (Abdominoperineal Excision), Resection of the Sigmoid, Operative Treatment of Carcinomata Located in Other Parts of the Colon.

VI. THE EXCISION OF LYMPHATIC AREAS DRAINING MALIGNANT NEOPLASMS OF THE COLON AND RECTUM 189
Anatomical and Surgical Considerations of Malignant Neoplasms Located in the Ileocecal Region, Ascending Colon, Hepatic Flexure and First Part of the Transverse Colon, Middle of the Transverse Colon, Splenic Flexure, Descending Colon, Upper and Middle Sigmoid, Lower Sigmoid and First Part of Rectum, Rectum and Anus.

VII. THE TREATMENT OF CARCINOMATA OF THE COLON AND RECTUM BY NON-SURGICAL AND PALLIATIVE PROCEDURES . . . 205
The Roentgen-Ray and Radium. Palliative Treatment of Carcinomata of the Colon and Rectum.

CHAPTER PAGE

VIII. The Results of Various Methods of Treatment of Carcinomata of the Colon and Rectum 211
Surgical Procedures. Radiation. Conclusions.

IX. Other Types of Primary Neoplasms of the Colon and Rectum 219
Lymphoblastoma (Lymphosarcoma). Other Neoplastic Formations Associated with Lymphoid Structures of the Large Intestine (Gastrointestinal Pseudoleucemia, Leucemia, Lymphoma). Other Atypical Lymphoid Tumors of the Large Intestine. Fibroblastoma (Fibroma, Fibrosarcoma). Myxosarcoma. Melanoblastoma (Melanosarcoma). Lipoblastoma (Lipoma). Liomyoblastoma (Liomyoma). Angioma. Résumé of Benign Tumors of the Colon and Rectum. Cysts of the Large Intestine.

Bibliography 243

Index of Names 249

Index of Subjects 253

LIST OF ILLUSTRATIONS

FIGURE PAGE

1. Stages in the development of the digestive tube in rabbit, pig and man..... 5
2. The vermiform appendix at birth..... 7
3. Meckel's diverticulum..... 7
4. The interior of the anal canal and lower rectum..... 13
5. Musculature of the pelvis viewed from above..... 16
6. Lateral view of the pelvic musculature..... 17
7. The superior mesenteric artery and its branches..... 20
8. The inferior mesenteric artery and its branches..... 20
9. Ligations with and without destroying anastomosis of the inferior mesenteric artery..... 21
10. The lymphatic pathways of the large intestine..... 22
11. Vertical section of the mucous membrane of the descending colon of an adult man 26
12. Huge papilloma of the anus..... 33
13. Section of a small soft papilloma of the intestine..... 34
14, 15. Simple papilloma of the anus. Gross specimen and microscopic view showing fibrous connective-tissue core covered by stratified squamous epithelium..... 36
16*a* and *b*. Simple benign papillary adenomata, each possessing a pedicle of redundant mucosa elongated as the result of traction..... 38
17, 18, 19, 20. Polypoid adenoma of the descending colon associated with pigmentation of the mucosa. Gross specimen; sigmoidoscopic view of pigmented mucosa showing a marked contrast to the adjacent normal mucosa; microscopic view of mucosa; distribution of pigment. (Fig. 18 *color*)..... 40
21, 22. Multiple polypoid adenomata of the ascending and transverse colon. Gross specimen and microscopic view..... 44
23, 24, 25. Remarkable specimen of multiple polypoid adenomata covering the entire colon and part of the small intestine. Gross specimen; drawing of small area exhibiting the distribution of the tumor masses in detail; microscopic view..46, 48
26, 27. Carcinoma of the appendix. Gross specimen and microscopic view..... 54
28. The intramural spread of carcinoma of the colon or rectum..... 56
29, 30. Ulcerated adenocarcinoma of the rectum with extensive eosinophilic infiltration of the connective-tissue stroma. Gross specimen and microscopic view. (Fig. 30 *color*)..... 58
31, 32. A malignant neoplastic process which has probably been grafted upon a benign adenomatous polyp. Gross specimen and microscopic view..... 60

FIGURE PAGE

33, 34, 35. Adenoma malignum which has become carcinomatous, and benign polypoid adenoma of the sigmoid. Gross specimen; microscopic view of polypoid adenoma; microscopic view of sessile tumor mass 62

36, 37, 38, 39. Adenocarcinoma of the sigmoid. Gross specimen; microscopic view showing adenocarcinomatous tissue spreading through the intramuscular plexus; microscopic view showing adenocarcinomatous tissue already in intermuscular lymphatic plexus; microscopic view showing invasion of subperitoneal connective tissue 64

40, 41, 42. Carcinoma of the ileum probably having as its precursor a benign adenoma and showing the tendency of carcinoma to spread laterally as it penetrates the intestinal wall. Gross specimen; operative field; microscopic view 66, 68

43, 44, 45. Adenocarcinoma of the rectum. Gross specimen; microscopic view; invasion of epicolic lymph node 70

46, 47. Adenocarcinoma of the rectum with greatest bulk of the tumor projecting from the mucous surface of the gut. Gross specimen and microscopic view 72

48, 49. Adenocarcinoma of the rectum, the sinuous border at the lower margin being almost stony hard due to a dense fibrosis. Gross specimen and microscopic view 74

50, 51. Scirrhous carcinoma of the rectum. Gross specimen and microscopic view 78

52, 53. Scirrhous carcinoma at the rectosigmoidal junction causing almost complete closure of the bowel lumen. Gross specimen and microscopic view 80

54, 55. Scirrhous carcinoma encircling the rectum. Gross specimen and microscopic view 82

56, 57. Scirrhous carcinoma at the rectosigmoidal junction. Gross specimen and microscopic view 84

58, 59. Adenocarcinoma of the rectum which has already extended through the entire thickness of the intestinal wall. Gross specimen and microscopic view 98

60, 61. Scirrhous carcinoma of the rectum circumscribing the wall. Gross specimen and microscopic view 102

62, 63. Adenocarcinoma of the rectum resembling the scirrhous type. Gross specimen and microscopic view 104

64, 65. Large bulky adenocarcinoma of the rectum exhibiting extensive surface ulceration due to choking-off of the blood supply. Gross specimen and microscopic view 108

66, 67, 68. Adenocarcinoma at the rectosigmoidal junction exhibiting the usual central ulceration and heaped-up everted margin. Gross specimen; operative field showing tendency of stroma of invaded tissue to contract and pull upon healthy uninvolved tissue; microscopic view. (Figs. 66 and 67 *color*) 114, 116

69, 70. Large ulcerated adenocarcinoma of the rectum with central depressed cicatricial area. Gross specimen; microscopic view showing extensive invasion of the muscularis by atypical neoplastic epithelial cells 118

FIGURE PAGE

71. Sigmoidoscopic view of carcinoma of the sigmoid (*color*) 121
72. Simple polyp of the rectum (proctoscopic view) 121
73. Adenomatous polyps of the rectum (proctoscopic view) 121
74, 75. Adenocarcinoma of the rectum. Gross specimen showing smooth floor formed by muscularis; microscopic view showing extensive invasion of blood vessels and lymphatics 122
76, 77. Large, relatively superficial, adenocarcinoma of the rectum. Gross specimen and microscopic view 124
78, 79. Adenocarcinoma of the rectum. Gross specimen and microscopic view 126
80, 81. Advanced adenocarcinoma of the rectum which has spread beyond the local lymphatic bulwark. Gross specimen and microscopic view 128
82. Polyposis of the colon. Roentgenogram showing filling defect in the proximal colon 131
83. Benign papilloma. Roentgenogram showing filling defect in the upper border of the transverse colon 131
84. Carcinoma of the proximal colon (roentgenogram) 131
85. Carcinoma of the rectosigmoidal junction (roentgenogram) 131
86, 87. Large scirrhous type of carcinoma encircling the rectum. Gross specimen and microscopic view 134
88, 89. Adenocarcinoma of the rectum previously subjected to roentgen-ray and radium therapy. Gross specimen showing peculiar worm-eaten appearance of floor; microscopic view 136
90, 91. A relatively slow growing adenocarcinoma at the rectosigmoidal junction. Gross specimen showing lateral spread of tumor mass; microscopic view 138
92, 93. Constricting carcinoma at the rectosigmoidal junction. Gross specimen and microscopic view 140
94–98. Colostomy. (1) Delivery of a knuckle of sigmoid. (2) Suturing the peritoneum and anchoring the peritoneum below. (3) Another view of Step 2. (4) Suturing the fascia including the longitudinal band. (5) Skin sutured. Gut anchored only at angles (Figs. 94, 95, 96, 97 *color*) 147, 151, 153
99–108. Perineal resection of the rectum (female). (1) Purse-string suture shuts off anal orifice. Coccyx exposed and excised. (2) Levatores ani cut, lateral ligament clamped. (3) Rectum dissected away from bladder and urethra. (4) Ligation of superior hemorrhoidal artery. (5) Rectum excised between clamps by electric cautery, peritoneum closed with interrupted sutures. (6) Fascia and levatores ani closed (ventral view). (7) Dorsal view. Vaginal incision closed. (8) Rebuilding of perineum and making of pelvic support posteriorly. (9) The completed perineum. (10) Result four weeks after resection. (Figs. 99–107 *color*) 155, 159, 161, 165

FIGURE PAGE

109, 110. Combined operation for carcinoma of the rectum. Preservation of rectal sphincter (male) (*color*) 169, 171

111–115. Abdominal resection of the sigmoid or rectum. (1) Sigmoid loop delivered and peritoneal layers being peeled off on either side. (2) Later stage of Procedure 1. (3) Vascular supply exposed. (4) Rectum cut away from sigmoid and rectal stump buried below the peritoneal diaphragm. (5) Peritoneum completely closed over (111, 112, 113, 114 *color*) 179, 181, 183

116–121. Restoration of the rectosigmoid after resection of the rectum. (1) Healed colostomy wound. (2) Colostomy excised, Mummery tube tied into sigmoid stump. (3) Exposure of rectal stump. (4) Sponge forceps inserted in rectal canal and through rectal wall. (5) Rectosigmoid anastomosis closed off by fixing uterus to sigmoid and visceral peritoneum. (6) Completed operation 184, 185, 186, 187, 188

122. Intestinal resection for carcinoma of the colon or rectum with complete excision of the lymphatic drainage area 193

123. Lymphosarcomatous deposit in the intestinal wall 221

Chapter I

INTRODUCTION AND DEFINITION OF TERMS AND DEVELOPMENT OF THE COLON AND RECTUM

TUMORS
OF THE COLON AND RECTUM

Chapter I

INTRODUCTION AND DEFINITION OF TERMS AND DEVELOPMENT OF THE COLON AND RECTUM

THE colon and rectum are the common site of relatively few primary neoplastic diseases. By neoplastic diseases we refer to tumors made up of collections of cells growing independently and progressively at the expense of the rest of the body and serving no useful purpose. Various authors have expressed more limited or more elaborate conceptions of neoplastic disease. Thus, von Rindfleisch lays emphasis upon "a localized degenerative excess of growth." Ribbert regards tumors as uncontrolled new growths of tissue, abnormal in structure and unlimited in the extent of their growth. Lubarsch includes in his definition growths differing in their histological structure from the tissue in which they originate and pursuing an independent course not beneficial to the rest of the body. Prudden and Ewing limit their conceptions merely to an autonomous new growth of tissue.

The variety of tumors arising primarily in the wall of the large intestine may be described according to the cell types which form the beginning of and later predominate in the neoplastic process. These cells normally constitute the structure of the intestinal wall and may be tabulated as follows:

Cell type	Tumor
1. Epithelial cell—glandular or pavement cell	Papilloma Adenoma Carcinoma
2. Lymphocyte	Lymphoblastoma (lymphosarcoma, malignant lymphoma, lymphatic leucemia)
3. Connective-tissue cell (fibroblast)	Fibroma Fibrosarcoma
4. Pigment cell	Melanoma
5. Fat cell	Lipoma
6. Muscle cell (*a*) Smooth muscle cell.	Liomyoma
7. Endothelial cell	Hemangioma Lymphangioma

In order to understand more clearly the pathological and clinical problems underlying a study of the benign and malignant tumors of the large intestine it is deemed expedient to review briefly the development, anatomical structure and physiology of the digestive tract.

Development of the Colon and Rectum

The digestive tube of mammals develops as two outgrowths from the yolk sac, the foregut and the hindgut.[108] The former, situated anteriorly, extends from the yolk sac to the oral plate; posteriorly, there projects from the sac a short hindgut possessing a ventral outgrowth known as the allantois. The colon is seen to be partly differentiated from the rest of the alimentary tract in the six-weeks-old embryo. As the foregut and hindgut increase in length, their connection with the yolk sac is reduced to a slender tube-like structure, lined by entoderm, called the vitelline duct. The cecum first appears as a lateral protrusion of the alimentary tract just beyond the vitel-

line duct. It gradually increases in size, becoming bulbous, except at its blind extremity which remains narrow and eventually becomes the vermiform appendix. Posteriorly, the intestine and the allantois fuse, forming the cloaca whose communication with the exterior is closed by the cloacal membrane. As the alimentary canal increases in length it forms a loop, the lower

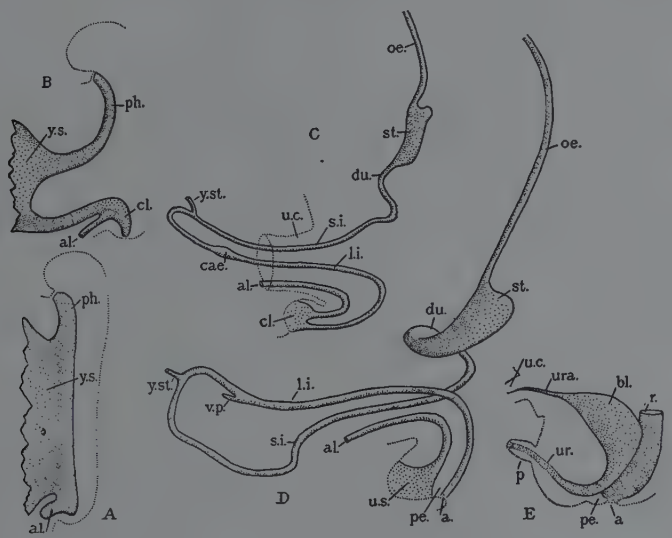

FIG. 1. STAGES IN THE DEVELOPMENT OF THE DIGESTIVE TUBE. A. RABBIT OF NINE DAYS. B. MAN 2.15 MM. (AFTER HIS). C. PIG 12 MM. D. MAN, 17.8 MM. (AFTER THYNG). E. MAN, ABOUT FIVE MONTHS. A., ANUS; AL., ALLANTOIS; BL., BLADDER; CAE., BULB OF THE COLON; CL., CLOACA; DU., DUODENUM; L. I., LARGE INTESTINE; OE., ESOPHAGUS; P., PENIS; PE., PERINEUM; PH., FORE-GUT; R., RECTUM; S.I., SMALL INTESTINE; ST., STOMACH; U.C., UMBILICAL CORD; UR., URETHRA; URA., URACHUS; U.S., UROGENITAL SINUS; V.P., VERMIFORM PROCESS; Y.S., YOLK-SAC; Y.ST., VITELLINE DUCT WITHIN THE YOLK-STALK (LEWIS-STÖHR).

part of which becomes colon, extending out into the cavity of the umbilical cord. Near the bend in this loop the yolk stalk is still attached to the intestine at a site which later becomes the ileum. In human embryos of about 10 mm. (four and one-half week embryo) the large intestine is twisted across the front of the duodenal portion of the small intestine. In the three- or four-months-

old embryo the cecum lies at about the center of the abdomen. The remainder of the colon lies on the left side, being attached to the front of the spine by means of a mesentery. After the withdrawal of the colon from the umbilical cord into the body the cecum is gradually carried up and to the right until it lies under the liver. In some mammals (dog, cat) this position is permanent, there being no ascending colon. By the eighth month the cecum and vermiform appendix reach their final position in the right iliac fossa. The remaining portion of the colon forms an inverted U, the limbs of which are the ascending, transverse and descending colon, the last connecting with the rectum by means of the convoluted sigmoid. Lockwood[77] connects the carriage downwards of the cecum into the right iliac fossa with the descent of the testicle, a band of peritoneum passing from the right testicle to a point near the ileocecal junction. Thus, imperfect descent of the cecum is often associated with undescended right testicle. The yolk sac above described becomes detached, the stalk sometimes remaining as a blind pouch of the ileum, 3 to 9 cm. in length, situated about 3 feet above the ileocecal region and known as Meckel's diverticulum.

The primitive gut ends blindly in the caudal end of the embryo. There is formed on the ventral aspect of the caudal extremity a small depression known as the anal pit. The ectoderm and entoderm at the bottom of this depression come in contact by the thinning-out of the mesoderm, thus forming the anal membrane. Just cephalad to the anal membrane the gut enlarges to form the cloaca which becomes separated by means of the urorectal fold into a dorsal portion, the rectum, and a ventral portion, the urogenital sinus. At about the end of the fifth week the anal membrane ruptures, forming the anal opening. The tissue which subdivides the cloaca reaches the surface and becomes the perineum.

The mesentery at first is attached to the entire alimentary tract. From the septum transversum (or diaphragm) to the anus the gut is suspended in

the celom (or abdominal cavity) by means of the dorsal mesentery which is attached to the dorsal body wall along the midline. The ventral mesentery, attached to the opposite side of the gut, is lacking from the anus to a point just above the yolk stalk. The dorsal and ventral mesenteric sheets give rise to the mesenteries and omenta of the adult. During the process of elongation the gut coils extensively within the abdominal cavity, resulting in various folds and pockets in the mesentery. Thus, when the portion of the intestine to which the yolk stalk is attached grows out into the umbilical cord it draws the mesentery out with it. Upon the return of the intestine

FIG. 2. THE VERMIFORM APPENDIX AT BIRTH. ILEOCECAL REGION AND APPENDIX INJECTED WITH GELATIN. ACTUAL SIZE.



FIG. 3. MECKEL'S DIVERTICULUM. ACTUAL SIZE.

to the abdominal cavity to form the primary loop, throwing the cecum to the right underneath the liver, a funnel-shaped twist of the mesentery results (fourth month). This part of the mesentery becomes the mesentery of the jejunum, ileum, ascending and transverse colon. As the gut continues to elongate attachments and fusion with other parts result. Thus, the transverse mesocolon fuses with the ventral surface of the duodenum and peritoneum covering the dorsal body wall. The descending mesocolon usually fuses with the peritoneum of the body wall so that the descending colon becomes fixed.

A similar process occurs with the ascending mesocolon. In many cases fusion of the ascending and descending mesocolon with the peritoneum fails to occur or is incomplete. The sigmoid mesocolon maintains its original position, forming no secondary attachments. The mesoappendix probably represents an elongated portion of the original common mesentery. The portion of the mesentery attaching the primitive stomach to the dorsal body wall (the dorsal mesogastrium) becomes the great omentum which later fuses with the transverse colon and transverse mesocolon and left dorsal body wall. Beyond the transverse colon the two lamellae of the omentum fuse with each other.

Chapter II

THE ANATOMY AND PHYSIOLOGY OF THE COLON AND RECTUM

Chapter II

THE ANATOMY AND PHYSIOLOGY OF THE COLON AND RECTUM

Descriptive Gross Anatomy of the Colon and Rectum

In man the colon starts in the right iliac region as a dilated pouch, the cecum, into which the small intestine opens, passing the ileocecal valve. From the cecum the ascending colon, which is of smaller caliber, passes up towards the liver, then bends inward and forward to the left (hepatic flexure), passes transversely across the upper part of the abdomen (transverse colon) to the spleen where it curves downward (splenic flexure). The colon then continues along the outer border of the left kidney, at the lower pole of which it turns inward along the outer border of the psoas muscle until the crest of the ileum is reached (descending colon). Here it becomes continuous with the sigmoid flexure, the narrowest portion of the colon, which in turn joins the rectum at the level of the third sacral vertebra. The rectum continues downward, lying in the sacrococcygeal curve, as far as the apex of the prostate (i.e., a little below the tip of the coccyx). Bending sharply backward and downward as the anal canal for a distance of 2.5 to 3.75 cm., the intestinal tract terminates at the anus.[38]

The ascending colon is fixed to the posterior wall of the abdomen by the peritoneum which covers its posterior surface and sides. The posterior surface lies upon the quadratus lumborum and right kidney. Sometimes the ascending colon possesses a short mesocolon. The anterior surface is in relation with the ileum and abdominal parietes.

The transverse colon is the longest and most movable portion of the large intestine. It is completely covered by peritoneum and connected with the posterior abdominal wall by means of the transverse mesocolon. The upper surface is in relation with the liver and gall-bladder, the greater curva-

ture of the stomach and lower end of the spleen. The under surface is in contact with the small intestine. The anterior surface touches the great omentum and abdominal wall. The posterior surface adjoins the second portion of duodenum, part of the jejunum and ileum.

The splenic flexure lies in contact with the lower end of the spleen and tail of the pancreas. This flexure is attached to the diaphragm opposite the tenth and eleventh ribs by means of a fold of peritoneum.

The descending colon is also fixed by peritoneum which covers its anterior surface and sides and lies in contact with the left kidney and quadratus lumborum muscle. This portion of the colon sometimes possesses a mesocolon.

The sigmoid flexure, commencing at about the level of the sacrovertebral angle, passes downward parallel to the outer border of the psoas muscle and in the pelvis forms a loop averaging about 40 cm. in length. The flexure first descends in contact with the left pelvic wall, then crosses the pelvic cavity between the rectum and bladder or uterus to the lower margin of the right iliac fossa. Here it arches backward along the anterior surface of the sacrum to the third sarral vertebra. The sigmoid colon is completely covered by peritoneum and possesses a long fan-shaped mesentery, attached by its short end to a line running from the left sacroiliac synchondrosis to the midline of the sacrum. This line of attachment runs across the left psoas muscle, left external iliac artery and vein, left spermatic or ovarian vessels, and left ureter. When empty the sigmoid falls into the rectovesical or rectovaginal space. When distended it moves upward into the abdomen. The sigmoid mesocolon diminishes in length from the center towards both ends of the flexure so that the latter is fixed at its junction with descending colon and rectum but very mobile in the intervening portion. The sigmoid flexure lies in relation posteriorly with the external iliac vessels, left piriformis muscle and left sacral plexus. In front are some coils of the small intestine.

The rectum is about 12 cm. in length, smooth (lack of sacculation being due to absence of the characteristic longitudinal bands of the colon) and may be divided into two parts.[21] The upper part is in relation posteriorly with the sacrum, being separated from it by the piriformis muscle, internal pudic artery and sacral plexus. Anteriorly it is in contact with the bladder (in the male) except when the latter organ is empty, in which case the rectum touches some coils of the small intestine. In the female, the uterus and vagina are interposed between the rectum and bladder. The peritoneum is related to the upper two-thirds of the rectum, at the top covering both front and

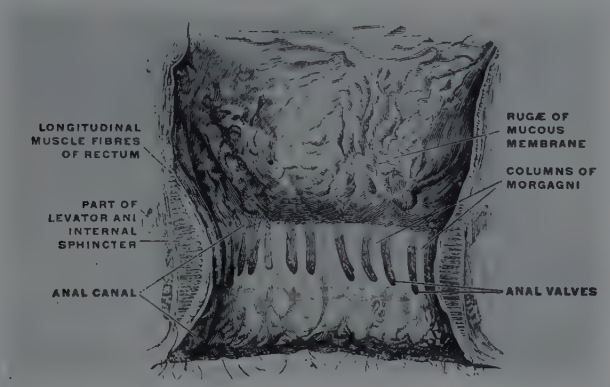

FIG. 4. THE INTERIOR OF THE ANAL CANAL AND LOWER RECTUM (CUNNINGHAM).

sides but lower down the front only, being reflected on to the seminal vesicles and bladder in the male and posterior vaginal wall and uterus in the female. Dupuytren[60] gives the distance of the rectovesical reflection as 70 mm. above the anus except when the bladder and rectum are empty, at which time the peritoneum touches the prostate. Lisfranc's[62] figures are 150 mm. in the female and 100 mm. in the male. Gray[38] places the distance at about 75 mm. in the male and 55 mm. in the female. Cripps' figures are a little lower than those of Gray. As a rough approximation, the peritoneal reflection of the rectum may be said to start at a point corresponding to the length of the examining index finger.

The lower part of the rectum is in relation posteriorly with the sacrum, coccyx and levatores ani, being attached to the sacrum by connective tissue containing the sacral nerves and branches of the superior hemorrhoidal vessels. Anteriorly, below the rectovesical pouch, it is in relation with the triangular portion of the base of the bladder, the posterior surface of the prostate, seminal vesicles and ductus deferentes. In the female the rectum touches the posterior wall of the vagina.

Where sigmoid joins rectum there is a slight narrowing of the lumen, termed the rectosigmoidal junction. Immediately above the anus the rectum is dilated to form the ampulla. The latter is capable of being greatly distended. The mucosa of the rectum is smooth but when the lower part is contracted its mucosa is thrown into longitudinal folds which are obliterated by distention of the gut. There are also two to four transverse semilunar folds (Houston's valves): one is placed near the commencement of the rectum on the right side; another is located on a level with the middle of the sacrum; a third, the largest, is opposite the fundus of the bladder. If another is present it is usually found about 25 mm. above the anus on the left posterior wall. These folds are about 12 mm. in width and overlap when the rectum is empty.

The anal canal is not covered by peritoneum. It possesses, however, two sphincters. The circular muscle coat is thickened just above the anal orifice to form the so-called internal sphincter. The external or true sphincter arises from the tip and sides of the coccyx and nearby fascia, passing forward to embrace the anal canal to find insertion in the central tendinous point of the perineum. Here the sphincter blends with the fibers of the transversus perinei, levator ani and accelerator urinae. In the female it is continuous in front with the fibers of the sphincter vaginae. When empty, the anal canal is an anteroposterior longitudinal slit. Posteriorly, it is in relation with the anococcygeal body; anteriorly, with the membranous portion and bulb of

the urethra and fascia of the urogenital diaphragm. In the female the anal canal is separated from the vagina by the perineal body.

The upper part of the anal canal is lined by mucosa which is thrown into six to ten vertical folds (columns of Morgagni). These folds consist of mucosa and some muscularis, each fold containing a small artery and vein. Below, these columns end in and are joined together by small crescentic folds called anal valves. The lower part of the anal canal is lined with skin which is thrown into folds from the anus upward towards the columns of Morgagni. The junction of skin and mucosa is indicated by a wavy white line due to the interlocking of the cutaneous and mucous folds.[110]

It is expedient at this point to give a brief description of the muscles and fasciae of the pelvic outlet. These structures form the floor of the pelvis. The perineum is that structure which lies between the pubic arch and a line drawn between the tuberosities of the ischia. The ischiorectal space lies between this line and the tip of the coccyx, being bounded laterally by the gluteus maximus muscle. The fasciae of the pelvic outlet can be divided into three strata:

(1) Superficial fascia, which fills the ischiorectal region in fatty layers on each side of the rectum and anus. In the perineal region it forms two layers: the thick superficial layer continuous with the dartos of the scrotum or mons Veneris and labia majora in front, and the fascia on the inner side of the thighs; the thin, strong aponeurotic deep layer which is continuous with the dartos, fascia of the penis and Scarpa's fascia on the anterior surface of the abdomen. Laterally, the deep layer is attached to the outer borders of the rami ischii while posteriorly it blends with the base of the triangular ligament. This fascia covers the superficial muscles, blood-vessels and nerves of the perineum.

(2) The triangular ligament (deep perineal fascia) is made up of two musculomembranous layers which stretch across the pubic arch, shutting

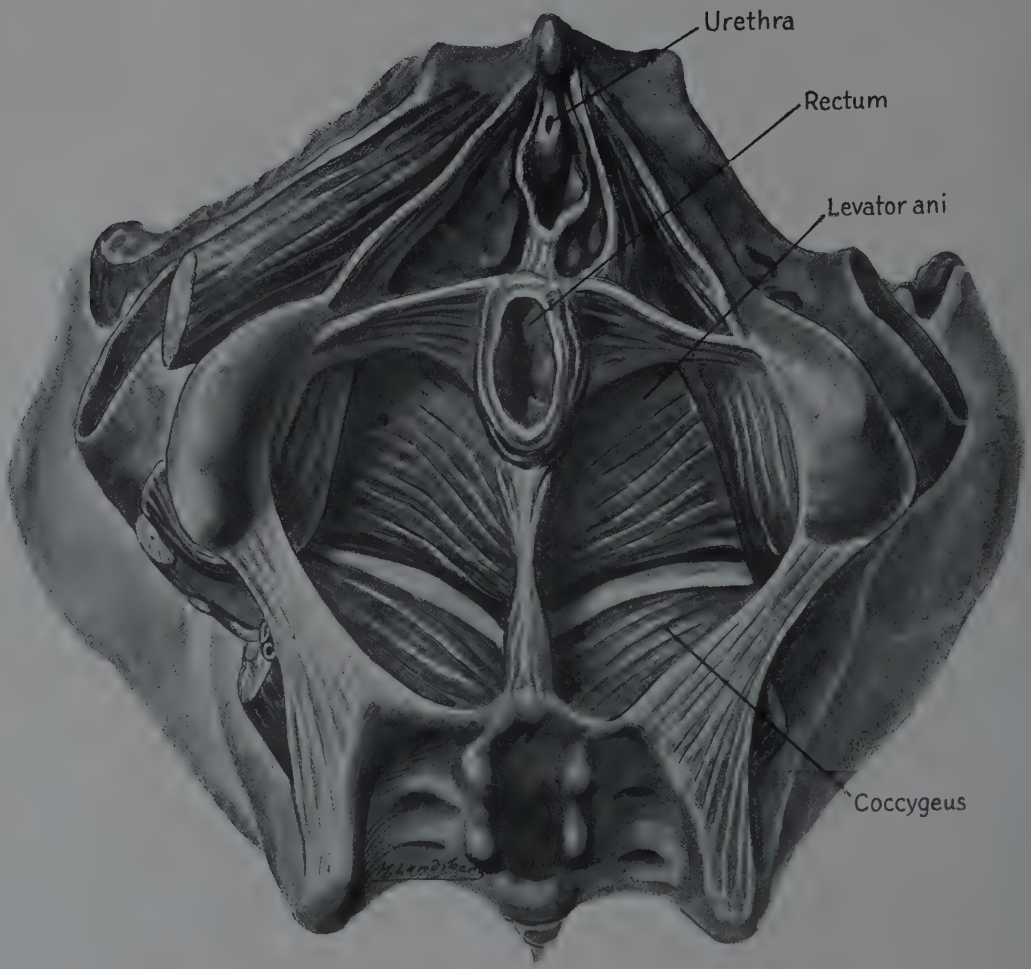

FIG. 5. MUSCULATURE OF THE PELVIS VIEWED FROM ABOVE.

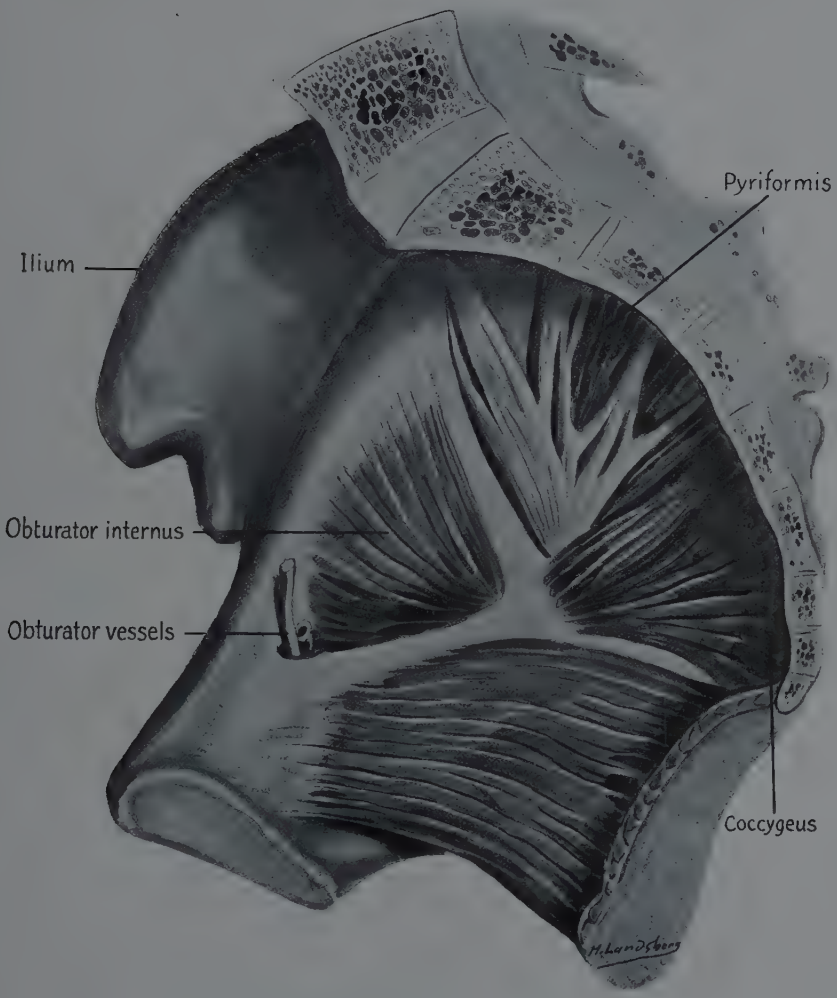

FIG. 6. LATERAL VIEW OF THE PELVIC MUSCULATURE.

off the front part of the pelvic outlet. The two layers fuse at the base which is attached to the central tendinous point of the perineum.

(3) The pelvic fascia, which forms a strong support for the structures of the pelvic cavity. Anteriorly, this is attached to the back part of the iliopectineal line, blending with the iliac fascia. Posteriorly, it extends along the piriformis muscle forming attachments to the margins of the sacral foramina, ensheathing the nerves and spreading out into the gluteal region. The remainder of the pelvic fascia serves to complete the obturator canal, covers the obturator internus and forms an attachment to the posterior surface of the os pubis. It blends with the base of the triangular ligament at the ischiopubic ramus and crosses the pubic arch to become continuous with the fascia of the opposite side. The pelvic fascia is perforated by the urethra, being called in this region the deep layer of the triangular ligament. A thick band of whitish tissue termed the white line extends from the back part of the symphysis pubis to the spine of the ischium. Above this line the fascia is in contact with the peritoneum lining the pelvic cavity; below it the obturator fascia invades the ischiorectal space. The pubic vessels and nerves cross this region. From the white line the obturator fascia distributes itself over the pelvic viscera, the cephalic surface of the levator ani, bladder, seminal vesicles, prostate and its venous plexus as well as the rectum. It forms the anterior and lateral true ligaments of the bladder.

Of the muscular structures concerned in a study of tumors of the pelvis the most important is the levator ani. This is a broad thin muscle attached to the inner wall of the true pelvis. It descends to unite with the muscle of the opposite side and together with the coccygei forms a strong muscular support for the pelvic viscera. The levator ani is attached to the posterior surface of the body of the pubis, the inner surface of the spine of the ischium and the pelvic fascia. From these points of attachment the fibers converge toward the midline forming a sort of sling for the rectum and prostate, and pos-

teriorly find insertion into the sides of the lower part of the coccyx. The fibers passing underneath the prostate join with those of the external sphincter and transversus perinei at the central tendinous point.

The coccygeus runs parallel to the levator ani, extending from the spine of the ischium to the side of the sacrum and coccyx.

The piriformis arises from the anterior sacral region, and passes out of the pelvis through the great sacrosciatic foramen to find insertion into the upper border of the great trochanter.

The obturator internus arises from the inner surface of the anterior and external pelvic wall and the obturator membrane, and leaves the pelvis by the lesser sacrosciatic foramen to be inserted into the great trochanter.

The ischiorectal fossa is a triangular space about two inches in depth and one inch wide at the base, which is formed by the integument of the ischiorectal region. This space is composed largely of fatty tissue which is very prone to infection associated with pathological conditions of the rectum. Its boundaries are: externally, the tuberosity of the ischium and obturator fascia; anteriorly, the line of junction of the superficial fascia and base of the triangular ligament; behind, the margin of the gluteus maximus and great sciatic ligament.

The anal fascia covers the inferior surface of the pelvic diaphragm. It is attached to the obturator fascia origin of the levator ani, the back of the body and symphysis pubis, and is continuous with the deep layer of the triangular ligament and fascia on the internal sphincter.

The arterial supply of the colon is derived from the superior and inferior mesenteric branches of the descending aorta. The former supplies the cecum, ascending and right part of the transverse colon while the latter supplies the remainder of the transverse and all of the descending colon, sigmoid flexure and part of the rectum. The superior mesenteric artery, which also supplies all of the small intestine, descends from its origin just below the celiac axis

between the layers of the mesentery to the right iliac fossa to anastomose with one of its own branches, the ileocolic. The inferior mesenteric artery, smaller than the preceding, arises from the aorta about two inches above its division. It passes downward to the left iliac fossa, between the layers of the mesorectum, and enters the pelvis as the superior hemorrhoidal artery which crosses the left ureter and left common iliac artery to supply the rectum. Here it communicates with the middle hemorrhoidal branches of the internal iliac and inferior hemorrhoidal branches of the internal pudic. The superior hemor-

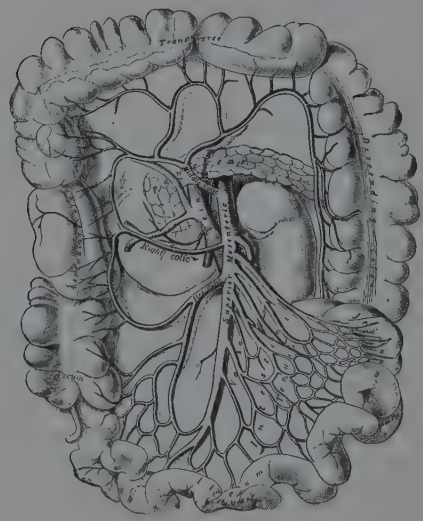

FIG. 7. THE SUPERIOR MESENTERIC ARTERY AND ITS BRANCHES.

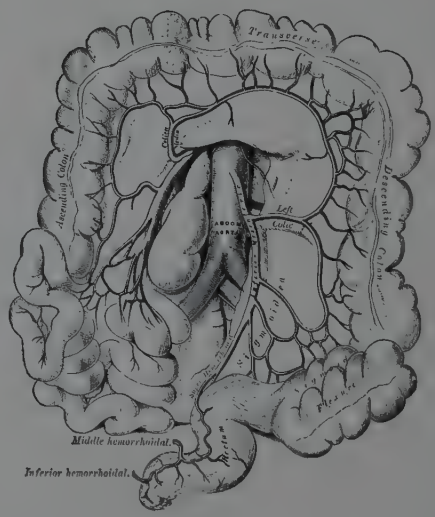

FIG. 8. THE INFERIOR MESENTERIC ARTERY AND ITS BRANCHES.

rhoidal artery running down the posterior wall of the rectum usually divides opposite the middle of the sacrum into two branches, which run down on either side until they reach a point about five inches above the anus. Here they break up into smaller branches which pierce the muscularis and continue downward as straight vessels in the submucosa until they reach the internal sphincter. They then form a series of loops around the rectum and anastomose with the

other hemorrhoidal arteries. The superior hemorrhoidal artery may receive a large branch from the sigmoid artery (a tributary of the inferior mesenteric).

The arterial branches in the wall of the colon do not freely anastomose. Free anastomoses usually occur by a series of loops which lie close to the mesenteric border of the colon. In the sigmoid flexure the anastomoses usually occur nearer the base of the mesocolon.

The veins in general follow the course of the arteries. By means of anastomoses like those above described the portal and systemic veins unite. In this manner blood from the rectal area passes both into the liver and

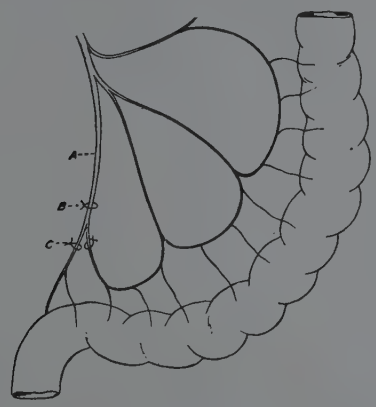

FIG. 9. A. INFERIOR MESENTERIC ARTERY; B. LIGATURE WITHOUT DESTROYING ANASTOMOSIS; C. LIGATURES BREAKING THE ANASTOMOSIS.

directly into the inferior vena cava. Just in front of the rectum there is a large plexus of veins (the prostatic plexus of the male or vaginal plexus of the female).

The lymphatic vessels of the intestines for the most part accompany the branches of the superior mesenteric artery. After having passed through the many lymph-nodes interspersed among these branches the lymphatic vessels terminate in the large nodes lying near the place of origin of the artery at the root of the mesentery. The efferent vessels from these nodes empty

into the receptaculum chyli. This general arrangement holds true from the duodenum to the splenic flexure of the colon. A more detailed account of the lymphatic areas will be given in connection with the surgical procedures used in removing malignant neoplasms from various portions of the large

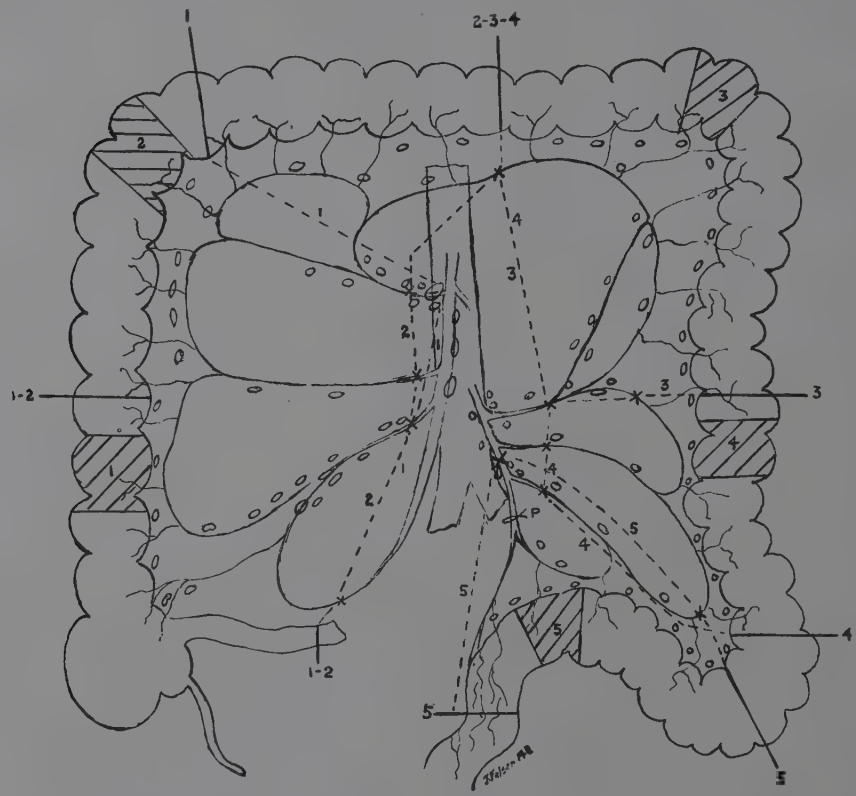

FIG. 10. THE LYMPHATIC PATHWAYS OF THE LARGE INTESTINE (FELSEN).

intestine. The following description summarizes in a very brief way the main lymph-node distribution for the colon and rectum.

The lymphatic supply of the colon follows the course of the blood-vessels. According to Jamieson and Dobson,[47] the lymph-nodes can be divided into the following groups:

(1) The epiploic nodes, which lie on the intestinal wall and in the appendices epiploicae, being especially numerous in the pelvic colon. These drain into the two following groups.

(2) The paracolic nodes, which lie along the mesenteric border of the colon.

(3) The intermediate groups, which lie along the arteries.

(4) The main groups: Middle colic, lying on the middle colic artery; left colic, lying on the left colic artery near its origin and on the terminal portion of the mesenteric vein. These nodes drain into the superior mesenteric, celiac and lumbar nodes. The inferior mesenteric group lies on the artery and passes into the lumbar nodes which drain the pelvic colon. Some of the lymphatics of the left portion of the transverse colon drain into the nodes at the hilum of the spleen through the gastrocolic omentum. Briefly stated, the mesenteric nodes drain the cecum, the ascending and transverse colon; the lumbar nodes drain the descending colon and sigmoid flexure.

The rectum and anus have the following lymphatic supply:

The vessels from the skin of the anus ascend along the inner side of the thigh to reach the superficial inguinal nodes. Some vessels from this region also reach the submucous plexus of the rectum, draining into the pararectal nodes and those situated along the middle and inferior hemorrhoidal arteries as well as into a pelvic node near the origin of the internal pudic artery. From these nodes efferent vessels terminate in preaortic nodes near the origin of the inferior mesenteric artery.

The nerve supply to the colon is derived from the sympathetic plexuses around the branches of the superior and inferior mesenteric arteries. The nerves of the anus and rectum are largely derived from the sympathetic system but also receive branches from the third, fourth and fifth sacral nerves. The sensory distribution is confined to the anus. In structure the nerves to the colon include both medullated and non-medullated fibers. The former

end in knobbed terminals located beneath and upon the glandular epithelium. The latter supply the muscular coats and blood-vessels.

Applied Gross Anatomy of the Colon and Rectum

Perfect preservation of the pelvic floor is dependent upon the integrity of the muscular and fascial structures above described. Because of its long mesentery the sigmoid is most frequently the seat of volvulus. On the other hand, advantage of its mobility may be taken in perineal excision of the rectum. The mucous membrane of the rectum, being thick and loosely connected to the muscularis, is prone to prolapse, especially in children. The loose connective tissue about the rectum above the levator ani may be the site of a troublesome abscess, the source of which may be rectum, prostate, seminal vesicles, sacrum or presacral lymph-nodes. Contraction of the sphincter ani interferes with the healing of an ischiorectal abscess. Contraction of this same muscle causes pain in lesions about the anus. The peculiar peritoneal reflections from the rectum may be used to advantage, as one may operate on the posterior wall of the rectum higher up than on any other wall without fear of entering the peritoneal cavity. The blood supply of the upper part of the rectum depends on the superior hemorrhoidal artery and sloughing will usually follow anastomoses made in this portion of the rectum. The vessels of the rectum run longitudinally in the loose cellular submucosa. This anatomical feature together with the absence of valves in the superior hemorrhoidal veins, their dependent position, exposure to trauma by feces and possible constriction where the veins pierce the muscularis, render these vessels peculiarly susceptible to varicosities. Digital examination of the rectum reveals the tight ring-like contraction of the external sphincter, the finger then entering the wide ampulla. Posteriorly there can be felt the coccyx and hollow of the sacrum, while laterally are the ridges formed by the levatores ani. Anteriorly the prostate and

seminal vesicles may be palpated in the male. In the female the hard cervix uteri can be felt high up. Proctoscopic examination is of great diagnostic importance. Within the area of the external sphincter there may be seen the longitudinal folds known as the columns of Morgagni. At the junction of anal skin and rectal mucosa a faint white line is visible circumscribing the anal canal (Hilton's white line). The healthy rectal mucosa is pale pink, glistening and smooth. Higher up where rectum joins colon there is a slight narrowing. The three Houston valves are noted as crescentic folds of mucosa each incompletely circumventing the wall of the rectum but placed diagonally at different levels and overlapping like the leaves of an iris diaphragm. The extensive lymphatic supply of the colon and rectum is the cause of grave concern in carcinomata of the hindgut structures. Epitheliomata of the anal region invade the superficial inguinal lymph-nodes by ascending the lymphatics along the inner sides of the thighs. They may also permeate the nodes of the mesorectum. Lesions of the ampulla, on the other hand, are drained by the nodes of the mesorectum and base of the mesentery near the bifurcation of the aorta. The intramural spread of cancer of the rectum is dependent upon the histological distribution of the lymphatic networks.

Because of the absence of pain or tactile sense in the mucosa of the colon and upper part of the rectum, serious lesions may exist without causing much inconvenience, while small lesions at the sensitive anal orifice are very soon the source of great annoyance. For this reason colon and rectal tumors usually are seen by the surgeon at an advanced stage while epitheliomata of the anus are noticed quite early. Referred pains in rectal and anal conditions are due to the intimate connection of their nerve supply with that of the neck of the bladder, urethra, vagina, hip joint and inner side of knee (obturator branches). Direct pressure upon or neoplastic involvement of the sacral plexus with concomitant symptoms may accompany lesions of the rectum.

Microscopic Anatomy of the Colon and Rectum

The wall of the colon consists of four coats[2]:

(1) Mucosa, made up of simple, columnar epithelium with goblet cells resting upon a basement membrane beneath which is the tunica propria containing capillaries and diffuse lymphoid tissue. Externally is the muscularis mucosae. The glands are of the simple tubular type. The mucosa

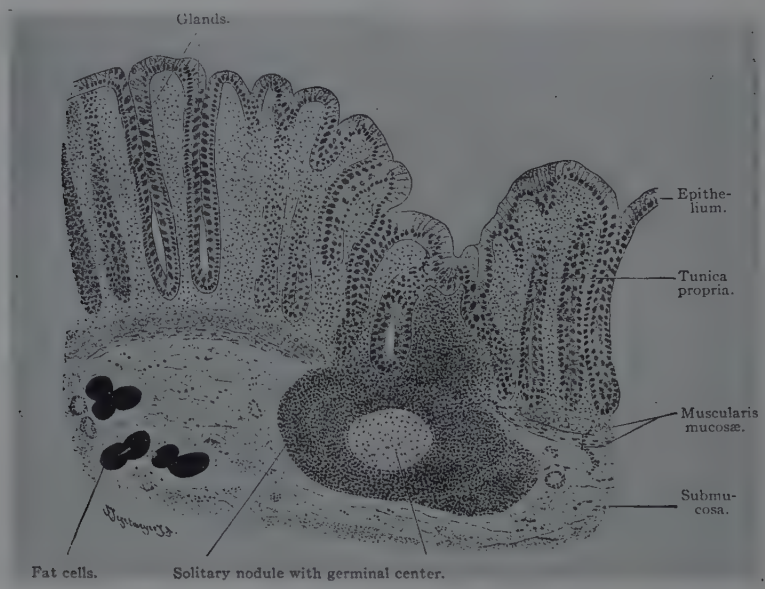

FIG. 11. VERTICAL SECTION OF THE MUCOUS MEMBRANE OF THE DESCENDING COLON OF AN ADULT MAN. × 80 (LEWIS-STÖHR).

possesses neither pits (as found in the stomach) nor villi (as found in the small intestine).

(2) Submucosa, consisting of loosely arranged connective tissue in which are contained large blood-vessels, the nerve plexuses of Meissner and solitary lymph follicles. The latter frequently break through the muscularis mucosae and protrude into the submucosa. The solitary follicle consists of a mass of

lymphoid tissue and is surrounded by connective tissue whose fine branches penetrate the follicle and form a supporting reticulum for the lymphocytes. These cells are loosely packed in the center of the follicle and usually show active mitosis. This germinal center is surrounded by a denser layer of lymphoid tissue which in turn is surrounded by a more loosely packed area of lymphocytes and a more or less circumventing peripheral lymph sinus.

(3) Muscularis, consisting of an internal circular layer (especially thick in the intervals between the sacculi and forming the internal sphincter of the anus) and an outer longitudinal layer forming the bands or teniae so characteristic of the colon. Between the bands the longitudinal muscular tissue is thin or entirely absent. The nerve plexuses of Auerbach lie in the connective tissue between the circular and longitudinal muscular coats.

(4) Serosa, consisting of loose connective tissue covered by a single layer of mesothelium. It is derived from the peritoneum.

The microscopic study of the lymphatic networks is of interest, especially in connection with the intramural spread of cancer. According to Cole,[20] the main lymphatic networks of the large bowel are the submucous, subserous, intermuscular and plexuses of the circular and longitudinal coats (intramuscular layer). "Lymph from the intramuscular networks drains into the intermuscular plexus though some communication exists between the lymph vessels of the longitudinal coat and those of the subserous plexus. Vessels of the circular coat are distributed radially, running out from submucous to the intermuscular plexuses like spokes of a wheel; the vessels of the longitudinal coat have generally a longitudinal direction. The vessels of the intermuscular plexus have generally a circular disposition. Below the peritoneal reflection it shares with the submucous plexus the task of transferring lymph from the bowel wall to collecting trunks. Deposits of cancer tissue are often seen in the intermuscular lymphatic plexus, a condition which may be largely responsible for the circular dissemination of cancer growths."[39]

Sappey describes three lymphatic networks in the large intestine:

(1) A plexus situated in or just beneath the mucosa, taking its origin in the solitary follicles but also receiving some tributaries from the tissue between the crypts of Lieberkühn. The vessels from this plexus run just within or below the mucosa and do not communicate with the muscularis. At the mesenteric attachment of the colon they perforate the muscularis to end in the regional mesenteric nodes.

(2) The important lymphatic network of the muscularis, the vessels from which communicate with the subserous plexus.

(3) The subserous plexus, lying just beneath the peritoneum. Handley considers this plexus as mainly concerned with absorption of excess fluid from the peritoneal cavity.

The mucosa of the rectum is like that of the colon except that the Lieberküehn glands are longer, more numerous and secrete a large amount of mucus. At the upper end of the columns of Morgagni the simple columnar epithelium of the rectum passes into the stratified squamous epithelium in which the glands persist for a short distance. At the anus there is a complete transition from mucosa to skin. The submucosa is similar to that of the colon. The muscularis is thicker and at one point the circular fibers form the internal sphincter. The serosa is absent in the lower part of the rectum.

Physiology of the Colon and Rectum

Hertz[43] finds that in man it requires about two hours for food to pass from the ileocecal valve to the hepatic flexure and about four and a half hours to reach the splenic flexure. From this point the food material advances very slowly towards the rectum. It requires sixteen to seventeen hours for food to pass from the splenic flexure to the lower end of the sigmoid and six hours to pass through the sigmoid as compared with four and three-eighths hours for movement through the twenty feet of small intestine. Cannon[13]

divides the large intestine into two parts: In the first, corresponding to the cecum, ascending and transverse colon, the most frequent movement is antiperistalsis. The fluid or semifluid material is forced back toward the small intestine, the entrance to which is guarded by the ileocecal valve. The object of this delay is probably primarily the absorption of water, secondarily to complete the process of digestion. The importance of fluid absorption is evident from the phenomenon of intense thirst displayed by patients having a right inguinal colostomy. According to Keith and Mummery, the cecum bears the same relationship to the large intestine as the stomach does to the small intestine. In some of the lower animals the cecum is actually the main organ of digestion. In the second portion, the descending colon, the food material which is now quite solid is moved on by peristaltic waves toward the rectum.

The motor-nerve fibers of the colon leave the cord in the second to fourth sacral nerves and reach the colon through the hypogastric plexus. The inhibitory fibers probably leave the cord in the lumbar nerves and reach the colon through the sympathetic chain and inferior mesenteric ganglia. The type of movement in the colon except for its relative infrequency is generally considered to be the same as in the small intestine: a local rhythmical constriction and a progressive peristaltic movement. According to Hertz, fecal material is normally absent from the rectum except just before defecation. The sigmoid flexure acts as the normal fecal reservoir. The feces are retained in the rectum by the tonicity of the internal and external sphincters, the latter being in greater tone than the former. With distention of the rectum by the feces there arises the normal stimulus to defecate, which act is effected by peristaltic action of the colon and rectum occurring simultaneously with relaxation of the sphincters and fixation of the diaphragm. It will be noted that the rectum is normally empty and functionates entirely as an expulsive organ. The function of Houston's valves is probably to impart a rotary motion to the feces and to consolidate them. The valves may also act

as a support to the fecal column preventing descent to the anus where its presence excites the sensation to defecate.

The nerve supply to the anus and rectum is derived from the sympathetic system, third, fourth and fifth sacral nerves. It is interesting to note that the normal mucous membrane of the colon and rectum as far as a point about one inch above the anus does not possess ordinary tactile or pain sensation. The latter is also absent from visceral peritoneum. Parietal peritoneum, the mesentery of the colon and the mucous membrane of the lower part of the rectum do possess pain sensation. Pain due to muscular contraction of the intestine can be produced by violent peristalsis.

Chapter III

PATHOLOGICAL ASPECTS OF PRIMARY EPITHELIAL TUMORS OF THE COLON AND RECTUM

Chapter III

PATHOLOGICAL ASPECTS OF PRIMARY EPITHELIAL TUMORS OF THE COLON AND RECTUM

PRIMARY epithelial-cell tumors of the colon and rectum are by far the most frequent type encountered. For this reason our prime consideration will be given to this group, which includes the papilloma, adenoma and carcinoma.

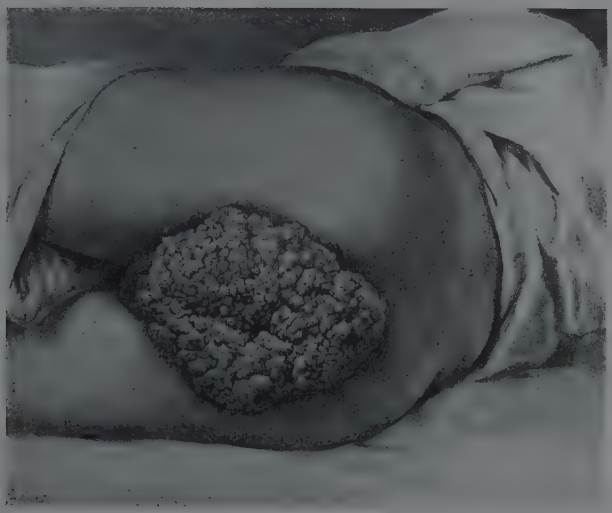

FIG. 12. HUGE PAPILLOMA OF THE ANUS.

Pathological Aspects

Papilloma. This type of epithelial tumor is a fibroepithelial structure which arises from skin or mucous membrane and shows definite evidence of epithelial hyperplasia. One must not confuse this tumor with the papillary fibroma of the skin or papillary adenoma of the intestine. In the former the epithelium merely covers the growth. The latter is simply an adenoma com-

posed of hyperplastic glandular tissue which has taken on a papillary form. It must be remembered, however, that in the true papilloma the connective tissue is nearly always hypertrophic and contains dilated or elongated blood-vessels. When located in the intestine, the accumulation of fluid within the meshes of the tumor alters its shape and size while traction on a loose mucous membrane during defecation produces an elongated pedicle. An example is the simple polyp of the rectum. There is no tendency on the part of the



FIG. 13. SECTION OF A SMALL SOFT PAPILLOMA OF THE INTESTINE (PHOTOGRAPHED UNDER A LOW POWER TO SHOW THE WHOLE TUMOR, BY PROF. ALLEN J. SMITH).

epithelium in a true benign papilloma to invade the underlying connective tissue. It is questionable whether the so-called "villous tumors" of the intestine should be classified under the true papillomata or papillary adenomata. Of delicate papillary structure and great vascularity, this type of tumor presents a beautifully complex arborescent arrangement occasionally covering an area as large as 10 cm. Ewing[31] observed a benign villous papilloma of

the sigmoid 13 by 9 cm. in size. The papillae varied in height from 5 to 15 mm. There was no penetration of the muscularis mucosae. One of the authors removed a tumor of similar proportions. Being hyperemic and of soft texture such a tumor bleeds readily to the touch. The surface may be covered with mucus, detritus, etc., which fill in the spaces between the branches, thus giving the false appearance of a smooth mass. Upon section the central core is seen to consist of a vascularized adenoid tissue supporting single or multiple layers of columnar epithelium. In others the core appears to consist for the most part of fibrous tissue supporting blood and lymph vessels and reaching out to the terminal branches where it is covered by single or multiple layers of cylindrical epithelium resembling the mucosa from which it originates. Many goblet cells are present and the glands secrete like normal intestinal glands. Papillary tumors subjected to constant chronic irritation tend to undergo malignant change and for this reason thorough extirpation of the base is always advisable.

In the anal region a simple papillary cutaneous overgrowth known as the cutaneous wart is prone to occur. It is usually found around the orifice or just within the anal canal, arising from the skin probably as the result of an inflammatory process. Usually multiple, they vary in size from barely visible specks to 10 mm., appearing as thin, whitish, pointed, branching or cauliflower-like elevations. These may spread out for a considerable distance from the anus. Some disappear in a short time while others may coalesce and form bulky masses. Microscopically, the entire Malpighian layer is thickened and thrown into irregular folds projecting into the connective tissue. Usually the connective tissue is dense and poorly vascularized but it may be very vascular.

Occasionally, at the junction of skin and mucous membrane just below the valves of Morgagni, the anal papillae hypertrophy, acquire sensitive nerve endings and assume a definite papillary form. Upon section, however, these are seen to be more in the nature of fibromata with a thin epithelial covering.

CASE I. (Record no. 4543, lab. no. 1191)



FIG. 14. SIMPLE PAPILLOMA OF THE ANUS. SPECIMEN 1191.



FIG. 15. SIMPLE PAPILLOMA OF THE ANUS. NOTE THE FIBROUS CONNECTIVE TISSUE CORE COVERED BY STRATIFIED SQUAMOUS EPITHELIUM. SPECIMEN 1191.

CASE I. (Record no. 4543, lab. no. 1191)

CLINICAL HISTORY

Male, aged thirty-five, native of U. S. A.

Family History. Irrelevant.

Duration of Symptoms. Six years.

Onset. Burning pain in rectum following defecation.

Chief Symptoms and Signs. Pain as above. Mass protruding after defecation.

Loss of Weight. None.

Physical Examination (relevant). Small anal polyp.

Operative Procedure. Excision of polyp and hemorrhoids.

PATHOLOGICAL REPORT

Gross. Specimen consists of what appears to be pigmented mucosa to which is attached by a 1 cm. pedicle a firm whitish solid polyp-like mass.

Microscopic. Simple true polyp.

Case ii. (Record no. 3614, lab. no. 843)

A

Case iii. (Record no. 3486, lab. no. 798)

B

FIG. 16A AND B. SIMPLE BENIGN PAPILLARY ADENOMATA. EACH TUMOR POSSESSES A PEDICLE OF REDUNDANT MUCOSA ELONGATED AS THE RESULT OF TRACTION. (16A—SPECIMEN 843. 16B—SPECIMEN 798.)

Case II. (Record no. 3614, lab. no. 843)

CLINICAL HISTORY

Polyp on anterior hemorrhoid.

PATHOLOGICAL REPORT

Gross. Specimen consists of a pinkish elongated polyp-like mass 2 by 0.5 cm. in size, exhibiting a slight circular constriction near its center. This mass is attached to mucosa and seems to possess a small pedicle.

Microscopic. Simple polyp.

Case III. (Record no. 3486, lab. no. 798)

CLINICAL HISTORY

Male, aged sixty years, native of U. S. A.

Family History. Irrelevant.

Duration of Symptoms. Not stated.

Onset. Pruritus ani.

Chief Symptoms and Signs. Pruritus ani.

Operative Findings. Adenoma of rectum approximately 2.5 by 4 cm. in size, situated about 10 cm. from the anal orifice.

Operative Procedure. Tumor removed by snare through proctoscope.

PATHOLOGICAL REPORT

Gross. Specimen consists of firm, solid, delicately lobulated tumor mass 1.2 by 1 cm. in size, attached to a small pedicle.

Microscopic. Polypoid adenoma.

Case iv. (Record no. 3457, lab. no. 792)

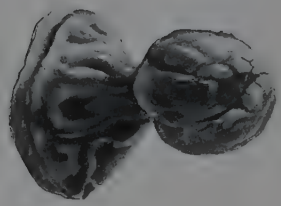

FIG. 17. POLYPOID ADENOMA OF THE DESCENDING COLON ASSOCIATED WITH PIGMENTATION OF THE MUCOSA. SPECIMEN 792.

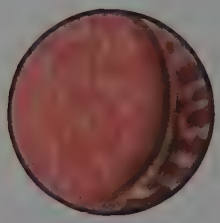

FIG. 18. SIGMOIDOSCOPIC VIEW OF PIGMENTED MUCOSA SHOWING A MARKED CONTRAST TO THE ADJACENT NORMAL MUCOSA. THIS PICTURE WAS MADE BEFORE OPERATIVE REMOVAL OF SPECIMEN 792.

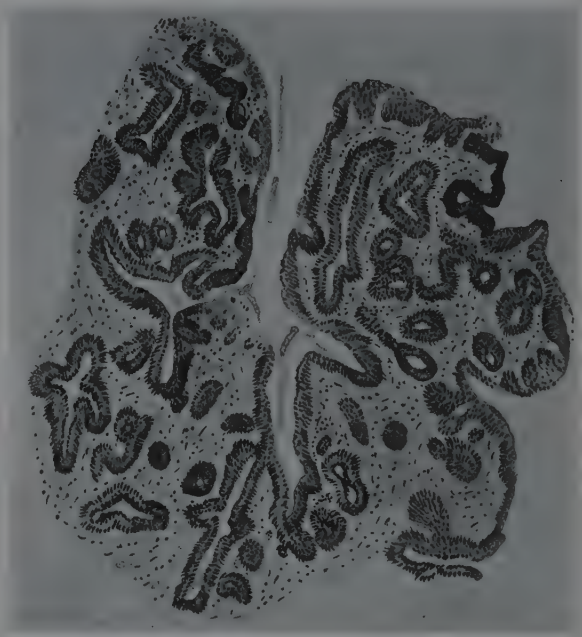

FIG. 19. MICROSCOPIC VIEW OF SUPERFICIAL EPITHELIUM IN SIMPLE ADENOMA OF THE COLON ASSOCIATED WITH PIGMENTATION. NOTE ALMOST COMPLETE ABSENCE OF PIGMENT DEPOSIT. SPECIMEN 792.



FIG. 20.

FIG. 20. DISTRIBUTION OF PIGMENT IN A SPECIMEN EXHIBITING PIGMENTATION OF THE COLON. NOTE THE DEPOSITS IN SMALL CLUMPS BETWEEN THE GLANDULAR TUBULES AND THE APPARENT OBSTRUCTION OFFERED TO FURTHER ADVANCE OF THE PIGMENT BY THE MUSCULARIS MUCOSAE. SPECIMEN 792.

CASE IV. (Record no. 3457, lab. no. 792)

CLINICAL HISTORY

Female, married, aged forty-three years, native of U. S. A.

Family History. Irrelevant.

Duration of Symptoms. Three to four years.

Onset. Hemorrhage from bowels.

Chief Symptoms and Signs. Constipation, excessive flatus, bloody and mucoid stools.

Remarks. Menopause one year previous.

Loss of Weight. Marked (amount not known).

Physical Examination (relevant). Pigmented colon with small adenoma of descending colon.

Laboratory Data. Urine normal. Stool negative for ova and parasites. Examination of gastric contents normal. Phenolsulphonephthalein excretion 61 per cent in two hours. Blood chemistry normal. Wassermann test negative.

Operative Findings. Pigmentation of colon; adenoma of descending colon.

Operative Procedure. Excision of tumor.

PATHOLOGICAL REPORT

Gross. Specimen consists of an oval portion of intestine 2.5 by 3 cm. in size. The mucosa exhibits an extremely dark brown to slate-colored pigmentation. Near the center is seen an oval, pedunculated, solid pinkish to slate-colored tumor 1.5 by 1.2 cm. in size attached to the apex of what appears to be redundant mucosa.

Microscopic. One can see the deposition of a rich brown pigment in the interstitial tissue between the tubules of the mucosa. This pigment does not extend beyond the mucosa, much of it being heaped up against the muscularis mucosae, which apparently acts as a barrier. The tumor mass is a polypoid adenoma.

Adenoma. Adenomata of the colon and rectum usually occur as small or large, single or multiple, sessile or polypoid masses projecting like blackberries into the lumen of the gut. They originate in the mucosa and are probably produced as the result of a localized inflammatory overgrowth of the normal glandular elements. Excessive response to functional stimuli, minor anatomical disturbances in the blood supply or misplaced and embryonal portions of glandular tissue have also been offered as possible explanations of the origin of adenomata. The pedicle is often of considerable length because of constant traction and may actually exert enough force during efforts at evacuation to produce prolapse of the entire rectum. Multiple polypoid adenomata (multiple polyposis, colitis polyposa) may involve the mucosa of the entire large intestine and, as seen in our specimen, thousands of these polypoid masses may project from the mucosa of the gut wall. The size of the individual tumors may vary from 1 to 20 mm. with pedicles 3 to 50 mm. in length. The single sessile flat adenomatous tumor is probably most frequently found in the rectum where the tendency to malignant change is most marked.

The rectum and colon are probably the most frequent seats of multiple polyposis, but cases have been reported affecting the duodenum, jejunum and ileum (Lubarsch, Niemack, Petrow). Hauser and Kaufman saw the entire gastrointestinal tract involved. Albu found isolated portions of the sigmoid and rectum affected. Thorebecke[113] reviewed 34 cases in which he found the distribution of the tumors to be as follows: 23 in the rectum, 5 in the colon and rectum and 6 in the colon alone. Mummery, Verse and others regard multiple adenomata as evidence of a present or previously existing inflammatory or irritative process. Thus they may be found below a chronic malignant stricture or associated with intestinal parasites and chronic inflammatory conditions. So, too, their disappearance has sometimes followed

sidetracking of the intestinal contents. Ewing's observation that there is a diffuse and pronounced hypertrophy of the entire epithelial lining in the early stages of multiple polyposis tends to support the above view as to etiology. The tendency towards carcinomatous degeneration is very marked so that it is not at all uncommon to see several polyps undergoing malignant change in the same specimen.

As already mentioned, adenomata of the large intestine may assume a papillary form, thus giving rise to the beautiful arborescent structure often referred to as a villous tumor. Like other types of adenomata the papillary tumor is richly endowed with blood-vessels. The tendency to become malignant has long been recognized.

A condition described by Virchow as "colitis polyposa cystica" may occasionally be confused with the benign polyp or polypoid adenoma. This condition, however, is merely the result of a healing process in chronic ulcerative colitis.[45] Polypoid projections are produced by the islands of intact epithelium, small retention cysts forming through the blocking of tubular orifices by contracting scar tissue.

Upon section the adenoma is seen to consist of a fibrovascular framework supporting normal glandular tubules lined by normal columnar epithelium. The epithelial cells maintain their typical arrangement upon a basement membrane and retain their normal polarity. Gland ducts, stroma and vessels are reproduced perfectly. The more atypical adenomata are devoid of definite function, differentiated ducts, specific stroma and membrana propria in the order named (Ewing). Langerhans and Lubarsch find a definite membrana propria in most adeno nata. The tumor mass is covered by simple columnar epithelium. Mummery holds that this type of intestinal tumor originates in the submucosa, probably in the solitary follicle. As the mass grows and protrudes into the bowel lumen it receives a covering of mucosa.

CASE V. (Record no. 724, lab. no. 866½)



FIG. 21. MULTIPLE POLYPOID ADENOMATA OF THE ASCENDING AND TRANSVERSE COLON. NOTE THE VARIATIONS IN SIZE OF THE TUMOR MASSES WHICH ARE SESSILE AS WELL AS PEDUNCULATED. THE SMALLER, EARLY ADENOMATA ARE USUALLY SESSILE AND ONLY AT A LATER PERIOD DO THEY BECOME POSSESSED OF A PEDICLE OF MUCOSA PROBABLY AS THE RESULT OF TRACTION. SPECIMEN 866½.

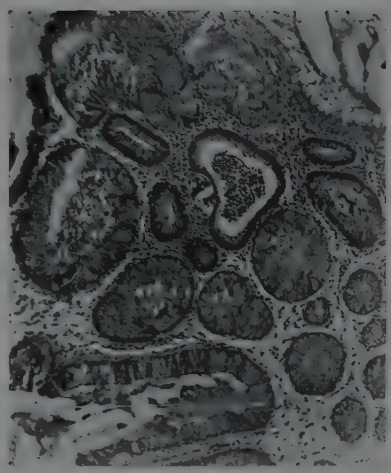

FIG. 22. A TYPICAL ADENOMA REPRODUCES ALVEOLI, DUCTS, MEMBRANA PROPRIA, STROMA AND VESSELS IN AN ORDERLY MANNER. THE STROMA AS WELL AS THE GLAND CELLS PROBABLY PARTICIPATE IN THE NEOPLASTIC FORMATION. FUNCTIONAL CAPACITY IS PROBABLY RETAINED BY MOST ADENOMATA. SPECIMEN 866½.

CASE V. (Record no. 724, lab. no. 866½)

CLINICAL HISTORY

Female, single, aged twenty-three years, native of U. S. A.

Family History. One sister died of multiple polyposis of bowel.

Duration of Symptoms. Five years.

Onset. Severe cramps, accompanied by diarrhea.

Chief Symptoms and Signs. Cramps, diarrhea, bloody stools, weakness, bearing down sensation in abdomen.

Loss of Weight. Twelve pounds within one year.

Laboratory Data. Roentgenogram shows three sharply localized filling defects in the sigmoid loop.

Operative Findings. Multiple polyposis of the colon.

Operative Procedure. Colectomy (ascending, transverse colon).

PATHOLOGICAL REPORT

Gross. Specimen consists of a portion of the large intestine including cecum, appendix, ascending and a major portion of the transverse colon. Length approximately 32.5 cm. Distributed along the course of the intestine and attached to the mucosa in most cases by a short pedicle, may be seen about forty isolated solid tumor masses separated from each other by varying amounts of intact mucosa and ranging in size from 3 to 30 mm. There are also seen a few minute sessile tumors which probably represent an early stage of the type above described. Two of the largest tumors have assumed a papillary form.

Microscopic. Polypoid adenomata. Papillary adenomata.

CASE VI. (Record no. 2904, lab. no. 578)



FIG. 23. REMARKABLE SPECIMEN OF MULTIPLE POLYPOID ADENOMATA COVERING THE ENTIRE COLON AND PART OF THE SMALL INTESTINE. HARDLY AN AREA OF INTACT MUCOSA REMAINS. SPECIMEN 578.

FIG. 24. DRAWING OF A SMALL AREA FROM SPECIMEN 578 EXHIBITING THE DISTRIBUTION OF THE TUMOR MASSES IN GREATER DETAIL.

(For Fig. 25, Case VI, see second page following.)

Case VI. (Record no. 2904, lab. no. 578)

CLINICAL HISTORY

Male, aged forty-five years, native of Portugal.

Family History. Irrelevant.

Duration of Symptoms. Eight months.

Onset. Involuntary defecation during sleep.

Chief Symptoms and Signs. Diarrhea.

Remarks. For a short period about three years previously noted specks of blood in stools.

Loss of Weight. None.

Physical Examination (relevant). Multiple polypoid adenomata of the colon.

Laboratory Data. Urine contains albumin and casts. Wassermann reaction negative. Blood count and morphology normal. No ova or parasites in stool.

Operative Findings. Multiple polypoid adenomata of the colon.

Operative Procedure. Colectomy.

PATHOLOGICAL REPORT

Gross. Specimen submitted consists of approximately 90 cm. of colon studded on its mucous surface with thousands of sessile and pedunculated oval, firm tumors projecting into the lumen like blackberries and varying in size from 0.5 cm. to 1.5 cm. These tumor masses (1) are situated in such close proximity to each other that hardly a centimeter of intact mucosa remains. At one point there appears to be an oval, ulcer-like area approximately 1.5 cm. in its longest diameter and possessing a raised indurated margin (2).

Microscopic. (1) Simple polypoid adenoma.
(2) Malignant adenoma.

FIG. 25. AN INFLAMMATORY ADENOMATOID HYPERPLASIA PROBABLY PRECEDES THE FORMATION OF TRUE POLYPOID TUMORS. THE GLANDS BECOME HYPERTROPHIC AND THE LINING CELLS INCREASE IN SIZE AND NUMBER. A REDUPLICATION OF CELL LAYERS IS UNCOMMON. SPECIMEN 578.

The same author makes a clinical classification of polypoid adenomata of the colon as follows:

(1) True multiple adenomata.

(*a*) The entire colon is almost covered with small semipedunculated polypi.

(*b*) Numerous polypi varying in size and shape, sessile and pedunculated. The sessile type is regarded as an early stage in the development of the pedunculated variety. The polypi all seem to project from the edges of the valvulae conniventes and nearly always an accompanying inflammation of the intestinal mucosa and always a tendency toward malignancy, especially in the sigmoid and rectum where the polyps are subject to trauma by hardened feces.

(2) Polypi associated with hyperplastic tuberculosis usually occurring in or just above a stricture.

(3) Polypi associated with an old stricture. These are filiform structures of bizarre shape and are found in the immediate vicinity of a stricture.

(4) Polypi associated with ulcerative colitis. It is interesting to note that White, making serial sections of a rectal polypoid adenoma, found lateral sacculi, communications between adjoining acini and multiplication of surface openings (Ewing).

At this point it might be well to mention a condition known as pigmentation of the colon. This is a comparatively rare affection of the colon and rectum in which the mucosa appears to be slate-colored or black, the pigment being distributed diffusely or in a stippled manner. The term "melanosis" has been used by Sir John Bland-Sutton to describe this appearance in a case reported by him in which the pigment began sharply at the ileocecal valve. Microscopically, we have found this appearance to be due to an iron-containing pigment not deposited in the cells, as described by some, but scattered in small and large irregular clumps in the interstitial tissue of the

mucosa. It is an extracellular pigment probably the result of old hemorrhages. In the specimen just referred to we (Felsen) found a sharp limitation of the pigment by the muscularis mucosae, against which it was heaped in large irregular clumps. We have been impressed by the relative frequency with which this condition is associated with toxic and highly nervous states and with adenomata. Clinically, it seems to be related in some way to a disordered function of the thyroid or adrenals or both.

Carcinoma. This is by far the most important type of epithelial tumor occurring in the rectum and colon.

General Considerations. Certain gross characteristics are more or less common to carcinomata, regardless of location. Their clinical significance is based upon certain pathological changes:

(1) Induration of the affected tissue is due to extreme density resulting from the desmoplastic power of this type of tu nor. Induration often signifies fixation to the surrounding tissues or is evidence of deep infiltration.

(2) The cicatricial character of many carcinomata makes the surrounding tissue appear to be drawn toward the carcinomatous focus.

(3) Hyaline swelling of the fibrous tissue in a carcinomatous tumor may actually lead to an increase in its size.

(4) Marked induration usually signifies slow progress of the local lesion.

(5) A very cellular carcinoma does not exhibit marked induration. It exhibits a rounded or convoluted border and a peripheral margin of congestion or hemorrhage which marks the growing edge. The center of the tumor mass is often ulcerated and depressed from cicatricial contraction.

(6) Degenerative changes in carcinomatous tumors are quite common (e.g., gelatinous carcinoma of the colon).

(7) The carcinomatous ulcer has a fixed indurated base and hard, raised edges. The regional lymph-nodes are enlarged in the beginning by inflammatory changes and at a later period because of carcinomatous infiltration.

(8) The equilibrium between epithelium and connective tissue is lost in carcinoma but maintained in papilloma and adenoma.

A study of the microscopic appearance of carcinomatous tissue brings forth certain characteristics worthy of note.

(1) Cellular overgrowth, indicating abnormal powers of proliferation.

(2) Atypical qualities of the cells—hypertrophy, increase in the chromatin content of the nucleus (indicative of increased nutrition and power of growth), abundance of mitoses (some atypical) and anaplasia (change in the type of cell).

(3) Heterotopia or advancement of the proliferating epithelium beyond normal limits.

(4) Local invasive and destructive properties. The tissue spaces, lymphatics and blood-vessels are infiltrated, possibly due to mechanical forcing of cells through hernias and tears in the distended basement membrane. Carcinoma travels by preference through the lymphatics. Lymphatic invasion is attended by perilymphangitis with fibrosis and atrophy of the tumor cells, or by no reaction at all. Much variation exists in the resistance of various tissues to carcinomatous invasion. Thus arteries and tendons are very resistant while bone and cartilage are easily destroyed. Exposed surfaces of a carcinoma are prone to necrosis and ulceration from mechanical trauma or pressure atrophy.

(5) Desmoplastic properties of carcinoma cells. The power of carcinoma to excite a growth of new cellular connective tissue is often very marked. Indeed, the newly formed connective tissue may exceed in bulk that of the tumor cells. This new connective tissue contains lymphocytes and plasma cells, capillary blood-vessels and endothelium, and proliferating fibroblasts with a soft mucinous stroma. There may be an acellular fibrous tissue. This connective tissue probably represents a protective reaction to the invading carcinoma cells.

(6) Loss of polarity, usually observed in a diffusely growing carcinoma.

(7) Power to produce distant metastatic tumors.

It is usually observed that a recurrent carcinoma is more atypical and malignant than the original tumor.

We have occasionally observed a very extensive infiltration by eosinophiles of the connective-tissue stroma in adenocarcinomata of the large intestine. The significance of the presence of these cells in such great numbers is not clearly understood. Their occurrence in some specimens and not in others suggests a definite biological foundation for their presence. In the case pictured (specimen 1162) there appeared to be no definite reason for a tissue eosinophilia. No eosinophiles were found in the blood upon repeated examination and there were no intestinal parasites to account for their presence in the intestinal mucosa. For a review and bibliography of tissue eosinophilia the reader is referred to Krehl and Marchand.*

For completeness, carcinoma of the appendix[16] is included in this study of tumors of the colon. In the appendix, the carcinoma resembles in structure the basal cell tumor of the skin. It is usually a perfectly benign growth and is often accidentally noted at the post-mortem table or in the routine gross or microscopic examination of operative specimens. The tumor, if visible, is likely to be seen at the tip of the appendix as a small nodule which projects slightly above the mucosa. It gives a small bulbous appearance to the terminal portion of the intact appendix. In many cases it may be associated with chronic appendicitis. Growth is very slow and only in rare instances does the tumor extend (*cf.* Ref. 4, 28, 51, 55, 78, 122), first involving the mesenteric and retroperitoneal lymph-nodes. Other gross pictures have been described, such as cystic degeneration, mucocele, obliteration of the lumen by scar tissue and ulcer. Microscopically, the usual appearance is that of small spheroidal

* Krehl, L., and Marchand, F. Handbuch der Allgemeinen Pathologie, 1924, i, 361–377.

cells grouped in small or large compact masses. The nuclei are large and hyperchromatic. In another type the cells are of the columnar adenocarcinoma variety which may undergo extensive mucous degeneration. McWilliams[70] (with the assistance of F. C. Wood) reports a series of 90 cases of primary carcinoma of the appendix, making the following pathological classification of 71 of the specimens:

(1) Columnar cell tumors, 22 per cent.

(2) Spheroidal cell cancer, 53 per cent.

(3) Mixed types.

(4) Columnar cell cancer undergoing spheroidal cell transformation, 9 per cent.

(5) Colloid cancer, 4 per cent.

Enlarged glands were present in 8 of the cases but carcinomatous involvement proved in 1 only.

The heterotopic groups of cells in a carcinomatous (more properly termed carcinoid) tumor of the appendix probably represent collections of epithelial cells dislocated in the process of development. The microscopic picture, according to Aschoff, is comparable to the groups of nevus cells present in pigmented moles of the skin.

Carcinoma of the large intestine usually arises (*cf.* Ref. 20, 42, 69, 70, 125) in a very limited area of the mucosa, from the crypts of Lieberkühn. The glands enlarge as the lining cells increase in size and number and the lumina become elongated and distorted. As soon as the glandular epithelium breaks through the muscularis mucosae the submucosal lymphatics may be invaded, although this is usually a late occurrence. Cheatle[17] maintains that the extensive spread of carcinoma in the lymphatic vessels of the submucosa is not very common. It seems to be true, however, that in many cases the submucosal lymphatics act as an effective barrier to the spread of carcinoma cells for a considerable time. In the submucosa the growth may spread later-

Case vii. (Lab. no. 618)

FIG. 26. CARCINOMA (CARCINOID TUMOR) OF THE APPENDIX. IT IS QUESTIONABLE WHETHER THIS RELATIVELY BENIGN TYPE OF TUMOR SHOULD PROPERLY BE IDENTIFIED WITH THE CARCINOMATA. SPECIMEN 618.



FIG. 27. THE USUAL MICROSCOPIC APPEARANCE OF CARCINOMA OF THE APPENDIX IS THAT OF SMALL SPHEROIDAL CELLS WITH LARGE HYPERCHROMATIC NUCLEI GROUPED IN COMPACT MASSES. SPECIMEN 618.

Case vii. (Lab. no. 618)

CLINICAL HISTORY

Female, single, aged seventeen years.

Chief Symptoms and Signs. For the past eight years patient has suffered from occasional abdominal cramps. Constipation present. Twenty-four hours before admission generalized abdominal pain later localized to the right lower quadrant. No nausea or vomiting. (Dr. J. L. Amster.)

PATHOLOGICAL REPORT

Gross. Specimen consists of appendix 5 cm. in length. At the extreme tip of the opened appendix there is seen a small, clearly demarcated, pinkish, sessile, rounded nodule 10 by 8 mm. in size projecting 3 or 4 mm. above the adjacent mucosa.

Microscopic. Carcinoid tumor of the appendix.

ally, undermining the mucosa or even sending up prolongations of cancerous tissue into it. In other cases the tumor may penetrate the deeper layers, invading the intramuscular, intermuscular and subserous lymphatic plexuses. The circular disposition of the lymphatic vessels of the intermuscular plexus probably accounts for the frequent circular distribution of carcinoma of the large intestine. Invasion of the lymph-nodes through the lymphatics may occur at any time after the growth has reached the submucosa. As a rule,

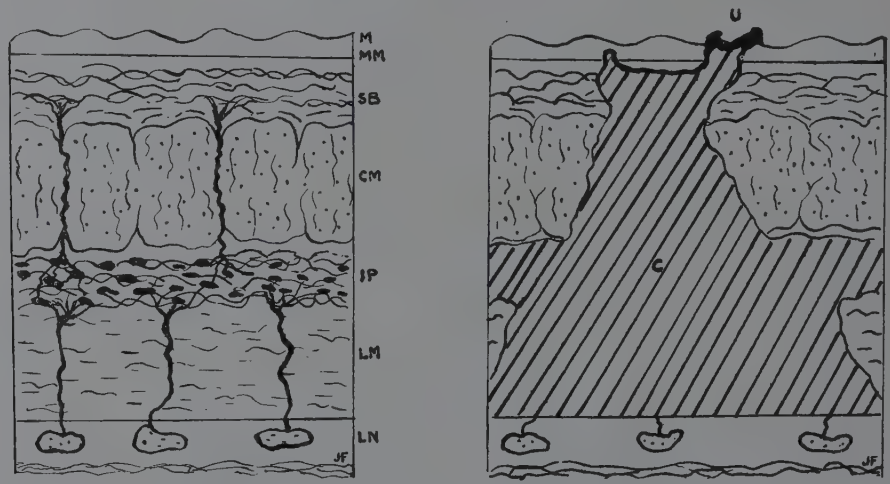

FIG. 28. THE INTRAMURAL SPREAD OF CARCINOMA OF THE COLON OR RECTUM. ILLUSTRATION ON THE LEFT SHOWS THE LARGE SUBMUCOUS AND INTERMUSCULAR LYMPHATIC PLEXUSES, (M—MUCOSA, MM—MUSCULARIS MUCOSAE, SB—SUBMUCOSA, CM—CIRCULAR MUSCLE COAT. IP—INTERMUSCULAR LYMPHATIC PLEXUS, LM—LONGITUDINAL MUSCLE COAT, LN—LYMPH NODES). THE ILLUSTRATION ON THE RIGHT IS INTENDED TO PORTRAY THE SPREADING EFFECT OF CARCINOMA (C) AS IT INVADES SUCCESSIVE LAYERS OF THE GUT WALL. NOTE ALSO THE RELATIVELY SMALL ULCERATION OF THE MUCOSA (U) WHILE THE MALIGNANT PROCESS IS SPREADING ALONG THE SUBMUCOSAL LYMPHATIC PLEXUS, POSSIBLY TO REAPPEAR ON THE MUCOSA AT A DISTANT POINT (FELSEN).

however, the lymph-nodes are not invaded until late, most carcinomata being inoperable rather because of their local extension. Metastatic deposits may reach the liver through the portal circulation. In 100 operative specimens studied by McVay[69] 53 per cent showed no metastatic involvement of

Case viii. (Record no. 4444, lab. no. 1162)



FIG. 29. ULCERATED ADENOCARCINOMA OF THE RECTUM. SPECIMEN 1162.

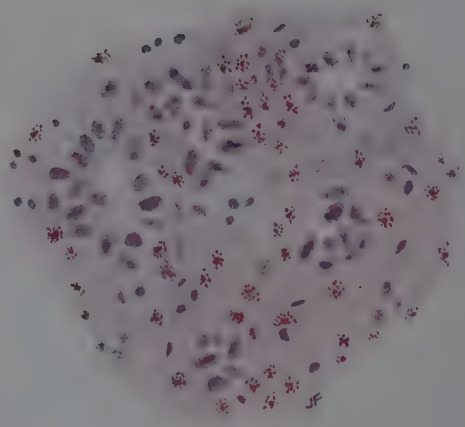

FIG. 30. NOTE EXTENSIVE EOSINOPHILIC INFILTRATION OF THE CONNECTIVE-TISSUE STROMA. SPECIMEN 1162.

CASE VIII. (Record no. 4444, lab. no. 1162)

CLINICAL HISTORY

Female, aged thirty-seven, native of U. S. A.

Family History. One paternal aunt had "cancer of the liver."

Duration of Symptoms. Ten months.

Onset. Diarrhea (ten to twelve bowel movements a day).

Chief Symptoms and Signs. Diarrhea alternating with constipation, occasional bloody stool. Spurious diarrhea (passes very little material). Bowel never feels quite empty.

Loss of Weight. Twelve pounds.

Remarks. Hemorrhoidectomy. Operation for fissure and fistula in ano seven years ago.

Physical Examination (relevant). Large hard mass on anterior rectal wall approximately 5 cm. above the anal margin.

Laboratory Data. Wassermann test negative. Blood chemistry normal.

Hemoglobin, per cent	R.B.C.	Remarks
70	4,200,000	1 day before operation
80	4,600,000	Day of operation. Transfusion
55	3,100,000	1 day after operation
62	3,900,000	4 days after operation
55	3,500,000	7 days after operation
65	3,500,000	18 days after operation

Operative Findings. Large carcinomatous mass on anterior and lateral rectal wall. All pelvic lymph-nodes enlarged. Liver not involved.

Operative Procedure. Abdominal proctectomy.

PATHOLOGICAL REPORT

Gross. Specimen consists of large intestine, presumably rectum, exhibiting near one end an irregularly rounded, dark red tumor mass with a sinuous border of firm, elevated, heaped-up tissue and a shallow, excavated central area of ulceration. The latter makes up most of the area of the tumor.

Microscopic. Adenocarcinoma without evident microscopic involvement of the lymph-nodes. Extensive eosinophilic infiltration of the stroma is present.

Case ix. (Lab. no. 615)

FIG. 31. IT IS OFTEN DIFFICULT TO DEFINITELY SEPARATE AN ADENOMA MALIGNUM FROM ADENOCARCINOMA. THE TWO BLEND IMPERCEPTIBLY. THIS SPECIMEN EXHIBITS A MALIGNANT NEOPLASTIC PROCESS WHICH HAS PROBABLY BEEN GRAFTED UPON A BENIGN ADENOMATOUS POLYP. NOTE THE BENIGN POLYPOID ADENOMA SEPARATED BY A SMALL AREA OF MUCOSA FROM THE UPPER POLE OF THE LARGE MALIGNANT TUMOR MASS. SPECIMEN 615.

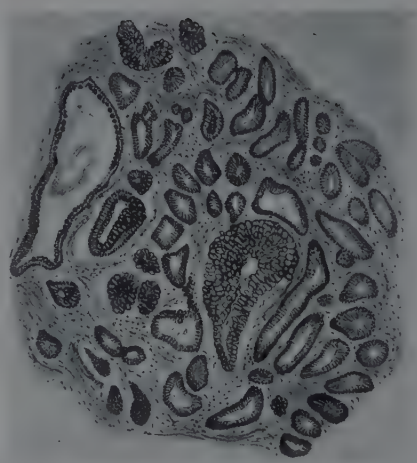

FIG. 32. CELLULAR OVERGROWTH, CELL DEGENERATION, DEFICIENT STROMA, HYPERCHROMATISM, MULTIPLICATION OF CELL LAYERS AND ABSENCE OF MEMBRANA PROPRIA ARE SEEN IN ADENOMA MALIGNUM. IN MOST CASES REPEATED MICROSCOPIC SECTION OR THE FUTURE CLINICAL COURSE WILL DEMONSTRATE THE TRUE CARCINOMATOUS CHARACTER OF THIS TYPE OF NEOPLASM. SPECIMEN 615.

Case IX. (Lab. no. 615)

CLINICAL HISTORY

Male, aged fifty-nine years, native of Germany.

Family History. Irrelevant.

Duration of Symptoms. Five months.

Onset. Sudden constipation.

Chief Symptoms and Signs. Dull aching pain in the left lower quadrant, diarrhea alternating with constipation, bloody stools.

Loss of Weight. None.

Physical Examination. Tumor mass in the sigmoid.

Laboratory Data. Blood: Hemoglobin 75 per cent, erythrocytes 4,610,000 per c.mm., leucocytes 10,000 per c. mm., polymorphonuclear neutrophiles 77 per cent, small lymphocytes 22 per cent, large lymphocytes 1 per cent. Urine: Trace of albumin, occasional cast. Feces: Free blood present.

Operative Findings (Dr. J. L. Amster). Large tumor of the sigmoid 12 cm. in length reaching as far as 17 cm. above the internal sphincter.

Operative Procedure. Resection of sigmoid. End-to-end anastomosis.

PATHOLOGICAL REPORT

Gross. Specimen consists of 16 cm. of large intestine. Near the lower margin is seen a clearly demarcated, pinkish to reddish, protuberant nodular sessile mass the edge of which slightly overhangs the adjacent mucosa. The center is the site of a small elliptical excavated ulcer. Just beyond the upper margin of this mass and separated by a narrow island of apparently normal mucosa is an adenomatous polyp 10 by 12 mm. in size.

Microscopic. Adenocarcinoma.

Case x. (Record no. 2668, lab. no. 517)

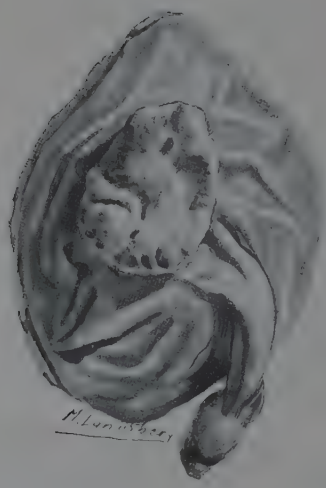

FIG. 33.

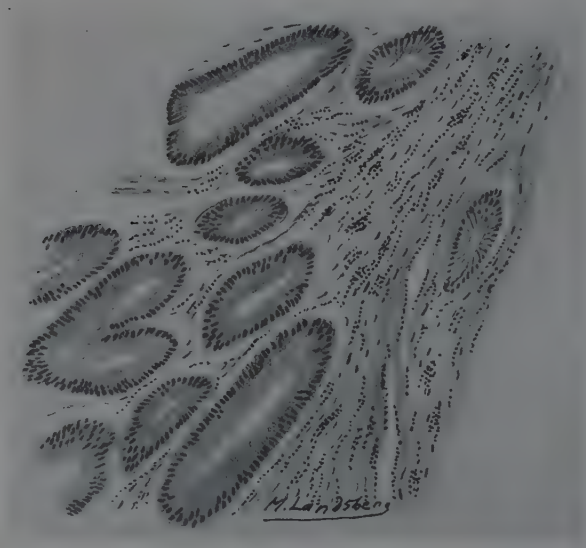

FIG. 34.

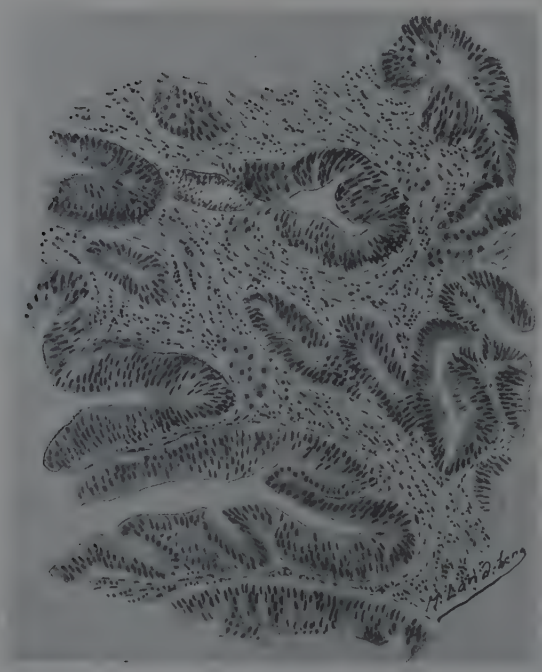

FIG. 35.

FIG. 33. ADENOMA MALIGNUM WHICH HAS BECOME CARCINOMATOUS, AND BENIGN POLYPOID ADENOMA OF THE SIGMOID. THE FREQUENT COEXISTENCE OF BENIGN AND MALIGNANT EPITHELIAL TUMORS OF THE COLON AND RECTUM SIDE BY SIDE SUGGESTS A CLOSE ETIOLOGICAL RELATIONSHIP. SPECIMEN 517.

FIG. 34. SIMPLE ADENOMA. MICROSCOPIC VIEW OF POLYPOID ADENOMA. SPECIMEN 517.

FIG. 35. ADENOCARCINOMA. MICROSCOPIC VIEW OF SESSILE TUMOR MASS, SPECIMEN 517. NOTE CELLULAR OVERGROWTH, ANAPLASIA AND INVASIVE TENDENCY ON THE PART OF THE TUMOR CELLS. DISTORTED GIANT ALVEOLI ARE PROMINENT. COMPARE WITH FIGURE 32.

CASE X. (Record no. 2668, lab. no. 517)

CLINICAL HISTORY

Male, aged fifty-four years, native of U. S. A.

Family History. Irrelevant.

Duration of Symptoms. Ten years.

Onset. Constipation, belching of gas, pain and fullness in the "stomach" region.

Chief Symptoms and Signs. As above. Pain occurs three hours after meals. Bloody stool occasionally.

Loss of Weight. None.

Physical Examination (relevant). Small carcinoma of the sigmoid (sigmoidoscopy).

Laboratory Data. Gastric analysis reveals free acidity of 110 and total acidity of 150. Blood picture and urine entirely normal. Feces contain occult blood. Phenolsulphonephthalein excretion normal. Roentgenogram shows presence of a duodenal ulcer and an organic constriction of the sigmoid.

Operative Findings. Small carcinoma and polyp of sigmoid.

Operative Procedure. Resection of 5 cm. of sigmoid. End-to-end anastomosis.

PATHOLOGICAL REPORT

Gross. Specimens consist of:

1. An oval portion of large intestine approximately 3 by 2.5 cm. in size exhibiting on its mucous surface a pinkish, firm, sessile, oval tumor mass with indurated margin and smooth nodular surface raised 0.5 cm. above the mucosa. At one point there seems to be a necrotic pea-sized crater containing a little yellowish debris. About 1 cm. distant is seen another tumor mass which is purplish, oval, pedunculated and apparently attached to redundant mucosa.
2. Two lymph-nodes 12 and 4 mm. in size and quite firm.

Microscopic. 1. Adenoma destruens. Polypoid adenoma.

2. No metastatic involvement of lymph-nodes noted.

CASE XI. (Record no. 4513, lab. no. 1185)



FIG. 36. ADENOCARCINOMA OF THE SIGMOID. SPECIMEN 1185.

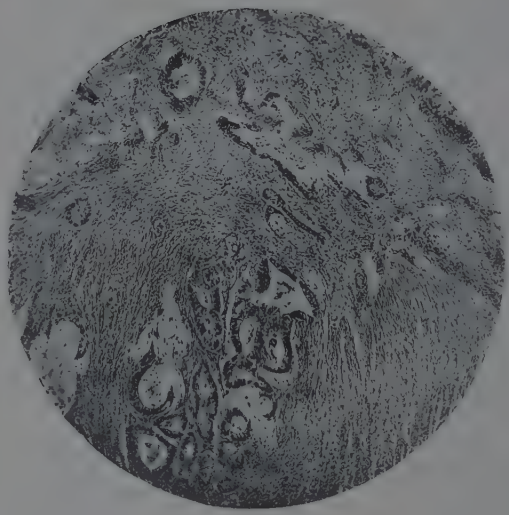

FIG. 37. ADENOCARCINOMATOUS TISSUE HAVING INVADED THE SUBMUCOSAL LYMPHATICS (UPPER PART OF PICTURE) IS NOW SPREADING THROUGH THE INTRAMUSCULAR PLEXUS. SPECIMEN 1185.

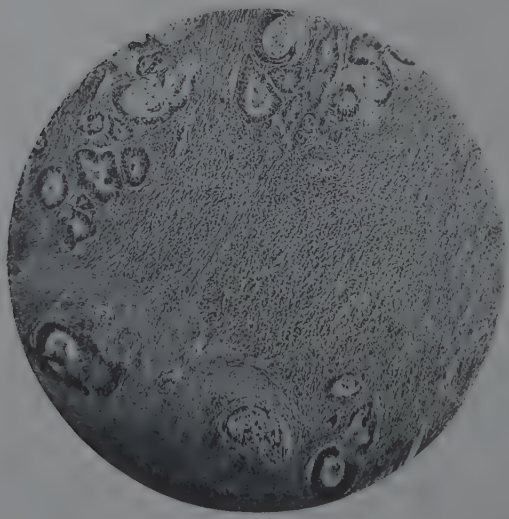

FIG. 38. ADENOCARCINOMATOUS TISSUE HAS ALREADY REACHED THE INTERMUSCULAR LYMPHATIC PLEXUS. SPECIMEN 1185.

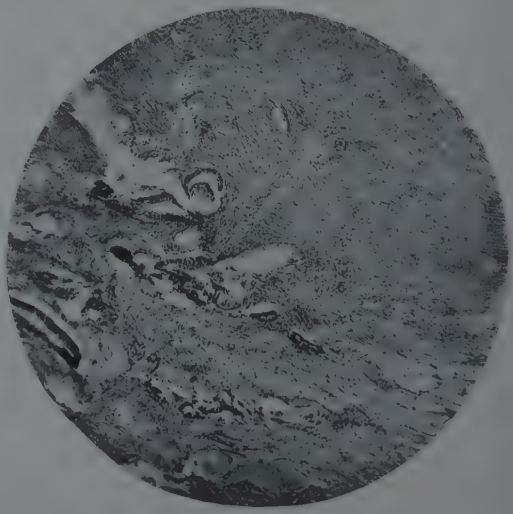

FIG. 39. INVASION OF THE SUBPERITONEAL CONNECTIVE TISSUE HAS ALSO OCCURRED. SPECIMEN 1185. SEE FIG. 35.

Case xi. (Record no. 4513, lab. no. 1185)

CLINICAL HISTORY

Male, aged fifty-eight, native of U. S. A.

Family History. Irrelevant.

Duration of Symptoms. Not known.

Onset. Gradually increasing constipation.

Chief Symptoms and Signs. Increasing constipation.

Loss of Weight. None.

Physical Examination (relevant). Mass in sigmoid.

Laboratory Data. Wassermann test negative.

Operative Findings. Non-rotated colon. Extensive carcinoma of sigmoid located about 18 cm. above anal margin, adherent to small intestines.

Operative Procedure. Resection of sigmoid.

PATHOLOGICAL REPORT

Gross. Specimen consists of approximately 18 cm. of large intestine exhibiting near its center a hard, circumventing, constricting mass not much raised above the mucous surface. This mass narrows the lumen of the gut considerably and penetrates the wall to the peritoneal surface, giving the latter a distinctly puckered appearance. No involved nodes discernible but two suspicious nodules excised for examination.

Microscopic. Adenocarcinoma, showing beautifully the spread along submucous, intramuscular, intermuscular and subserous plexuses. Nodules are carcinomatous but there is no semblance of lymph-node structure.

Case xii. (Record no. 2793, lab. no. 784)

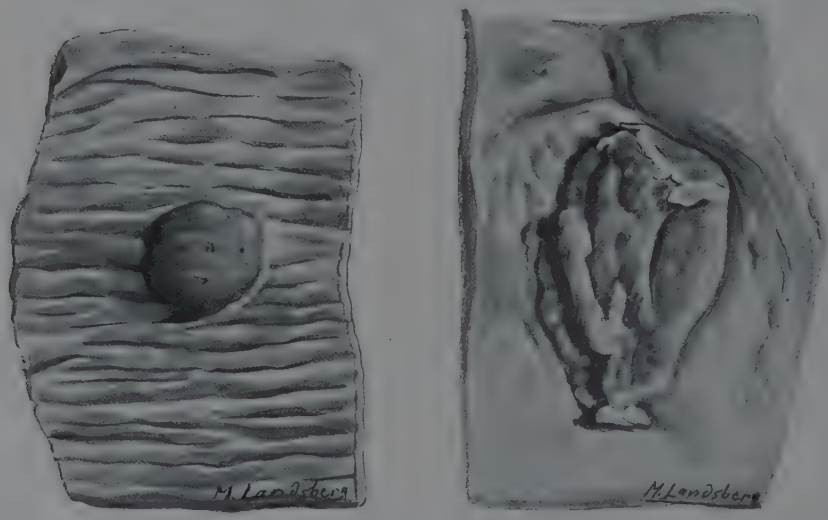

A B

FIG. 40. CARCINOMA OF THE ILEUM PROBABLY HAVING AS ITS PRECURSOR A BENIGN ADENOMA. NOTE IN THIS SPECIMEN THE TENDENCY OF CARCINOMA OF THE INTESTINE TO SPREAD LATERALLY AS IT PENETRATES THE GUT WALL SO THAT THE TUMOR APPEARING UPON THE PERITONEAL SURFACE (B) IS MUCH LARGER THAN THE MASS PROJECTING FROM THE MUCOSA (A). SPECIMEN 784.

FIG. 41. OPERATIVE FIELD. TUMOR IN SITU. IN THIS CASE THE PERITONEAL SURFACE OF THE TUMOR MASS HAD BECOME ADHERENT TO THE SIGMOID PRODUCING A STRICTURE IN THE LATTER. SPECIMEN 784.

(For Fig. 42, Case xii, see second page following.)

CASE XII. (Record no. 2793, lab. no. 784)

CLINICAL HISTORY

Male, aged thirty-two years, native of Japan.

Family History. Negative.

Duration of Symptoms. Three weeks.

Onset. Sudden, following meal consisting largely of canned food. Nausea vomiting, sharp pain in the lower abdomen radiating from the back to anterior aspect of abdomen.

Chief Symptoms and Signs. Persistent pain, constipation (chronic). Pain relieved by catharsis.

Loss of Weight. None.

Physical Examination (relevant). Hemorrhoids, fissure in ano, acute mucous colitis.

Laboratory Data (relevant). Roentgen-ray examination reveals stricture at rectosigmoidal junction. Normal blood picture.

Operative Findings. Ileum and sigmoid bound inseparably in what appeared to be an inflammatory mass.

Operative Procedure. Fifteen centimeters of small intestine resected. End-to-end anastomosis.

PATHOLOGICAL REPORT

Gross. Specimen consists of approximately 15 cm. of small intestine showing at the junction of middle and terminal thirds a small, sessile, soft, reddish, slightly elevated tumor mass 2 by 2.2 cm. in size. Margin appears to be slightly everted. This mass penetrates the intestinal wall, appearing upon the peritoneal aspect as a flattened, slightly elevated 4 by 3 cm. plaque with indurated margins.

Microscopic. Carcinoma (adenoma destruens).

CASE XII. (Record no. 2793, lab. no. 784) (*Continued*)

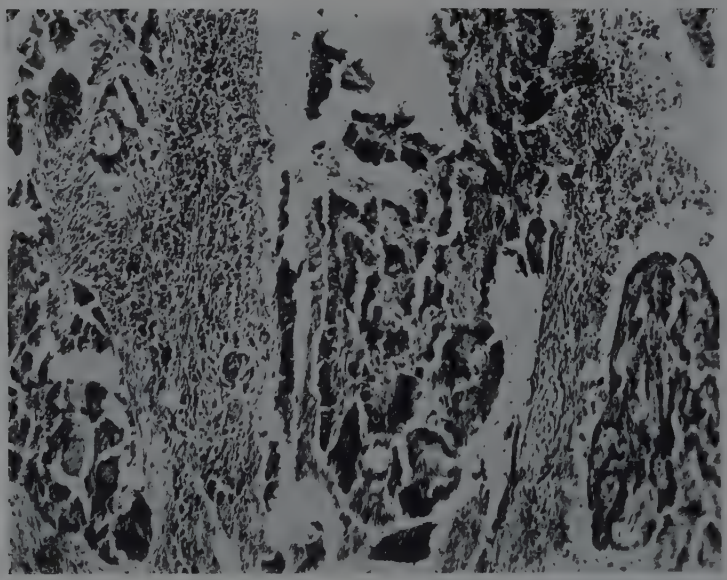

FIG. 42. THIS TYPE OF CARCINOMA IS RAPIDLY INVASIVE. ANAPLASIA, HETEROTOPIA, HYPERCHROMATISM AND ABUNDANCE OF MITOSES CHARACTERIZE THE CELLULAR ELEMENTS. THERE IS ALSO A MODERATE AMOUNT OF NEWLY FORMED CONNECTIVE TISSUE INFILTRATED WITH LYMPHOID CELLS. SPECIMEN 784.

the regional lymph-nodes. In Oehler's[82] 58 autopsies of carcinoma of the rectum, 34 had no internal metastases. Zinner[126] found that out of a series of 141 cases only 3.5 per cent showed involvement of the retroperitoneal nodes. Pennington[87] found regional lymph-node involvement in 324 out of 997 autopsies on cases of carcinoma of the rectum.

As the carcinoma eats its way through the bowel wall there is a tendency for each deeper layer to be more extensively involved so that on cross section a wedge-shaped area may be seen with the base towards the peritoneal surface. At any period in its growth masses of tumor cells may choke off the blood supply of the overlying intact mucosa, thus producing surface ulceration. As the stroma of the invaded area contracts it has a tendency to pull upon healthy uninvolved tissue resulting in an eversion of the margins of the ulcer and puckering of the peritoneum. The rectal fascia tends to limit the further extension of carcinoma in this region.

At the same time as the carcinomatous process is extending in the submucosa it is also carried along the lymphatics, penetrating the bowel wall so that at a comparatively early stage extramural structures may become involved. Fortunately, however, the majority of cases remain localized for a long time. Postoperative recurrences are usually due to infiltration by unremoved extramural carcinoma or contact transference. Mummery, however, cites a case in which he left behind at the time of operation small portions of the growth without recurrence for five to six years thereafter.

The gross appearance of carcinomata of the colon and rectum depends upon their duration, anatomical location and rapidity of growth. The early cases are rarely seen by the clinician or pathologist and usually represent an adenoma undergoing malignant degeneration. One sees a small, reddened, elevated, sessile, rounded mass with a rather indurated border which seems to blend imperceptibly with the surrounding mucosa. There may be a little central necrosis or none at all, depending upon the factors

CASE XIII. (Record no. 4410, lab. no. 1159)



FIG. 43. ADENOCARCINOMA OF THE RECTUM. SPECIMEN 1159.

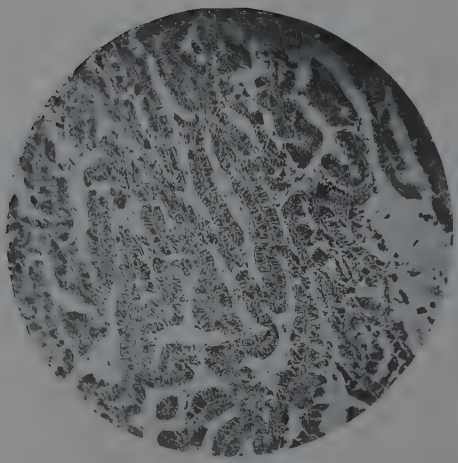

FIG. 44. ADENOCARCINOMA OF THE RECTUM. SPECIMEN 1159.

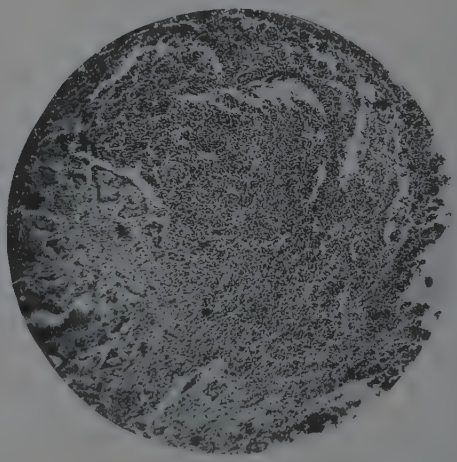

FIG. 45. INVASION OF AN EPICOLIC LYMPH-NODE BY CARCINOMATOUS TISSUE. SPECIMEN 1159.

CASE XIII. (Record no. 4410, lab. no. 1159)

CLINICAL HISTORY

Female, aged thirty-five years, Russian.

Family History. Irrelevant.

Duration of Symptoms. Six months.

Onset. Bloody stools (bright red blood).

Chief Symptoms and Signs. Bloody stools, painful bowel movements, frequency.

Loss of Weight. None.

Remarks. Hemorrhoidectomy ten years ago. Chronic constipation.

Physical Examination (relevant). Large irregular mass felt on posterior rectal wall.

Laboratory Data. Preceding operation: Erythrocytes 2,100,000 per c.mm., hemoglobin 55 per cent (Dare). After operation: Erythrocytes 3,450,000 per c.mm., hemoglobin 55 per cent (Dare), after transfusion. Wassermann test negative.

Operative Findings. Carcinoma of the posterior rectal wall, easily mobilized. Liver not involved.

Operative Procedure. Colostomy followed by resection.

PATHOLOGICAL REPORT

Gross. Specimen consists of 12 cm. of rectum submitted in two pieces, including anus and coccyx. There is seen upon the mucous surface a friable, reddish, fungating tumor mass commencing 4 cm. above the mucocutaneous margin and extending 6 cm. in an upward direction as well as circumventing the wall. The tumor proper is made up of loose projecting soft masses, some almost polypoid. The upper margin is very clearly limited by a sinuous border of soft mucosa while the lower margin is not so clearly visible, gradually blending with mucous membrane. One enlarged lymph-node is seen on the peritoneal surface.

Microscopic. Adenocarcinoma with metastatic lymph-node involvement.

CASE XIV. (Record no. 3647, lab. no. 869)



FIG. 46. ADENOCARCINOMA OF THE RECTUM. THE GREATEST BULK OF THIS TUMOR PROJECTS FROM THE MUCOUS SURFACE OF THE GUT. THIS CHARACTERISTIC TAKEN IN CONJUNCTION WITH THE ABSENCE OF FIXATION TO SURROUNDING ORGANS STAMPS THIS AS A RATHER SLOW-GROWING CARCINOMA. SPECIMEN 869.

FIG. 47. THE INVASIVE NATURE OF EVEN THE RELATIVELY SLOW-GROWING CARCINOMATA OF THE COLON AND RECTUM SHOULD SUGGEST A GUARDED OPERATIVE PROGNOSIS. SPECIMEN 869.

CASE XIV. (Record no. 3647, lab. no. 869)

CLINICAL HISTORY

Female, unmarried, aged fifty-two years, native of U. S. A.

Family History. Irrelevant.

Duration of Symptoms. Five months.

Onset. Blood in stool, occasionally mucus.

Chief Symptoms and Signs. Had always been constipated. Began to have occasional diarrhea. An uncomfortable "soreness" in the rectum, relieved by bowel movement.

Loss of Weight. None. Has actually gained in weight.

Remarks. Menopause three years before.

Physical Examination (relevant). Polypoid growth on posterior rectal wall. Mass has a broad base about 3 cm. in diameter, is hard and apparently freely movable.

Laboratory Data. Chronic renal disease. Blood chemistry normal. Phenolsulphonephthalein excretion 51 per cent in two hours. Hemoglobin 76 per cent. Erythrocytes 3,900,000 per c.mm. Wassermann test negative.

Operative Findings. Small carcinoma 3 cm. in diameter situated on posterior rectal wall.

Operative Procedure. Perineal resection of rectum.

PATHOLOGICAL REPORT

Gross. Specimen consists of approximately 10 cm. of large intestine presenting near its center a sessile, firm, pinkish tumor mass with elevated indurated margin and exhibiting a superficial central necrosis. This tumor does not extend through to the peritoneal coat. Accompanying this specimen there is what appears to be a small lymph-node 3 by 3 mm. in size.

Microscopic. Intestinal tumor—adenocarcinoma. Lymph-node shows no evidence of metastatic involvement.

Case xv. (Record no. 2909, lab. no. 577)

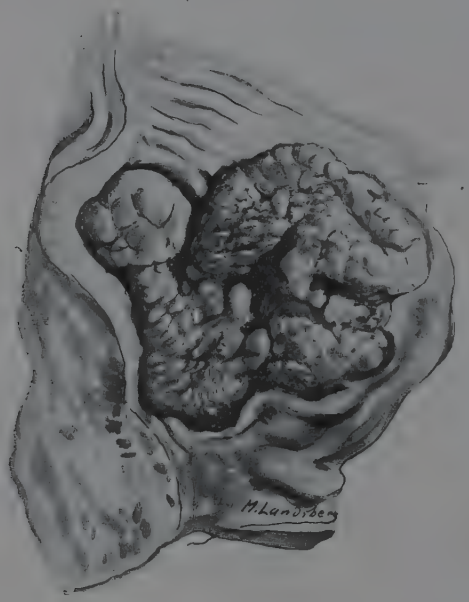

FIG. 48. ADENOCARCINOMA OF THE RECTUM. THE SINUOUS BORDER AT THE LOWER MARGIN OF THE TUMOR MASS IS ALMOST STONY-HARD DUE TO A DENSE FIBROSIS WHICH PROBABLY REPRESENTS AN ATTEMPT TO STAY THE RAPID SPREAD OF THE MALIGNANT PROCESS. SPECIMEN 577.

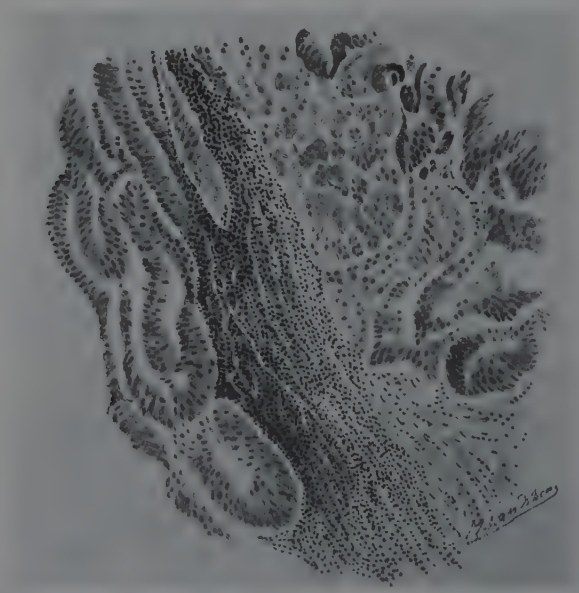

FIG. 49. INTERSPERSED THROUGHOUT A DENSE MASS OF CONNECTIVE TISSUE THERE ARE SEEN SMALL GROUPS OF NEOPLASTIC EPITHELIAL CELLS WHICH MAY TAKE ON AN ALVEOLAR FORMATION. NOTE LYMPHOID INFILTRATION OF CONNECTIVE TISSUE. SPECIMEN 577.

CASE XV. (Record no. 2909, lab. no. 577)

CLINICAL HISTORY

Female, married, aged forty-one years, native of U. S. A.

Family History. Irrelevant.

Duration of Symptoms. Six months.

Onset. Sudden constipation.

Chief Symptoms and Signs. Constipation, bloody stools, dragging sensation in rectum.

Loss of Weight. None.

Physical Examination (relevant). Rectal tumor.

Laboratory Data. Blood picture entirely normal.

Operative Findings. Hard, indurated, ulcerating carcinoma 3 cm. in diameter situated upon the anterior wall of the rectum.

Operative Procedure. Perineal resection of the rectum.

PATHOLOGICAL REPORT

Gross. Specimen submitted consists of rectum, including anus. At a point approximately 1 cm. above the mucocutaneous junction there is seen a rounded beautiful cauliflower-like tumor mass approximately 4.5 cm. in diameter. The tumor is fringed by a neat, thickened sinuous border which is especially prominent at the most dependent part.

Microscopic. Adenocarcinoma.

above described. Clinically the picture may be that of a benign adenoma, in which case only routine microscopic section reveals carcinoma penetrating the deeper layers. Indeed one is occasionally surprised at the extent of penetration and lymph-node involvement with such an apparently benign tumor or early malignancy. The usual slow-growing tumor which has existed for some time is seen as a more or less circular mass about the size of a half dollar with typical reddened, heaped-up or everted, indurated, thick margins and ulcerated crater-like center filled with mucus, perhaps some blood and detritus.

At a more advanced stage there is seen a large fungating, deeply excavated, friable, cauliflower-like mass which penetrates the entire wall and is surrounded by adhesions. Adjacent organs become involved and regional and distal lymph-nodes and liver become infiltrated. Miles describes three methods of extension of rectal carcinoma by direct continuity:

(1) Downward into the wall of the bowel below the growth into the rectal sphincter and ischiorectal fossa.

(2) Lateralward into the fascia propria, levator ani muscles, capsule of the prostate, seminal vesicles and base of the bladder in the male, and the vaginal wall and genital organs in the female.

(3) Upward into the bowel above the growth, pelvic peritoneum and mesocolon.

It is sometimes surprising to note the extent of intestinal-wall involvement without adherence to surrounding structures. Thus Ewing describes a specimen of transverse colon of which fourteen inches was involved with but few adhesions.

Besides extension by direct continuity of tissue, carcinoma of the large intestine advances along the lymphatics. Thus, from the rectum, lymphatic extension reaches the pararectal nodes and those situated along the middle and inferior hemorrhoidal arteries, as well as a node near the origin of the

internal pudic artery. From these nodes efferent vessels may carry the invasion to the preaortic nodes near the origin of the inferior mesenteric artery. From the anus and skin of the perineum extension takes place up the thighs to the inguinal nodes in Scarpa's triangle. Lymphatic extension from the colon is slow and it is rather unusual to find carcinomatous lymph-nodes in the mesocolon or retroperitoneal nodes except in very advanced cases. The tendency of carcinoma of the colon to remain localized to the bowel wall is very pronounced. Many enlarged nodes seen at operation are purely inflammatory in nature. As an instance of the longevity of some patients, Mummery cites a case of a patient who had a colostomy performed for a carcinoma of the rectosigmoidal junction and was still well six years later.

Carcinoma at the ileocecal junction is usually found at the valve but may occur at the junction of the cecum and colon or on the posterior wall. It is usually seen as a large, ulcerating mass which soon obstructs the lumen of the gut. Carcinoma of the transverse colon tends to spread to the stomach wall. Carcinoma of the sigmoid is usually found at the rectosigmoidal junction.

Depending upon the arrangement and character of the cells, predominance of fibrous tissue and the presence of degenerative changes, several varieties of carcinomata of the large intestine have been described. The most frequent type encountered in the large intestine is that known as adenoma destruens. Microscopically, this type of epithelial tumor is seen to consist of orderly giant alveoli and glands with a deficient or absent stroma. The lining columnar cells are hyperplastic and hypertrophic but their polarity is maintained. The nuclei are hyperchromatic. In this form the tumor is infiltrative and produces metastases. The alveolar structure may be maintained even in metastases. Ewing points out the early disappearance of the ducts and membrana propria in adenoma destruens. Uniformly atypical cell forms, nuclear hyperchromatism, abundance of mitoses, reduplication of

Case xvi. (Record no. 2044, lab. no. 312)

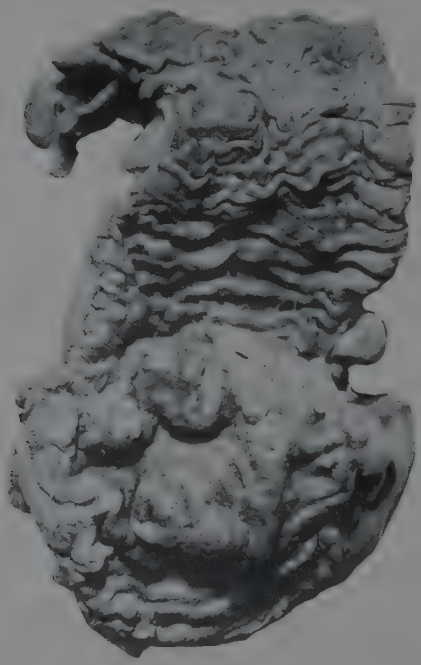

FIG. 50. SCIRRHOUS CARCINOMA OF THE RECTUM. THIS TYPE IS USUALLY SEEN IN ITS EARLY STAGE OF DEVELOPMENT AS A SMALL INDURATED SUPERFICIAL ULCER. MARKED STENOSIS OF THE GUT USUALLY RESULTS FROM THE TENDENCY OF THE NEOPLASTIC PROCESS TO INVOLVE THE GUT WALL IN A CIRCULAR FASHION. SPECIMEN 312.



FIG. 51. NEOPLASTIC CELLS IMBEDDED IN A DENSE MASS OF CONNECTIVE TISSUE. THE SCIRRHOUS TYPE OF CARCINOMA TENDS TO INVADE THE LYMPH-NODES EARLY. SPECIMEN 312.

CASE XVI. (Record no. 2044, lab. no. 312)

CLINICAL HISTORY

Male, aged forty years, native of U. S. A.

Family History. Irrelevant.

Duration of Symptoms. Approximately six months.

Onset. Pain in rectum, thought due to hemorrhoids.

Chief Symptoms and Signs. Pain in rectum, bloody stools.

Loss of Weight. None.

Physical Examination (relevant). Tumor mass in rectum.

Laboratory Data. Piece of tissue snipped from mass shows presence of carcinoma.

Operative Findings. Rectal carcinoma situated 6 cm. from the anus. Enlarged glands in the mesosigmoid.

Operative Procedure. Abdominal proctectomy.

PATHOLOGICAL REPORT

Gross. Specimen consists of a portion of rectum 6.5 cm. in length, received longitudinally incised disclosing an ulcer 4 by 3 cm. in size presenting an indurated base. A small lymph-node accompanies this specimen.

Microscopic. Adenocarcinoma. No evidence of lymph-node involvement.

CASE XVII. (Record no. 3921, lab. no. 963)

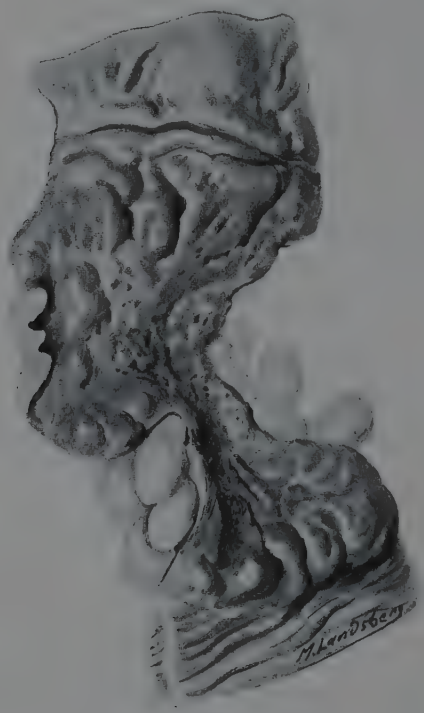

FIG. 52. SCIRRHOUS CARCINOMA AT THE RECTOSIGMOIDAL JUNCTION CAUSING ALMOST COMPLETE CLOSURE OF THE BOWEL LUMEN. SPECIMEN 963.

FIG. 53. BIZARRE EPITHELIAL NEOPLASTIC DEPOSITS MARK THE PROGRESS OF THIS RAPIDLY INVASIVE CARCINOMA. SPECIMEN 963.

CASE XVII. (Record no. 3921, lab. no. 963)

CLINICAL HISTORY

Male, aged forty-two years, native of U. S. A.

Family History. Irrelevant.

Duration of Symptoms. Eight months.

Onset. Pain starting just above symphysis and radiating to rectum.

Chief Symptoms and Signs. Pain as described, occasional "cramps," bloody stools, itching about anus. Frequent desire to defecate but attempt unsuccessful. Tired and worried.

Loss of Weight. About five pounds.

Physical Examination (relevant). Mass in rectum. Hemorrhoids. Tumor located at rectosigmoidal junction on posterior wall possesses crater-like center with friable heaped-up margin. Polyp seen on anterior wall.

Laboratory Data. Wassermann test negative. Blood shows moderate secondary anemia. Urine contains albumin and casts.

Operative Findings. Advanced carcinoma of the rectum approximately 3 cm. in diameter, annular and almost perforated. Liver and mesenteric nodes not involved.

Operative Procedure. Perineal resection of rectum.

PATHOLOGICAL REPORT

Gross. Specimen consists of 30 cm. of large intestine cut open and disclosing a tumor mass, 5 by 10 cm. in size in its largest diameters, irregularly elliptical in shape, the broader portion being situated cephalad. The margins are elevated and hard while the deeper portions are excavated somewhat like a trough, the bottom being filled with greyish yellow debris. Just below the center of the growth there is a distinct narrowing and at this point the margin is evulsed. The lower border reaches to within 5 cm. of what appears to be the beginning of the anus.

Microscopic. Adenocarcinoma.

CASE XVIII. (Record no. 2603, lab. no. 486)

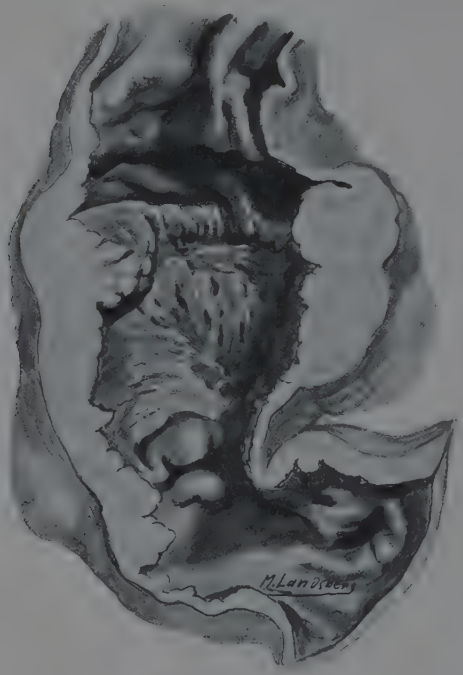

FIG. 54. SCIRRHOUS CARCINOMA ENCIRCLING THE RECTUM. NOTE THE HEAPED-UP MARGINS AND CENTRAL NECROSIS GIVING THE MASS A SOMEWHAT WORMY APPEARANCE. SPECIMEN 486.

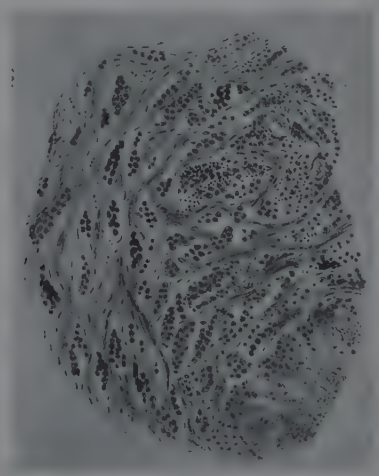

FIG. 55. SMALL NEOPLASTIC EPITHELIAL CELL NESTS SEPARATE THE STRANDS OF DENSE CONNECTIVE TISSUE. LOCAL INVASIVENESS, CELLULAR HYPERTROPHY, HYPERCHROMATISM, ABUNDANCE OF MITOSES, ANAPLASIA, HETEROTOPIA, LOSS OF POLARITY AND DESMOPLASTIC POWER ARE COMMON TO ALL SCIRRHOUS CARCINOMATA. SPECIMEN 486.

CASE XVIII. (Record no. 2603, lab. no. 486)

CLINICAL HISTORY

Male, aged twenty-seven years, native of Spain.

Family History. Irrelevant.

Duration of Symptoms. Three months.

Onset. Sudden constipation.

Chief Symptoms and Signs. Pain in rectum, bloody stools, constipation, dysuria.

Loss of Weight. Ten pounds.

Physical Examination (relevant). Moderate amount of prolapse of anus. Tumor mass approximately 3 cm. from the anus.

Operative Findings. Large carcinomatous mass encircling rectum approximately 2.5 cm. above the prostate. Enlarged paracolic lymph-node.

Operative Procedure. Combined operation for carcinoma of the rectum.

PATHOLOGICAL REPORT

Gross. Specimen consists of the major portion of the rectum presenting at a point 5 cm. above the anus a hard, indurated tumor mass, 2 by 4 cm. in size. The edges are thickened and everted, surrounding a shallow crater-like ulcerated area. Peritoneal coat not invaded.

Microscopic. Adenocarcinoma.

Case xix. (Record no. 3212, path. no. 668)

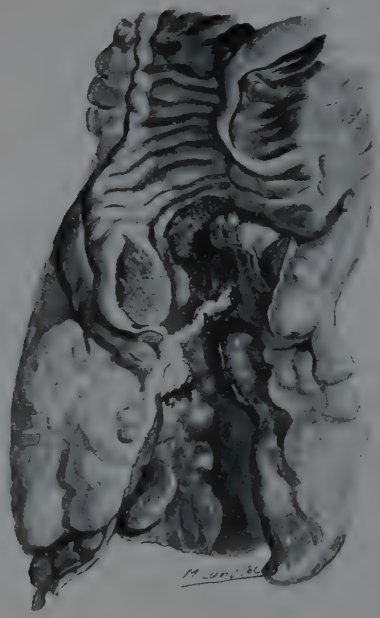

FIG. 56. SCIRRHOUS CARCINOMA AT THE RECTOSIGMOIDAL JUNCTION. BECAUSE OF THE EXTENSIVE INVASION OF THE WALL THIS TUMOR MASS WAS ADHERENT TO ADJOINING LOOPS OF INTESTINE. DIFFICULTY IN OPERATIVE REMOVAL RESULTED IN TEARING OF THE INTESTINAL WALL MOST DEEPLY INFILTRATED. NOTE SINUOUS BORDER INDICATING THE UPPER SUPERFICIAL LIMIT OF THE CARCINOMATOUS PROCESS. THIS DOES NOT USUALLY MARK THE TRUE LIMITS OF THE EPITHELIAL INVASION WHICH MAY HAVE ALREADY SPREAD EVEN AS FAR AS THE PREAORTIC LYMPH-NODES. SPECIMEN 668.

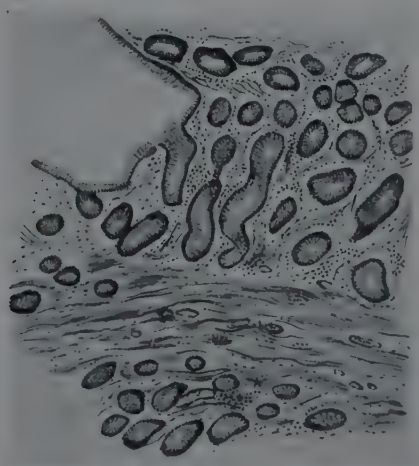

FIG. 57. SMALL GROUPS OF APPARENTLY NORMAL ALVEOLI MAY BE SEEN SCATTERED THROUGHOUT THE CONNECTIVE TISSUE. SPECIMEN 668.

Case xix. (Record no. 3212, path. no. 668)

CLINICAL HISTORY

Male, aged seventy-one years, U. S. A.

Family History. Irrelevant.

Duration of Symptoms. One year.

Onset. Occasional pain in rectum with involuntary discharge of pus and blood.

Chief Symptoms and Signs. None other than above. Bowels very regular.

Loss of Weight. None.

Physical Examination (relevant). Large annular, hard ulcerating mass felt in rectum.

Laboratory Data. Blood chemistry and phenolsulphonephthalein excretion normal. Wassermann test negative. Urine contains albumin and casts.

Operative Findings. Large annular carcinoma at rectosigmoidal junction with some adhesions of the pelvic colon to peritoneum. Enlarged prostate.

Operative Procedure. Combined operation for cancer of the rectum.

PATHOLOGICAL REPORT

Gross. Specimen submitted consists of approximately 12 cm. of rectum, 8 cm. of its lower portion being occupied by an infiltrating, ulcerating, indurated mass. This tumor exhibits at its upper pole a rather sinuous, indurated, elevated margin. In the upper and lower right hand portion of the mass there are seen two bulbous sessile projections each approximately 1 cm. in diameter. The most extensive invasion and ulceration are noted just above the mucocutaneous border. There is a marked hourglass stenosis of the gut at about the center of the tumor mass.

Microscopic. Adenocarcinoma.

lining cells and a promiscuous distribution of glands and stroma are indicative of malignancy. At times the lumina of newly formed tubules may be completely obliterated by the rapid proliferation and encroachment of the lining cells. The muscularis mucosae may be broken through and the process extend laterally as well as more deeply until a large ulcerating nodular or cauliflower area is produced.

While it does not appear advisable to draw any hard and fast lines between adenoma destruens and adenocarcinoma there seem to be certain differential features about the latter type of tumor: The alveolus is imperfectly formed, the lining cells begin to lose their polarity and exhibit markedly atypical cell morphology. There is an extensive cellular overgrowth. Metastases are usually more distinctly adenomatous than the original tumor.

Another type of growth is the scirrhous carcinoma (stenosing fibrocarcinoma), characterized by the presence of a large amount of scar tissue. As first seen it is a small indurated superficial ulcer. Later it tends to involve the entire wall in a circular fashion, producing marked stenosis. Interspersed throughout the dense mass of connective tissue there are seen small groups of neoplastic epithelial cells. The scirrhous type of carcinoma invades the lymph-nodes early and therefore makes surgical removal difficult. In some cases there is a tendency to hyaline swelling of the fibrous tissue which results in a limitation of contraction by the scirrhous carcinoma and may even increase the bulk of the tumor.

The gelatinous adenocarcinoma tends to produce a large bulky mass much of which undergoes gelatinous degeneration. A large area of the intestine may be involved but stenosis is not common and lymphatic invasion is late. The tumor ulcerates early, often converting the gut into a thick rigid tube. It may extend to the peritoneum covering the latter with numerous gelatinous nodules.

From the anal epidermis or the lower rectal mucosa below the point where the transition occurs from columnar to squamous epithelium (upper

ends of the columns of Morgagni) there may occur the typical malignant squamous-celled carcinoma found arising from skin surfaces in other parts of the body. This tumor may first be seen as a superficial hard nodule or as an ulcer involving the skin and anal mucosa. Fissures, ulcers, cicatrices or other areas about the anus subject to chronic irritation may be the seat of malignancy. The origin of cell growth may be found in the squamous cells of the Malpighian layer or in the cells of the sudoriferous or sebaceous glands. As the tumor extends laterally or more deeply there is a tendency towards spontaneous healing in some parts while others are advancing. A variety of histological pictures may be produced. Nests of hornified squamous epithelial cells and concentric formations of flattened cells (epithelial pearls) invade the deeper tissues. Round or giant-cell formations may occasionally be produced. At an early period the regional lymphatics are invaded, eventually leading up the thighs to the inguinal nodes.

In recent years we have encountered several instances of carcinoma associated with diverticulum of the colon. The etiology of diverticula is quite obscure. McGrath[25] believes that the fundamental factors are a weakening of the intestinal wall (congenital, chronic constipation, debilitating disease, senility) and an increased pressure from within. In the small intestine diverticula are likely to be found along the line of the mesenteric attachment where the vessels pierce the bowel wall. In the large intestine they are usually found along the convexity of the gut, usually multiple, and frequently in two rows. One may divide diverticula into the congenital and acquired types. Meckel's diverticulum (above described) is an example of the former. In the complete diverticulum the sac is made up of all the layers of the intestinal wall whereas in the incomplete variety the muscularis is absent, the sac representing a true hernial protrusion through the muscular coat. Most diverticula occur after the age of thirty. In the large intestine they adjoin the appendices epiploicae and vary in size from microscopic

dimensions to several centimeters. The size of the opening into the intestinal lumen varies and the contents of the sac proper may consist of soft or hard fecal material. The diverticula are found with greatest frequency in the sigmoid, a site so favorable for the development of carcinomatous tumors. As a general rule these protrusions of intestinal wall stop abruptly at the rectosigmoidal junction probably because of the additional strength afforded by diffusion of the longitudinal muscular bands over the entire wall. As a result of chronic irritation an inflammatory process is often set up in the wall of the diverticulum. Perforation followed by generalized peritonitis or a local abscess may occur. Wilson has called attention to a low-grade chronic infection of the sac causing a peridiverticulitis or extramucosal inflammation with formation of a mass often simulating carcinoma. In the latter, however, ulceration or involvement of the mucosa is nearly always present in the gross. Carcinomata occurring in diverticula suggest chronic irritation due to the presence of inspissated fecal masses as the probable etiological agent.

A rare tumor of the rectum is that known as a melanoma. This type of carcinoma* is usually quite bulky, causing obstruction of the bowel. Necrosis and ulceration may occur. The black pigment is usually limited to the epithelium and lymph-nodes. In one case described by Kraske the tumor consisted chiefly of large pigmented polyhedral cells. In others, pigmented spindle cells have been described.

The remote results of carcinoma of the colon and rectum are varied. Intestinal obstruction occurs sooner or later in most cases. As long as it is partial, some fecal or fluid material may pass through the lumen while hypertrophy and dilatation of the bowel takes place above it. The obstruc-

*It is not universally accepted that a melanoma is of epithelial origin. This type of tumor will be more fully described under "Melanoma." It is possible that two forms exist: melanotic carcinoma and sarcoma.

tion may suddenly become acute and complete by blockage with fecal material or kinking by a shortened mesentery or adhesions. Intussusception or prolapse may occur; and finally, spontaneous anastomosis between adjoining portions of the invaded bowel. The latter condition is probably preceded by ulceration and perforation of the bowel. A localized peritonitis results, with adhesions to neighboring intestine into which an abscess or invading tumor tissue may perforate. Acute and fatal dilatation of the cecum may occur at a point distant from the site of the actual tumor (e.g., sigmoid).

Chapter IV

CLINICAL ASPECTS OF PRIMARY EPITHELIAL TUMORS OF THE COLON AND RECTUM

Chapter IV

CLINICAL ASPECTS OF PRIMARY EPITHELIAL TUMORS OF THE COLON AND RECTUM

Benign Tumors. Under this heading are included the papillomata and adenomata.

Anal warts occur as minute spots or larger branching excrescences growing from the skin and often spreading out for a considerable distance from the anus. They are always secondary to some chronic irritant, usually coming from the bowel. Ulcerative conditions of the colon or rectum, intestinal parasites, a discharging sinus, chronic vaginal discharge or metabolic conditions giving rise to highly acid stools are some of the etiological factors. It is readily understood that any age or sex may be affected and the associated symptoms and signs are entirely dependent upon the underlying condition. Considerable local irritation and discharge usually accompany the presence of anal warts. The diagnosis is readily made by inspection but care should always be taken to have any removed portions examined for malignancy. The prognosis after removal is excellent providing there is no malignant degeneration and the underlying cause has been removed. Usually there are no postoperative complications as the procedure is simply to snip off the warts and cauterize the bases.

The villous papillomata are usually seen in adults, the youngest of Quénu's[95] fourteen patients being twenty-eight years of age. There seems to be no difference as regards occurrence in either sex. Of doubtful etiology, the tumor makes its presence known by the passage of blood intimately mixed with the stool. There is no predilection for any special part of the colon or rectum. The diagnosis is usually made by sigmoidoscopic observation or, where located higher up, by unexplained bleeding from the bowel. The

prognosis after removal is good provided no malignant change has occurred. The tendency for this type of tumor to become cancerous warrants complete excision of the base. The operative findings depend entirely on the size, location and malignant tendency of the tumor. In passing it might be stated that villous papillomata may be found, as in our case (see Fig. 21), associated with multiple polyposis.

Intestinal polyposis affects both young and old of both sexes. Doering[26] reviewed 52 cases and found the condition to be most common in children. Cripps, Smith and others believe that there is an underlying local, individual and hereditary predisposition. We have long held that the condition of multiple polyposis is due to the active response of the colon and rectum to chronic irritation. The duration of symptoms before medical attention is sought varies greatly, depending chiefly upon the location and rapidity of growth. Mummery's patient noted diarrhea and bleeding eight years before seeking medical attention. Multiple polypi are most frequently found in the rectum. Hauser[42] describes the involvement of the entire mucosa from pylorus to anus. Lubarsch,[65] Niemack[79] and Petrow[88] report lesions in the duodenum, jejunum and ileum. Thorebecke reports 34 cases with the following distribution: 23 in the rectum, 5 in the colon and rectum and 6 in the colon alone. The remarkable specimen in our collection (see Fig. 23)* includes the entire large intestine. There is always a marked tendency towards the development of carcinoma. In fact, it is quite usual to find that one or more of the polyps have undergone malignant change. In the rectum they may be found below a carcinomatous stricture of long duration. Helminthiasis and chronic proctitis may be associated conditions. The onset of multiple polyposis is usually marked by a peculiar catarrhal condition of the bowel. In advanced cases a

* In the arrangement of this monograph it has been deemed expedient to present the individual cases and specimens of the authors apart from the text proper. In this way it is hoped that the subject will be more clearly presented and clinical-pathological illustrations better understood.

severe and intractable diarrhea ensues, accompanied by emaciation and anemia. The stools are liquid and contain considerable mucus and blood, the latter being intimately mixed with the feces. Tenesmus may be present to a troublesome degree. If abdominal pain is present it is usually more severe on the left side. Upon palpation the abdomen may be tender. Intussusception or prolapse may occur or the polypi may slough off and be passed by rectum. The diagnosis may be made by palpation if the masses are located in the rectum, or the sessile and pedunculated tumors may be seen through the sigmoidoscope. There is usually an associated inflammation of the colon and rectum. The course and prognosis of multiple polyposis is very uncertain. Quénu and Landel[95] and Doering[26] state that about half of the cases are associated with carcinoma. Thorebecke[113] states that the high mortality in this disease is due to metastases from polyps that have undergone carcinomatous change and to the disturbance of normal function. Oseki[84] reports metastatic deposits in the retroperitoneal lymph-nodes, liver and other internal viscera.

The treatment of single or multiple adenomatous polyposis depends upon several factors. In cases where there are one or a dozen pedunculated polypi it is a very simple matter to insert the proctoscope and remove them by means of a snare. Plenty of time should be taken as hemorrhage is likely to result if they are removed too rapidly. The thyrotome should always be at hand in case of hemorrhage so that the mucous membrane can be picked up by this instrument and the bleeding points seared with it. This is a most effective means for stopping hemorrhage from any cause in the rectum or sigmoid. The treatment of multiple adenomata is still quite uncertain. Personally, we are of the opinion that if the tumors are beyond the reach of the examining instrument and healthy mucous membrane cannot be reached removal is contraindicated. If the tumors are pedunculated or sessile and all are accessible, they should be removed by means of the snare or cautery.

If inaccessible, some form of local treatment should be applied (tannic acid 1:50, aqueous fluid extract of Krameria 33⅓ per cent solution). Simple measures have often secured surprising results. Thus we reported a case of a young woman who, two years previous to consultation at the St. Bartholomew's Clinic, had had several polypoid adenomata removed at another hospital but refused further operations because of the pain. Examination disclosed the rectum and lower sigmoid studded with polypoid and sessile adenomata varying in size from 2 to 15 mm. The examination also disclosed numerous ulcers of the mucous membrane varying in size from 1 to 12 mm. The remainder of the mucous membrane was granular, bled easily and was covered with mucus, pus and blood. Morning and evening enemata of cold normal salt solution with the occasional addition of 25 per cent aqueous fluid extract of Krameria were advised. At the last observation all ulcerations had disappeared and only one tumor has survived. The establishment of an artificial anus or ileostomy has occasionally given gratifying results.

One or a few sessile or polypoid adenomata may exist in the rectum or colon or both and give few or no symptoms. One condition which is nearly always seen associated with one or more adenomata of the large intestine is that known as pigmentation of the colon (see Fig. 20). Our case occurred in a woman forty-three years of age suffering from obstinate chronic constipation. For three or four years previous to the time of consultation the patient had occasionally passed blood-tinged mucus but had not sought medical aid until five days before admission to St. Bartholomew's Hospital. At that time the patient suffered a severe, acute hemorrhage. Wasting and toxemia were associated symptoms. The colon and rectum appeared to be slate-colored to black with a rather mottled distribution in some places, uniform in others.

The pigment is permanent and microscopically is found to be deposited between the glands of the mucosa. The condition is probably due to old

hemorrhages as the pigment contains iron and is sharply limited by the muscularis mucosae. In the case already described there was a small pigmented adenomatous polyp projecting from the slate-colored mucosa.

Carcinomata of the Colon and Rectum. *Age.* Pennington,[86] in a review of 7174 cases of carcinoma of the rectum, states the age incidence to be as follows:

Age	*Cases*
41 to 50	1442
51 to 60	2072
61 to 70	1783

In other words, about 75 per cent of carcinomata of the rectum occur between the ages of forty-one and seventy. Allingham reports a case of carcinoma of the rectum in a boy thirteen years of age. Other unusual early age incidences are given as follows:

Table 1

UNUSUAL EARLY AGE INCIDENCES OF CARCINOMA OF THE RECTUM

Age, years	*Number of cases*
11	2
12	5
13	2
14	3
15	3
16	2
17	7

Czerny,[23] Stern[107] and Schoning[103] report the occurrence of carcinoma of the rectum in patients between eleven and seventeen years of age.

In 120 operative cases of rectal carcinoma, W. J. Mayo found the average to be fifty-two years.[69] Lynch[67] found that 0.5 per cent of rectal and pelvic colon carcinomata occurred in children under nine, and 2.5 per cent in patients under nineteen years of age. Moreover, 7 per cent of his patients

Case xx. (Record no. 3708, lab. no. 889)



FIG. 58. ADENOCARCINOMA OF THE RECTUM WHICH HAS ALREADY EXTENDED THROUGH THE ENTIRE THICKNESS OF THE INTESTINAL WALL. THE TUMOR MASS HAS BEEN PARTIALLY TORN DURING OPERATIVE REMOVAL. SPECIMEN 889.

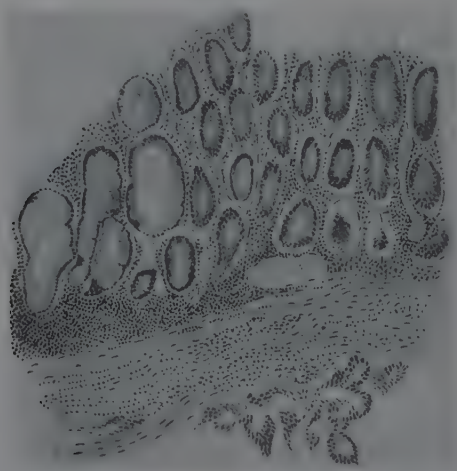

FIG. 59. INVASION OF THE MUSCULARIS BY GROUPS OF SQUAMOUS-LIKE EPITHELIAL CELL GROUPS. SPECIMEN 889.

CASE XX. (Record no. 3708, lab. no. 889)

CLINICAL HISTORY

Male, married, aged fifty-six years, native of U. S. A.

Family History. Irrelevant.

Duration of Symptoms. Two to three years.

Onset. Pain in back ("lumbago") two or three years ago. Six months ago noticed blood in stools.

Chief Symptoms and Signs. Persistent melena, frequency with passage of only gas and blood. No pain.

Loss of Weight. None.

Physical Examination. Carcinomatous growth on lateral rectal wall just above anus.

Laboratory Data. Urine: albumin trace, occasional hyaline and granular casts. Blood chemistry normal (glucose 0.090 per cent, urea nitrogen 0.0176 per cent, nonprotein nitrogen 0.0294 per cent, creatinine 0.0009 per cent, uric acid 0.0021 per cent). Phenolsulphonephthalein excretion 56 per cent in two hours.

Operative Findings. Tumor mass on left lateral wall of rectum running obliquely upwards and to the right. Size approximately 3 cm. Location approximately 2 cm. above anus.

Operative Procedure. Perineal excision of rectum.

PATHOLOGICAL REPORT

Gross. Specimen consists of a portion of rectum approximately 14 cm. in length, exhibiting in the lower portion an irregularly oval indurated and ulcerated mass 3.5 by 2.5 cm. in size with raised thickened margin. Upon section of the wall the neoplastic process seems to have penetrated through all coats of the rectum.

Microscopic. Adenocarcinoma.

were under thirty and 9 per cent between thirty and thirty-five years of age. The age distribution of Lynch's 491 cases is as follows:

Age, years	*Number of cases*
Under 20	4
20–30	32
30–40	66
40–50	117
50–60	136
60–70	91
70–80	21
Over 80	7
Not stated	17
	491

Cripps[21] found the following decade incidence of rectal carcinoma (series of 371 cases):

Age, years	*Number of cases*
20–30	3
30–40	21
40–50	78
50–60	93
60–70	119
70–80	53
Over 80	4
	371

It will be seen that Lynch's and Cripps' figures tally very closely, 70 per cent occurring between the ages of forty and seventy in the former and 76 per cent in the latter. Oehler's[82] series of 230 patients afflicted with carcinoma of the rectum is distributed as follows:

Age, years	Male	Female	Total
10–19	1	1	2
20–29	3	0	3
30–39	10	3	13
40–49	20	17	37
50–59	51	30	81
60–69	47	20	67
70–79	18	6	24
80–89	3	0	3

Carcinoma of the pelvic colon may be encountered at a very early age. Philipp[90] cites its occurrence in a girl of twelve and boys of nine, fourteen and fifteen (2) years. Louart[64] found 61 cases of carcinoma of the large intestine occurring between the ages of twenty and thirty. Other examples of early age of incidence are given by Nothnagel[80] (in the cecum at twelve years), Garrard[35] (in the sigmoid at twelve years) and Clar[19] (in the colon at three years). Bernouille[6] found 29 cases of carcinomata of the rectum and sigmoid in patients under twenty. Phifer[89] found records of 49 cases of carcinoma of the rectum or sigmoid in young people distributed as follows:

Age, years	*Case*
Under 1	1
6–10	1
11–15	22
16–20	25
	49

The average age of incidence of carcinoma of the pelvic colon is given as fifty-two to fifty-three years by Pennington.

To summarize the above statistics it may be stated that carcinoma of the rectum or colon occurs at any age, but the majority may be grouped between forty and seventy years for tumors of the rectum, about fifty for the pelvic colon and a considerably earlier age for the remainder of the large intestine.

TABLE II

COMBINED TABLE SHOWING AGE DISTRIBUTION FOR CARCINOMA OF THE RECTUM

Author	No. of cases*	Age, years								Male	Female
		Under 20	20–30	30–40	40–50	50–60	60–70	70–80	Over 80		
Lynch[67]	491	4	32	66	117	136	91	21	7		
Pennington[86]	7,174	..	..	..	1,442	2,072	1,783				
Cripps[21]	379	..	3	21	78	93	119	53	4		
Oehler[82]	230	2	3	13	37	81	67	24	3	153	77
Zinner[26]	201	..	6	24	50	76	38	6	1	129	72

* These figures include some patients with ages unknown.

Case xxi. (Record no. 2923, lab. no. 591)

FIG. 60. SCIRRHOUS CARCINOMA OF THE RECTUM CIRCUMSCRIBING THE WALL. THE LATTER IS INVADED TO AND INCLUDING THE PERITONEAL COAT. THERE IS MARKED STENOSIS OF THE RECTUM DUE MORE TO THE CONTRACTING FIBROUS TISSUE THAN ACTUAL TUMOR BULK PROJECTING ABOVE THE MUCOUS MEMBRANE. SPECIMEN 591.

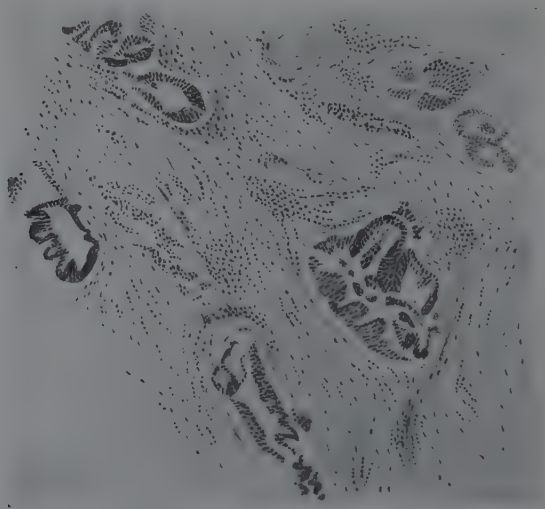

FIG. 61. ATYPICAL ALVEOLI DISTRIBUTED HERE AND THERE IN THE NEWLY FORMED CELLULAR CONNECTIVE TISSUE. SPECIMEN 591.

CASE XXI. (Record no. 2923, lab. no. 591)

CLINICAL HISTORY

Female, single, aged fifty-six years, native of U. S. A.

Family History. One sister died of carcinoma of the "stomach."

Duration of Symptoms. One year.

Onset. "Caught cold" in the right side and back. Stomach "upset."

Chief Symptoms and Signs. Gaseous eructations and frequent passage of flatus. Occasional diarrhea.

Loss of Weight. Thirty pounds within a few months before admission.

Physical Examination (relevant). Located on the anterior rectal wall is a rough, irregular mass with crater-like, punched-out center. The tumor is freely movable.

Laboratory Data. Wassermann test negative. Urine shows trace of albumin and casts. Blood count indicative of a mild secondary anemia. Fractional gastric analysis reveals absence of free hydrochloric acid with a total acidity of 10 during a period of 2 hours. No lactic acid present. *X*-ray of gastrointestinal tract shows the presence of a filling defect at or near the rectosigmoidal junction.

Operative Findings. Carcinoma at rectosigmoidal junction. Gut bound down by extensive adhesions. Extensive lymphatic involvement.

Operative Procedure. Resection of sigmoid and part of rectum. Artificial stoma.

PATHOLOGICAL REPORT

Gross. Specimen consists of approximately 15 cm. of large intestine presenting a hard, fungating mass 5 cm. in length in its longest diameter, circumscribing the gut wall and causing marked stenosis of the lumen. There appears to be a deep invasion of the intestinal wall down to the peritoneal coat so that as much of the tumor mass is in the wall proper as projects from the surface.

Microscopic. Adenocarcinoma.

CASE XXII. (Record no. 2957, lab. no. 602)



FIG. 62. ADENOCARCINOMA OF THE RECTUM RESEMBLING THE SCIRRHOUS TYPE SHOWN IN FIGURE 49. SPECIMEN 602.

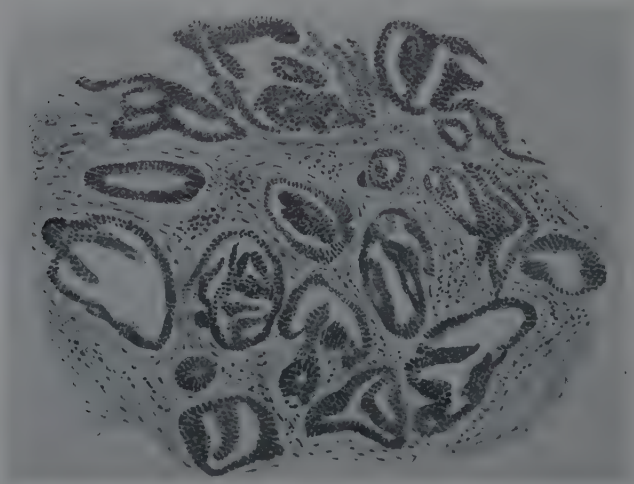

FIG. 63. TYPICAL FIELD ILLUSTRATING THE PREDOMINATING ATYPICAL GLANDULAR TISSUE INVASION. NOTE ALMOST COMPLETE OBLITERATION OF LUMINA OF SOME TUBULES BY RAPID PROLIFERATION OF THE LINING CELLS. SPECIMEN 602.

Case XXII. (Record no. 2957, lab. no. 602)

CLINICAL HISTORY

Male, aged fifty-nine years, native of U. S. A.

Family History. Mother died of breast carcinoma.

Duration of Symptoms. Three weeks.

Onset. Dull aching pain in left upper abdomen.

Chief Symptoms and Signs. As described. Occasional sharp, agonizing pain in same region.

Loss of Weight. None.

Physical Examination (relevant). Tumor located in splenic flexure.

Laboratory Data. Urine contains albumin and casts. Stool examination positive for occult blood. Widal negative. Blood chemistry normal. Blood count and morphology normal except for persistent leucocytosis varying between 14,000 and 18,000 per c. mm. Cystoscopic examination negative. *X*-ray examination reveals an obstruction with a filling defect just below the splenic flexure.

Operative Findings. Large carcinoma of the splenic flexure.

Operative Procedure. Resection of the splenic flexure.

PATHOLOGICAL REPORT

Gross. Specimen submitted consists of approximately 20 cm. of colon exhibiting a large indurated deeply excavated tumor mass upon its mucous surface. The floor is covered with friable yellowish debris and is apparently formed by muscularis. There is an irregular nodular margin. Apparently deep invasion into the extramural fatty tissue has already taken place.

Microscopic. Adenocarcinoma.

Sex. The incidence is about the same in either sex with a tendency toward slight predominance in males.[77,6] In Oehler's[82] series of 179 cases undergoing radical operation for carcinoma of the rectum, 120 were males and 59 females.

Etiology. While it is impossible to state all of the factors involved in the production of carcinomata of the large intestine, certain predisposing and exciting conditions seem to be of clinical significance. These factors are:

(1) Existence of chronic inflammatory conditions (old chronic ulcer of the rectum, opening of a long-standing fistula, simple stricture).

(2) Pre-existing benign tumor. The tendency for the simple papilloma or the condition known as multiple polyposis to undergo malignant transformation has been described. Ewing terms this tendency a "tissue predisposition," assuming a previously existing abnormality of structure.

(3) Trauma. Several authors (Goeckel,[36] Körte,[54] Anschutz[1]) have reported cases of rectal carcinoma due to trauma.

(4) Anatomical conditions. The fixed parts of the large intestine most subject to irritation are the cecum, flexures and rectal valves.

(5) Developmental anomalies. These are most likely to occur where there are changes in the structure of the wall of the gut (appendix, ileocecal valve, rectal folds, anus). Kraske[56] found no evidence of embryonal rests as a factor in the causation of rectal carcinoma.

Duration of Symptoms. In 491 cases of rectal carcinoma Lynch finds the duration of symptoms to average eight months. Tuttle[117] compiled an interesting table giving the duration of symptoms before operation and postoperative results (100 cases):

TABLE III

DURATION OF SYMPTOMS AND OPERATIVE RESULTS IN 100 CASES OF RECTAL CARCINOMA (TUTTLE)

Duration of symptoms before operations	Recoveries	Deaths	Recurrences	Mortality
Under three months	14	3	5	21.4 per cent
Three to six months	15	1	3	6.6 per cent
Six to nine months	7	1	2	14.3 per cent
Nine to twelve months	13	2	5	15.4 per cent
Over twelve months	36	8	5	22.2 per cent

It is interesting to note that although most of the cases showed symptoms for more than twelve months before operation the mortality is about the same as in the earlier cases (under three months). This is rather unusual, in our experience, for the average run of patients.

Site and Extent of the Tumor Mass. In a report of 1670 cases of rectal carcinoma Pennington[86] states that 1250 (74 per cent) were located in the ampulla and 178 (11 per cent) in the anal canal. In Lynch's 491 rectal cases, 69 per cent of the tumors were within four inches of the anus. Of 100 cases of anorectal carcinoma Gant[34] finds the following distribution:

Location	*Cases*
Anus	5 per cent
Ampulla	50 per cent
Upper rectum	20 per cent
Upper rectum and sigmoid	15 per cent
Anal canal	10 per cent

Tuttle groups rectal carcinomata as follows:

Anus	6.7 per cent
Infraperitoneal	26.3 per cent
Supraperitoneal	67.0 per cent

Mummery believes that the most common site is the rectosigmoidal junction, then the rectal ampulla, and least common the anus. Edwards asserts that about 80 per cent of rectal carcinomata occur 5 to 7.5 cm. from the anus.

CASE XXIII. (Record no. 2610, lab. no. 490)

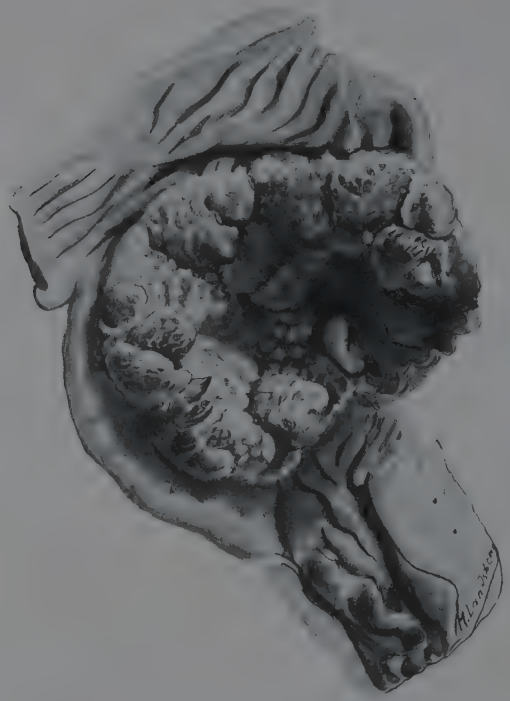

FIG. 64. LARGE BULKY ADENOCARCINOMA OF THE RECTUM EXHIBITING EXTENSIVE SURFACE ULCERATION DUE TO CHOKING-OFF OF THE BLOOD SUPPLY. SPECIMEN 490.

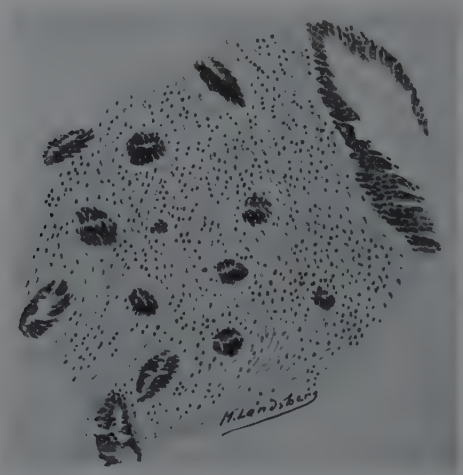

FIG. 65. AN UNUSUAL AMOUNT OF CONNECTIVE TISSUE IS PRESENT FOR THIS SLOWLY GROWING BULKY TYPE OF ADENOCARCINOMA. SPECIMEN 490.

Case xxiii. (Record no. 2610, lab. no. 490)

CLINICAL HISTORY

Female, widow, aged sixty years, native of U. S. A.

Family History. Irrelevant.

Duration of Symptoms. Three years.

Onset. Bloody stool.

Chief Symptoms and Signs. Bloody stools, belching, abdominal pain, obstinate constipation, feeling of fullness in the rectum with frequent desire to go to stool. Occasional localized pain in the rectum.

Loss of Weight. None.

Physical Examination (relevant). Large irregular mass in the rectum about 5 cm. above the anus. The entire rectum appears to be adherent to the sacrum.

Operative Findings. Nonadherent tumor mass in the rectum.

Operative Procedure. Combined operation for carcinoma of the rectum.

PATHOLOGICAL REPORT

Gross. Specimen submitted consists of 15 cm. of large intestine including the anus. At a point 5 cm. above the mucocutaneous junction there is seen an irregularly oval, nodular protuberance projecting from the mucosa and circumscribing the gut lumen. Size of tumor mass 6 by 10 cm. with larger diameter in transverse diameter of the intestine. Nodular excrescences at the margin overhang normal mucosa. Marked obstruction is present.

Microscopic. Adenocarcinoma.

W. J. Mayo[74] in 100 consecutive cases found 63 per cent in the rectosigmoid, 30 per cent in the rectum and 7 per cent in the anal canal. Kaufman states that 60 per cent of intestinal carcinomata and 5.25 per cent of all carcinomata occur in the rectum.

The distribution of carcinomata of the large intestine may be concisely summarized in the following table[30]:

TABLE IV

DISTRIBUTION OF CARCINOMATA OF THE LARGE INTESTINE

Author or Institution	No. of cases	Colon									Remarks
		Appendix	Cecum	Ascend.	Hep. Fl.	Trans.	Spl. Fl.	Desc.	Sig.	Rectum	
Brill	3563 intestinal tumors	....	..	....	..	..	..	..	...	...	97.5 per cent in appendix, colon, rectum
Schlieps[102]	542 intestinal carcinomata	....	259 located in colon					..	...	257	
Kaufman	123 intestinal carcinomata	....	36 located in colon					..	28	51	
Körte, Peterman, Anschutz.	297 colon carcinomata	....	47	22	19	44	31	10	124		
Pathologic Institute of Vienna.	343 intestinal carcinomata	....	164 located in colon					..	...	162	

As regards the location upon the rectal wall, Pennington[86] makes the following classification:

Site	*Cases*
Anterior wall	487
Posterior wall	250
Lateral wall	87
	824

Cole[20] finds the anterior and lateral walls as the favorite sites while Rawling finds the posterior wall most often affected and Oehler[82] the anterior just as frequently as the posterior wall. To summarize the location of rectal carcinoma it would be quite in accord with the facts to state that the tumor

mass is most likely to be located on the anterior wall, high up in the rectum above the peritoneal reflection but within reach of the examining finger.

As regards the remaining portion of the large intestine, carcinoma is found most frequently at the sigmoid flexure, then in the cecum and ascending colon, and least often in the transverse colon and splenic flexure (not entirely in agreement with figures of Körte, Peterman and Anschutz). The dependent parts are most commonly involved. As Nothnagel has pointed out, carcinoma is most likely to occur in regions where we find stercoral ulcers—the result of stasis and irritation. In this connection it is interesting to note that many authors have reported carcinomata growing simultaneously in two or more parts of the large intestine.

Symptoms and Signs. The early symptoms of carcinoma of the large intestine are very obscure and depend largely upon the situation and ulceration of the growth. In our experience the earliest symptoms of rectal carcinoma are the sudden onset of constipation and unexplained weakness. There may be a vague sense of discomfort in the rectum and a feeling that the bowels have been incompletely emptied. Diarrhea, or diarrhea alternating with constipation, may be an early and prominent symptom. Boas[8] lays emphasis upon colic as an early complaint. It is usually accompanied by tenesmus and passing of blood from the bowels. There may be either constipation or diarrhea. An elderly patient complaining of sudden diarrhea or constipation without any apparent cause should always receive a thorough examination of the lower intestinal tract. The diarrhea, if present, is of a rather unusual type. Sometimes it occurs only upon arising in the morning. The stools may be frequent but each time consist only of a little mucoid or watery discharge. Some fecal material and liquid blood may be in the admixture. This type of diarrhea has very aptly been termed "spurious" because of the fact that it is often found upon examination that very little real fecal material has been passed, the major portion accumulating above the tumor

mass. The passage of mucous and fluid blood intimately mixed with the stool is seen sooner or later in every case. In several of our cases there occurred a sudden profuse hemorrhage. With lesions of the colon, pain is likely to be an early symptom, either diffusely scattered over the abdomen or in the sacrum. There are likely to be attacks of colic. Distention and a constant dull dragging pain are of frequent occurrence. In cases of advanced carcinoma of the cecum, the pain may be related to meals, occurring several hours after the ingestion of food. In the pelvic colon the pain may be related to defecation. Carcinoma in the anal region is often accompanied by early, severe, often excruciating pain. In advanced carcinoma located in any part of the colon or rectum, obstructive symptoms become prominent. The patient may complain of difficulty in moving the fecal column past the tumor mass. Acute obstruction is very prone to occur in the sigmoid where the well-developed musculature is likely to be thrown into a spasm. Reflex pains down the thighs or referred to neighboring organs may be noted. With breaking down of the tumor mass a foul irritating discharge may excoriate the skin about the anal margin, often causing pruritus, abscesses or fistulae. Fecal impaction, cachexia, anemia, loss of weight, complete obstruction, edema of the legs and peritonitis are all late symptoms. The so-called pipe-stem feces are only seen in tumors of the anus, where the fecal mass acquires its final shape.

Diagnosis. With the above indefinite and rather vague symptom complex in mind, one can appreciate the significance of such figures as those given by surgeons in this field. Thus, Mummery[77] states that three-quarters of the cases of rectal carcinoma coming to St. Mark's Hospital (England) are already too far advanced for removal. Tuttle and Lynch found 153 out of 491 cases inoperable. Lusk[66] quotes Baish that in a selected series of cases one-third of the patients thought operable already had microscopic involvement of the lymph-nodes. The importance of early diagnosis and

CASE XXIV. (Record no. 3435, lab. no. 777)

FIG. 66. ADENOCARCINOMA AT THE RECTOSIGMOIDAL JUNCTION, EXHIBITING THE USUAL CENTRAL ULCERATION AND HEAPED-UP EVERTED MARGIN. SPECIMEN 777.

FIG. 67. OPERATIVE FIELD. VIEW OF TUMOR AREA, SHOWING TENDENCY OF STROMA OF INVADED TISSUE TO CONTRACT AND PULL UPON HEALTHY UNINVOLVED TISSUE, PRODUCING PUCKERING OF THE PERITONEUM. SPECIMEN 777.

(For Fig. 68, Case XXIV, see second page following.)

Case xxiv. (Record no. 3435, lab. no. 777)

CLINICAL HISTORY

Female, married, aged sixty-five years, native of U. S. A.

Family History. Irrelevant.

Duration of Symptoms. One year.

Onset. Bloody stool.

Chief Symptoms and Signs. Chronic constipation. Bloody stools containing mucus and expelled with large amount of gas. Pain below umbilicus relieved by bowel movement.

Remarks. Pulmonary hemorrhage three years ago.

Loss of Weight. None.

Physical Examination (relevant). Small tumor mass in sigmoid palpated through vagina.

Laboratory Data. Urine contains albumin and casts.

Operative Findings. Carcinoma located at the rectosigmoidal junction.

Operative Procedure. Resection of lower end of sigmoid and part of rectum.

PATHOLOGICAL REPORT

Gross. Specimen consists of a portion of large intestine 14 cm. in length, exhibiting near one end what appears to be an oval ulcerated area 6 by 4 cm. in size, having raised indurated margins.

Microscopic. Adenocarcinoma.



FIG. 68. LARGE DISTORTED TUBULES WITH ATYPICAL CELL PROLIFERATION. NOTE PENETRATION OF THE MEMBRANA PROPRIA AND MULTIPLICATION OF EPITHELIAL LINING CELLS. SPECIMEN 777.

careful scrutiny of intestinal symptoms at any age can scarcely be overestimated. Only too often have hemorrhoids been removed without careful examination of the rectum to determine a possible underlying cause. Pennington[87] quotes Jones as estimating that the mistaken diagnosis of hemorrhoids where carcinoma actually exists is made in 75 per cent of the cases. Periodic rectal examination should be made of all patients complaining of constipation.

Abdominal palpation will in most early or moderately advanced cases reveal no information. In most cases when a tumor mass is felt through the abdomen (carcinoma of the colon) the neoplasm has advanced too far to make this method of diagnosis of any value.

Rectal examination is of great value, as most of the carcinomata in this region are within reach of the examining finger. The bowel should be emptied by the administration of castor oil at night followed by a saline cathartic in the morning. Sometimes a growth just beyond the reach of the examining finger may be satisfactorily palpated by means of a bimanual examination (one hand on the abdomen and index finger of the other hand in the rectum). The typical crater-like mass with the heaped-up, smooth or nodular, indurated thick margins may be readily felt. Pedunculated polyps, cauliflower-like masses, small nodules, or pararectal infiltration can be detected by the sensitive finger.

By far the best method of examination is the ocular, by means of the electric sigmoidoscope. If carefully and gently passed, there is very little danger of perforation of the diseased bowel. The patient, properly prepared by catharsis and enemata, is placed in the knee-chest position. The outside of the instrument is slightly warmed by passing it through a flame, and lubricated. Vaseline is applied to the anus and the instrument gently inserted for about 10 cm. toward the sacrum. The obturator is then removed and the illuminating device inserted. The instrument is gently pressed through the bowel lumen using air inflation if necessary. After reaching the sacral prom-

CASE XXV. (Record no. 3901, lab. no. 999)

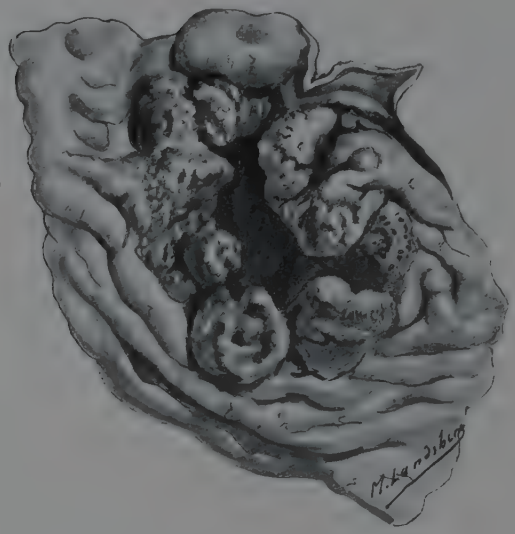

FIG. 69. LARGE ULCERATED ADENOCARCINOMA OF THE RECTUM WITH CENTRAL DEPRESSED CICATRICIAL AREA. SPECIMEN 999.

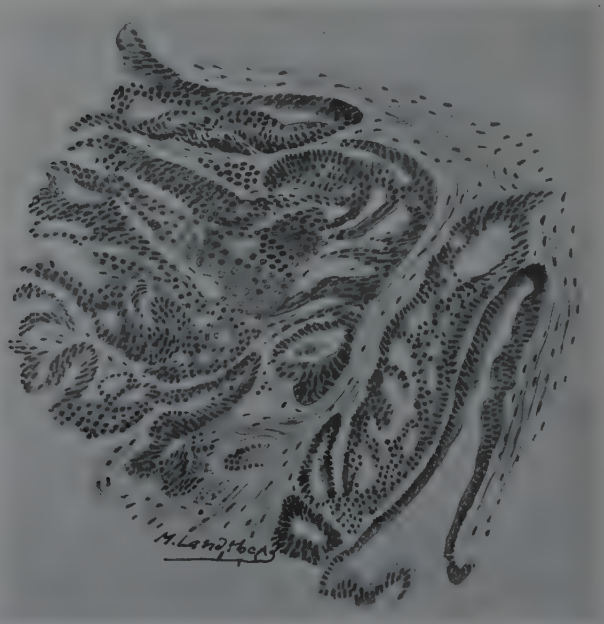

FIG. 70. EXTENSIVE INVASION OF THE MUSCULARIS BY ATYPICAL NEOPLASTIC EPITHELIAL CELLS. NOTE UNUSUAL CELL MORPHOLOGY AND IMPERFECTLY FORMED ALVEOLI. THE GENERAL CONTOUR OF THE NEOPLASTIC DEPOSITS WHICH RUN MORE OR LESS PARALLEL WITH THE DIRECTION OF THE MUSCLE FIBERS SUGGEST A POSSIBLE MODE OF DISSEMINATION BY CONTRACTION OF THE LATTER. SPECIMEN 999.

CASE XXV. (Record no. 3901, lab. no. 999)

CLINICAL HISTORY

Male, married, aged fifty-seven years, nativity not known.

Family History. Irrelevant.

Duration of Symptoms. Seven months.

Onset. Recurrence of piles not relieved by medication (had had similar condition ten and five years previous but each time was relieved by medication).

Chief Symptoms and Signs. Pain in rectum especially at stool, constipation, frequency, lassitude.

Loss of Weight. Six pounds.

Physical Examination. Tumor mass on the posterior wall of the rectum approximately 5 cm. above the nucocutaneous margin with the long diameter in the axis of the gut. Tumor approximately 2 by 3 cm. in size, possessing an indurated margin and crater-like center.

Laboratory Data. Urine contains faint trace of albumin, occasional hyaline casts and some pus.

Blood chemistry normal (glucose 0.100 per cent, urea nitrogen 0.0178 per cent, nonprotein nitrogen 0.0285 per cent, creatinine 0.0015 per cent, uric acid 0.0012 per cent). Wassermann test negative.

Blood count: Hemoglobin 75 per cent, erythrocytes 5,180,000 per c.mm., leucocytes 12,200 per c.mm., polymorphonuclear neutrophiles 79 per cent, small lymphocytes 18 per cent, large lymphocytes 2 per cent, large mononuclear 1 per cent (Aug. 14, 1924). Phenolsulphonephthalein excretion 59 per cent in two hours.

Operative Findings. Large carcinomatous tumor on the posterior rectal wall. Rectum not adherent to surrounding structures.

Operative Procedure. Perineal resection of rectum.

Remarks. Colostomy, August 19, 1924; resection, October 22, 1924.

	Hemoglobin	R. B. C.	W. B. C.	P. N.	S. L.	L. L.	L. M.
Oct. 20.....	80	4,200,000	8,800	65	33	2	
Nov. 26.....	70	3,600,000	5,200	78	18	2	2

Transfusion (800 c.c.) on October 21, one day preceding resection, and again (500 c.c.) on November 24. Compare with count of August 14. Note persistent anemia in spite of transfusions.

PATHOLOGICAL REPORT

Gross. Specimen consists of rectum 12 by 8 cm. in size exhibiting a deeply ulcerated oval area 2.5 by 2 cm. in size, with smooth floor, and surrounded by a friable, heaped-up, sinuous border which blends imperceptibly with the adjacent mucosa. The widest diameters of the tumor mass are 6 by 5 cm. The tumor mass has been entirely circumscribed in removal. The neoplastic process does not penetrate the rectal wall so that the muscular tissue covering the peritoneal surface does not appear to be invaded.

Microscopic. Adenocarcinoma.

inence the end of the tube is manipulated forward in order to follow the natural curvature of the gut. At the rectosigmoidal junction the end of the instrument may become impinged upon a normal fold of mucosa generally

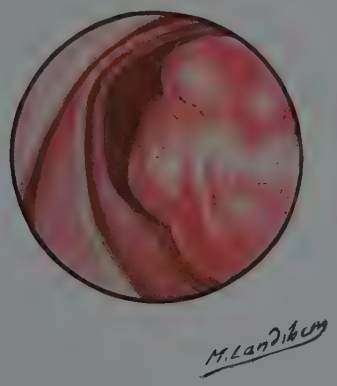

FIG. 71. CARCINOMA OF THE SIGMOID (SIGMOIDOSCOPIC VIEW).

found at this point. The sigmoid generally curves to the left, but being movable is finally slipped over the straight sigmoidoscope after some manipula-



FIG. 72.

FIG. 73.

FIG. 72. SIMPLE POLYP OF THE RECTUM (PROCTOSCOPIC VIEW).
FIG. 73. ADENOMATOUS POLYPS OF THE RECTUM (PROCTOSCOPIC VIEW).

tion. The various pictures encountered depend upon the location, size and duration of the tumor mass and associated conditions. There may be seen the excavated, ulcerative lesion with smooth, thick, everted, red, angry-

CASE XXVI. (Record no. 904, lab. no. 878½)

FIG. 74. ADENOCARCINOMA OF THE RECTUM. NOTE THE SMOOTH FLOOR FORMED BY MUSCULARIS. THE BLOOD SUPPLY TO THE OVERLYING MUCOSA HAS BEEN CHOKED OFF, RESULTING IN NECROSIS AND SLOUGHING OF THE AFFECTED TISSUE. SPECIMEN 878½.

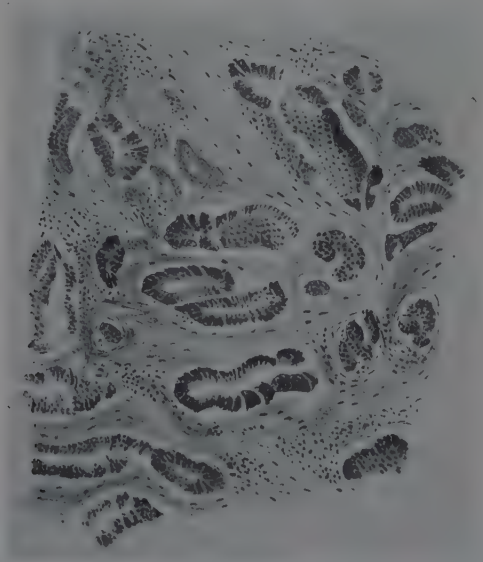

FIG. 75. NOTE THE EXTENSIVE INVASION OF BLOOD VESSELS AND LYMPHATICS BY NEOPLASTIC EPITHELIAL CELLS. SPECIMEN 878½.

CASE XXVI. (Record no. 904, lab. no. 878½)

CLINICAL HISTORY

Female, single, aged fifty-four years, native of Ireland.

Family History. Irrelevant.

Duration of Symptoms. Twenty months.

Onset. Sudden diarrhea accompanied by pain in the left lower quadrant of abdomen, and bloody stools.

Chief Symptoms and Signs. Periodic attacks of diarrhea although previously suffering from chronic constipation, pain in left lower quadrant of abdomen, anorexia, weakness, melena.

Loss of Weight. Some.

Physical Examination. Large mass in rectum.

Laboratory Data. Blood: Hemoglobin 70 per cent, erythrocytes 4,160,000 per c.mm., leucocytes 8,000 per c.mm., polymorphoneuclear neutrophiles 62 per cent, small lymphocytes 32 per cent, large lymphocytes 4 per cent. Urine: contains trace of albumin and occasional hyaline and granular cast. Phenolsulphonephthalein excretion 79 per cent in two hours.

Operative Findings. Sigmoid greatly distended. Carcinomatous tumor in rectum.

Operative Procedure. Preliminary colostomy followed by abdominal resection of the rectum.

PATHOLOGICAL REPORT

Gross. Specimen consists of approximately 15 cm. of large intestine, including rectum and anus, exhibiting a large oval tumor mass 4 by 4 cm. in size, whose lower margin reaches a point 1 cm. above the mucocutaneous junction. The tumor edge is raised, indurated, sinuous, and seems to overhang the surrounding tissue. The central portion is the seat of a deeply excavated ulcer cavity.

Microscopic. Adenocarcinoma.

CASE XXVII. (Record no. 3151, lab. no. 652)

FIG. 76. LARGE, RELATIVELY SUPERFICIAL, ADENOCARCINOMA OF THE RECTUM. THIS SPECIMEN IS ILLUSTRATIVE OF THE FACT THAT FOR A LONG TIME A CARCINOMATOUS PROCESS IN THE RECTUM MAY BE LIMITED BY THE SUBMUCOSAL LYMPHATIC PLEXUS, EXTENDING IN THIS LAYER AND EVEN SENDING OFFSHOOTS UP INTO THE MUCOSA AT POINTS QUITE DISTANT FROM THE PLACE OF ORIGIN. SPECIMEN 652.

FIG. 77. INVASION OF THE CIRCULAR MUSCULAR COAT HAS ALREADY TAKEN PLACE. IT MUST BE REMEMBERED THAT AT ANY TIME AFTER REACHING THE SUBMUCOSAL PLEXUS THE CARCINOMATOUS PROCESS MAY EXTEND THROUGH THE RADIAL MUSCULAR LYMPHATICS TO REACH THE CIRCULAR INTERMUSCULAR AND THE SUBSEROUS PLEXUSES. SPECIMEN 652.

Case xxvii. (Record no. 3151, lab. no. 652)

CLINICAL HISTORY

Male, aged sixty-two years, native of U. S. A.

Family History. Irrelevant.

Duration of Symptoms. Three months.

Onset. Bloody stools.

Chief Symptoms and Signs. Bloody stools. Otherwise well.

Loss of Weight. Eight pounds.

Physical Examination (relevant). Tumor mass high up in rectum.

Laboratory Data. Blood chemistry and blood count normal. Urine contains albumin and casts.

Operative Findings. Large carcinomatous mass near the rectosigmoidal junction 3.5 cm. in diameter.

Operative Procedure. Combined operation for resection of rectum.

PATHOLOGICAL REPORT

Gross. Specimen submitted consists of approximately 20 cm. of large intestine exhibiting a large rounded excavated ulcer approximately 5 cm. in diameter and located about 8 cm. above the mucocutaneous border. The margins are raised and indurated. Near one end of the specimen there is seen a large oval thrombosed hemorrhoid.

This process seems to have spread very superficially as there appears to be no deep invasion visible in the gross.

Microscopic. Adenocarcinoma.

CASE XXVIII. (Lab. no. 534)

FIG. 78. ADENOCARCINOMA OF THE RECTUM. IT IS SURPRISING HOW LITTLE ULCERATION IS PRESENT IN VIEW OF THE BULK OF THE TUMOR MASS. SPECIMEN 534.

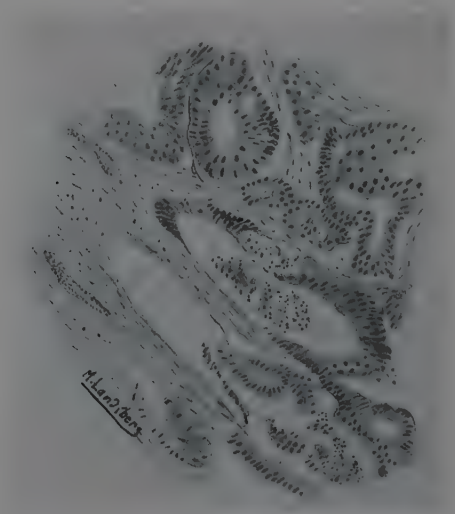

FIG. 79. NOTE THE ATYPICAL CELL MORPHOLOGY AND CELLULAR OVERGROWTH. THE VASCULAR SUPPLY IS APPARENTLY QUITE WELL PRESERVED. SPECIMEN 534.

CASE XXVIII. (Lab. no. 534)

CLINICAL HISTORY

Male, married, aged forty-six years, nativity not known.

Family History. Irrelevant.

Duration of Symptoms. Eight months.

Onset. Sudden cramps in the left lower quadrant of abdomen accompanied by constipation lasting two days.

Chief Symptoms and Signs. Eight weeks before admission patient again experienced sudden sharp pain in the left lower quadrant of the abdomen, accompanied by constipation. Fever present. Attack lasted five days, only to recur at frequent intervals until the time of admission. For the last few days, blood and mucus noted in feces.

Loss of Weight. None.

Physical Examination. Rectal mass palpated by examining finger.

Laboratory Data. Wassermann test negative.

Operative Findings (Dr. J. L. Amster). Incomplete intestinal obstruction due to a carcinomatous growth obstructing the descending colon. The mass is about the size of a small orange and situated 20 cm. below the splenic flexure, being densely adherent to the omentum and posterior parietal peritoneum.

Operative Procedure. Resection of the descending colon. End-to-end anastomosis.

PATHOLOGICAL REPORT

Gross. Specimen submitted consists of large intestine 14 cm. in length. At or near the lower border there is seen an oval mass projecting 1 cm. above the level of the mucosa. The edge is indurated and elevated and merges imperceptibly with the adjacent mucosa. At a point 1.5 cm. distant there is seen another small pinkish sessile nodule 1.5 by 1 cm. in size firmly fixed to the mucosa. The large tumor mass above described shows some superficial ulceration.

Microscopic. Adenocarcinoma.

CASE XXIX. (Record no. 2898, lab. no. 573)

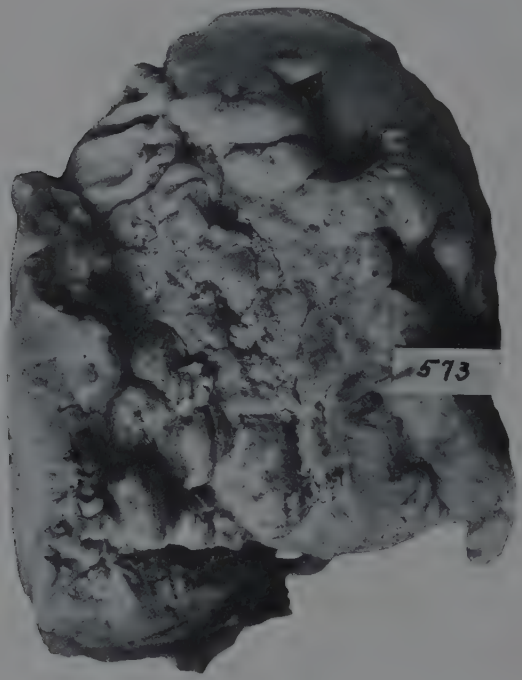

FIG. 80. ADVANCED ADENOCARCINOMA OF THE RECTUM WHICH HAS ALREADY SPREAD BEYOND THE LOCAL LYMPHATIC BULWARK. SPECIMEN 573.

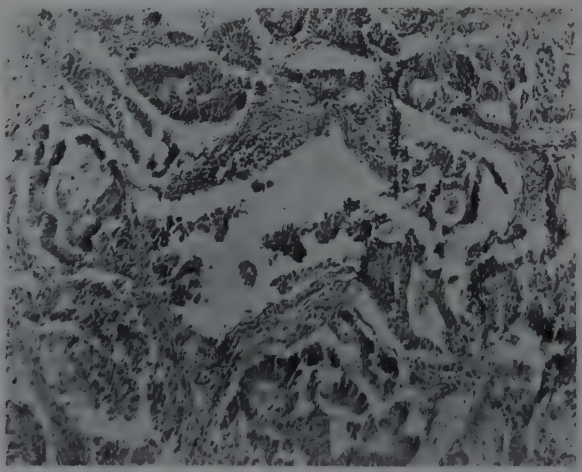

FIG. 81. EXTENSIVE INVASION OF LYMPHATICS BY DIFFUSELY GROWING EPITHELIAL CELLS, OF ATYPICAL MORPHOLOGY, IN FORMATIONS HAVING LITTLE OR NO SEMBLANCE TO NORMAL STRUCTURES, IS SEEN IN ALL ADVANCED CARCINOMATA. SPECIMEN 573.

CASE XXIX. (Record no. 2898, lab. no. 573)

CLINICAL HISTORY

Male, aged fifty years, native of Ireland.

Family History. Irrelevant.

Duration of Symptoms. Four years.

Onset. Loss of weight, passage of flatus.

Chief Symptoms and Signs. Diarrhea, bloody stools, passage of flatus.

Loss of Weight. Sixty pounds.

Physical Examination (relevant). Few palpable lymph-nodes in the left supraclavicular region, emaciation. Rectal tumor mass.

Laboratory Data. Urine shows presence of albumin and casts. Phenolsulphonephthalein excretion 47 per cent in two hours.

Operative Findings. Carcinoma about 5 cm. in size just above the peritoneal reflection on the rectum. No visceral metastases.

Operative Procedure. Abdominal proctectomy.

PATHOLOGICAL REPORT

Gross. Specimen submitted consists of a portion of rectum approximately 15 cm. in length. Approximately 2.5 cm. above the mucocutaneous junction there is seen a large nodular, fungoid sessile tumor 7 by 7 cm. in size in its largest diameters, apparently encircling the gut. There is deep penetration of the rectal wall. Superficial ulceration of the tumor mass is evident.

Microscopic. Adenocarcinoma.

looking margin, usually round and covered with mucus and a little blood. The crater-like center may contain some yellowish necrotic material and other detritus. There is nearly always an associated colitis or proctitis. The papillary tumors which bleed so easily, the associated sessile or polypoid adenomata, and scirrhous carcinomatous strictures each present an individual picture.

Laboratory Aids in the Diagnosis of Epithelial Tumors of the Colon and Rectum. Outside of the microscopic examination of a piece of tissue snipped from a suspicious tumor mass, there is no one laboratory method of much value in the diagnosis of malignancy of the large intestine. The finding of occult blood in the feces is subject to so many variable factors that no undue significance should be attached to the report. A positive benzidine and negative guaiac tests mean very little as the former is so sensitive. In our experience (Felsen) fresh blood intimately mixed with the feces and grossly visible is of greater diagnostic importance. The feces should be carefully examined for tumor fragments, which may occasionally be found, as carcinomata of the large intestine are so prone to ulcerate. The feces should be mixed with plenty of water and strained through a fine-mesh wire sieve (Boas sieve). We are at the present working upon a satisfactory method for carrying out this procedure, as it may prove of value in carcinomata located high up in the colon. In late cases, when intestinal obstruction has occurred, there is a tendency toward the retention of nitrogenous substances in the blood.

Careful examination of the colon by means of the roentgen ray has proved of value as an aid to the diagnosis of tumors of the colon. The barium-meal method of examination is practically useless in the study of lesions in the distal half of the colon because of pronounced haustral sacculation and thinning-out of the mixture. For these reasons Carman and Fineman[15] lay considerable stress upon the barium enema. Sixty grams of castor oil are administered on the evening preceding the day of examination. The evening

FIG. 82. POLYPOSIS OF THE COLON. ROENTGENOGRAM SHOWING FILLING DEFECT IN THE PROXIMAL COLON (CARMAN-FINEMAN).

FIG. 83. BENIGN PAPILLOMA (PAPILLARY ADENOMA). ROENTGENOGRAM SHOWING FILLING DEFECT IN THE UPPER BORDER OF THE TRANSVERSE COLON (CARMAN-FINEMAN).

FIG. 84. CARCINOMA OF THE PROXIMAL COLON. ARROW POINTS TO THE FILLING DEFECT (POWELL).

FIG. 85. CARCINOMA OF THE RECTO-SIGMOIDAL JUNCTION. ARROW POINTS TO THE FILLING DEFECT (POWELL). THIS ROENTGENOGRAM WAS TAKEN JUST BEFORE OPERATION (SPECIMEN 591).

meal is omitted and an enema of normal saline is given on the following morning. The constituents of the barium enema mixture are:

Barium sulphate	250 gm.
Mucilage of acacia	500 gm.
Condensed milk q.s. ad	2000 c.c.

This mixture should be of a creamy consistency and is administered at a temperature of 37.6°c. A head of flow of 30 to 60 cm. forces the mixture into the rectum and fills the entire colon in less than ten minutes. Using this technique these observers report an irregularity of outline and, after partial emptying or filling of the bowel combined with palpation, a peculiar mottled appearance in multiple polypoid adenomata of the colon. Malignant tumors usually appear as filling defects due to the mechanical obstruction caused by the mass. The advancing barium column usually terminates in a ragged or conical end. It must be remembered that not all tumors of the colon are revealed by the roentgen ray. The roentgenographer must often resort to manipulation, changes in the patient's position, the use of antispasmodics and, probably most important of all, repeated examinations. The presence of an obstruction to the flow of barium, an intrinsic spasm and filling defect point to neoplastic involvement of the bowel wall. The lesions overlooked by the roentgenographer with greatest frequency are those located in the lower sigmoid or at the rectosigmoidal junction. By the careful correlation of roentgenographic evidence and clinical data, however, much information may be obtained in the case of lesions not accessible to the sigmoidoscope.

Occasionally, tuberculosis[14] of the cecum or proximal colon may simulate the roentgenologic picture of carcinoma. A more common source of confusion is peridiverticulitis, which usually occurs in that portion of the colon most frequently the site of carcinoma, i.e., distal to the hepatic flexure. Usually peridiverticulitis affects the sigmoid and is characterized by a local filling defect with a few barium-filled diverticula. The obstruction, however, is

rarely complete. Diverticula are often simulated by cancerous lesions in pictures taken by the method above described. This observation is of interest in view of the relatively frequent association of carcinoma with diverticula.

Secondary Results of Carcinomata of the Colon and Rectum. Dilatation and hypertrophy occur in that portion of the bowel located above a carcinomatous stricture. Chronic incomplete or acute complete obstruction may occur due to the size of the tumor mass, impaction of a pedunculated tumor, adherence to adjoining organs, or kinking by a shortened mesentery. Ulceration, hemorrhage (continuous slight oozing due to trauma or sudden profuse bleeding), infectious peritonitis following perforation, carcinomatous involvement of the peritoneum, acute dilatation of the cecum and intussusception have already been mentioned. Metastatic involvement of the lymph-nodes and most of the viscera has been described by many authors. The liver, however, is most commonly affected except in the case of carcinoma of the transverse colon, which tends to involve the stomach by direct extension. In this connection, it is very interesting to note that several patients with carcinomatous nodules in the liver have lived for three years following resection of the rectum (Mummery). Spontaneous anastomosis may occur by perforation of the gut wall, with resultant localized peritonitis and adherence to an adjoining portion of intestine into which the abscess or neoplastic tissue eventually breaks. The opening is usually not large enough to alter the course of the fecal column. In carcinoma of the sigmoid, rupture of the bowel may be the first evidence of pathology in this region, or an acute intestinal obstruction may occur following the ingestion of a heavy meal.

Case xxx. (Record no. 3284, lab. no. 701)

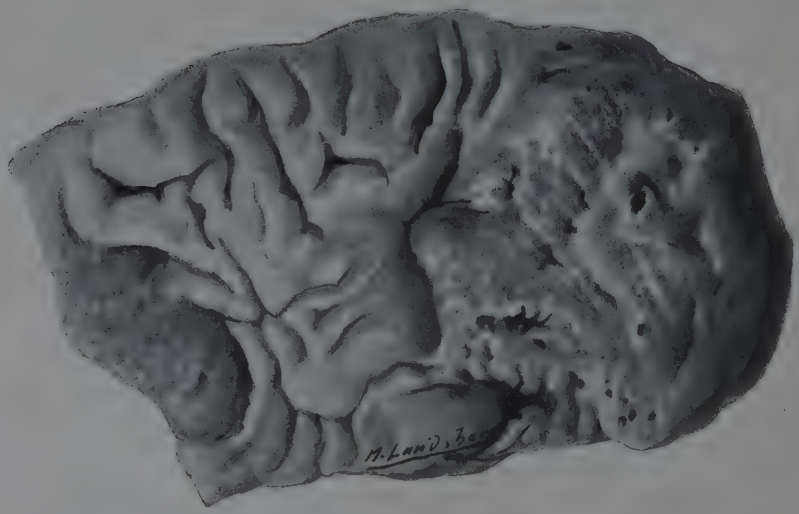

FIG. 86. A LARGE SCIRRHOUS TYPE OF CARCINOMA ENCIRCLING THE RECTUM AND ACCIDENTLY NOTICED BY THE SURGEON IN THE COURSE OF AN OPERATION FOR HEMORRHOIDS. IN OPENING THE RECTUM THE MARGIN OF THE TUMOR MASS HAS BEEN ACCIDENTALLY INCISED. SPECIMEN 701.

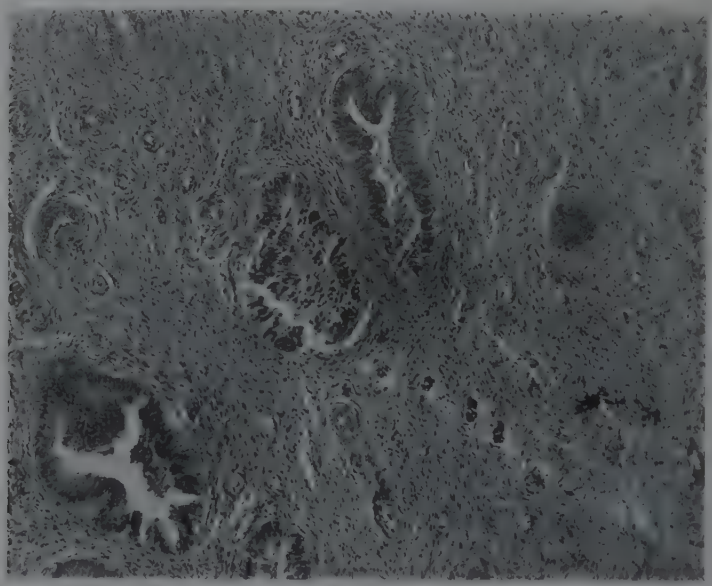

FIG. 87. AREAS OF GLANDULAR TISSUE EMBEDDED IN A THICK, RICHLY VASCULAR FIBROUS STROMA. SPECIMEN 701.

CASE XXX. (Record no. 3284, lab. no. 701)

CLINICAL HISTORY

Female, married, aged sixty years, native of U. S. A.

Family History. Irrelevant.

Duration of Symptoms. Three months.

Onset. Accidentally noted by surgeon during removal of hemorrhoids.

Chief Symptoms and Signs. Occasional blood-streaked stools.

Remarks. Menopause eight years before.

Loss of Weight. None.

Physical Examination (relevant). Mass approximately 3 cm. in diameter, located on the right and posterior walls of the rectum, approximately 2.5 cm. from the anal orifice.

Laboratory Data. Urine contains albumin and casts.

Operative Findings. Small carcinoma situated close to the anus on the right side, apparently arising in a papilla or crypt.

Operative Procedure. Perineal resection of the rectum.

PATHOLOGICAL REPORT

Gross. Specimens submitted consist of :

1. Mass of tissue 6 by 5 cm. in size exhibiting a mucous surface in the center of which is a small, somewhat stellate scarred area next to which is a whitish, bean-shaped area 1 by 2 cm. in size.
2. Coccyx.
3. Mass of adipose and muscular tissue 7 by 4 cm. in size.

Microscopic. Adenocarcinoma.

CASE XXXI. (Record no. 3731, lab. no. 893)

FIG. 88. ADENOCARCINOMA OF THE RECTUM WHICH HAD BEEN PREVIOUSLY SUBJECTED TO ROENTGEN-RAY AND RADIUM THERAPY. NOTE THE PECULIAR WORM-EATEN APPEARANCE OF THE FLOOR OF THE ULCER, WHICH IS FORMED BY MUSCULARIS. SPECIMEN 893.

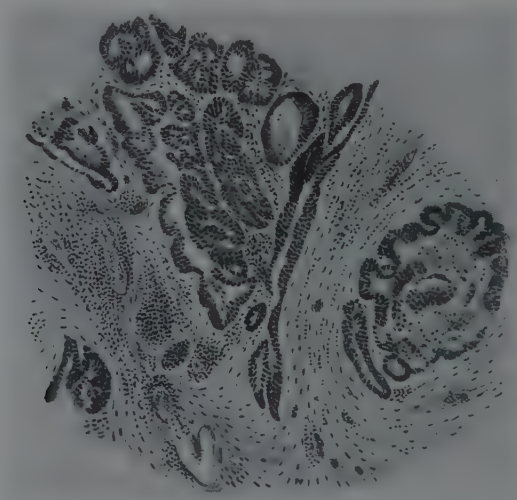

FIG. 89. INVASION OF THE CIRCULAR MUSCULAR COAT BY NEOPLASTIC TISSUE. NOTE THE PERIVASCULAR ROUND CELL INFILTRATION. SPECIMEN 893.

CASE XXXI. (Record no. 3731, lab. no. 893)

CLINICAL HISTORY

Male, aged fifty-six years, native of Italy.

Family History. Irrelevant.

Duration of Symptoms. Six months.

Onset. Patient noted some blood in stool.

Chief Symptoms and Signs. Pain in spine, soreness in rectum, frequent desire to defecate. Some incontinence, mucus and bloody discharge. Constipation present. No weakness.

Remarks. Has had radium and *x*-ray treatment.

Loss of Weight. Twenty-five pounds.

Physical Examination (relevant). Ulcerating tumor mass on left lateral wall of rectum, extending around toward prostate, about 4 cm. in diameter, and freely movable. Lower margin of tumor is situated about 2.5 cm. above the internal sphincter.

Laboratory Data. Wassermann test negative. Blood count normal. Urine showed trace of albumin upon several occasions.

Operative Findings. As already described.

Operative Procedure. Perineal resection of rectum.

PATHOLOGICAL REPORT

Gross. Specimens submitted consist of:

1. Portion of rectum, including anus, 10 cm. in length. Approximately 7 mm. above the mucocutaneous junction there is seen a deeply excavated ulcer with thickened, indurated, heaped-up margin which appears to be deficient for about one-quarter of the circumference. The floor of the ulcerated area has a punctured, pumice-like appearance.
2. Coccyx.

Microscopic. Adenocarcinoma.

CASE XXXII. (Record no. 3388, lab. no. 735)

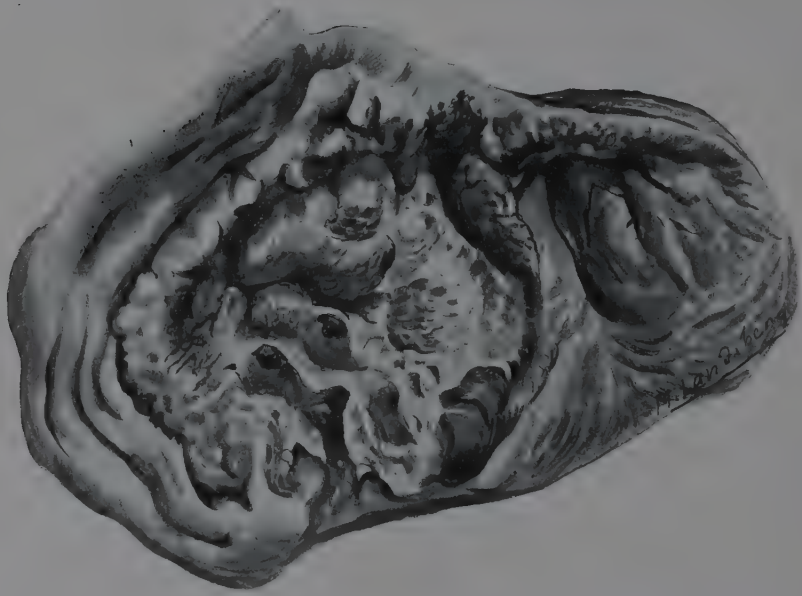

FIG. 90. A RELATIVELY SLOW GROWING ADENOCARCINOMA AT THE RECTOSIGMOIDAL JUNCTION. THE BULK OF THE TUMOR MASS SEEMS TO HAVE SPREAD LATERALLY RATHER THAN DEEPLY. SPECIMEN 735.

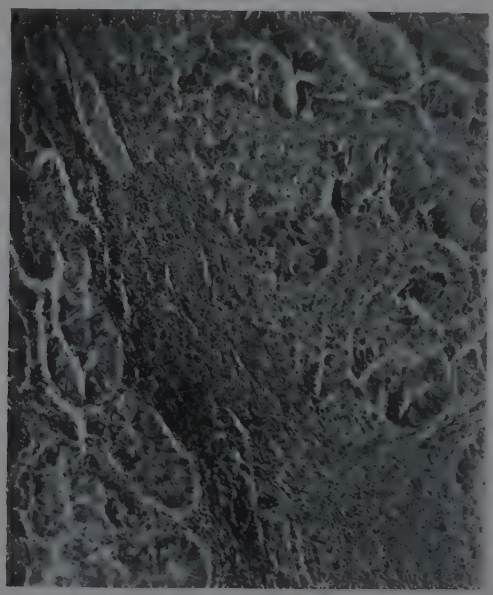

FIG. 91. GROUPS OF ATYPICAL GLANDS EMBEDDED IN A CELLULAR STROMA. SPECIMEN 735.

CASE XXXII. (Record no. 3388, lab. no. 735)

CLINICAL HISTORY

Male, aged fifty-eight years, native of U. S. A.

Family History. Irrelevant.

Duration of Symptoms. One year.

Onset. Reddish to chocolate-colored stools.

Chief Symptoms and Signs. Chronic constipation for the past five years. For the last year, however, since noting blood in stools, has had frequent desire to defecate. Pus and mucus passed with feces. For past six months pain below umbilicus. No weakness.

Loss of Weight. None.

Physical Examination (relevant). Internal and external hemorrhoids. Ulcerating, cauliflower-like growth at rectosigmoidal junction.

Laboratory Data. Urine contains albumin and casts.

Operative Findings. Growth about the size of a hen's egg at the rectosigmoidal junction. Long redundant sigmoid.

Operative Procedure. Combined operation for carcinoma of the rectum.

PATHOLOGICAL REPORT

Gross. Specimen consists of a portion of large intestine approximately 14 by 8 cm. in size, exhibiting an irregularly oval, somewhat superficial, slightly elevated nodular mass 7.5 by 10 cm. in size, occupying most of the mucous surface. The margin of the tumor is not prominently raised except near the upper pole. The mass appears to have been completely circumscribed.

Microscopic. Adenocarcinoma.

CASE XXXIII. (Record no. 3646, lab. no. 868)



FIG. 92. CONSTRICTING CARCINOMA AT THE RECTOSIGMOIDAL JUNCTION. PART OF THE TUMOR HAS BEEN EVULSED DURING OPERATIVE REMOVAL. SPECIMEN 868.

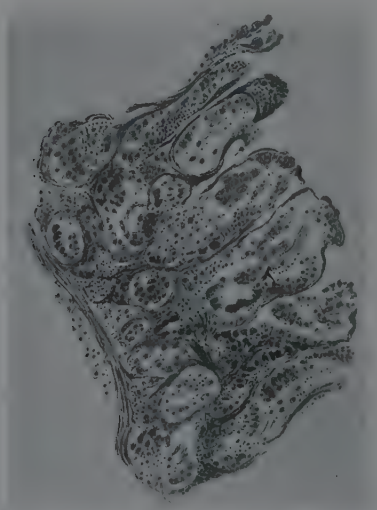

FIG. 93. NOTE ATYPICAL MORPHOLOGY IN THE MUCOSA AND PENETRATION OF THE MUSCULARIS MUCOSAE BY CARCINOMA CELLS. SPECIMEN 868.

CASE XXXIII. (Record no. 3646, lab. no. 868)

CLINICAL HISTORY

Male, aged sixty-two years, native of U. S. A.

Family History. Irrelevant.

Duration of Symptoms. One year.

Onset. Tired feeling, sudden onset of constipation.

Chief Symptoms and Signs. Slight blood staining on toilet paper after movement of bowels. Dragging pain in bladder region associated with constipation for the last six months.

Loss of Weight. Six pounds.

Physical Examination (relevant). Constricting tumor at rectosigmoidal junction.

Laboratory Data. No anemia. Other examinations normal except for chronic nephritic condition.

Operative Findings. Carcinoma of rectosigmoidal junction.

Operative Procedure. Preliminary colostomy, followed by perineal resection of rectum.

PATHOLOGICAL REPORT

Gross. Specimen consists of a portion of the large intestine 15 cm. in length, presenting near one end an oval, firm, nodular, pinkish, sessile mass with raised, everted indurated margin. Another specimen, 5 by 3 cm. in size, accompanies the above and appears to be part of the tumor mass broken off. The tumor proper is situated just above the anal margin and measures 4 by 2 cm.

Microscopic. Adenocarcinoma.

Chapter V

THE SURGICAL TREATMENT OF PRIMARY EPITHELIAL TUMORS OF THE COLON AND RECTUM

Chapter V

THE SURGICAL TREATMENT OF PRIMARY EPITHELIAL TUMORS OF THE COLON AND RECTUM

(1) *Benign Tumors.* Anal warts should be snipped off and the bases cauterized with fuming nitric, trichloracetic acids or by means of heat. Adenomata of the rectum should be promptly removed through the proctoscope by means of a snare or ligation and excision. Large villous adenomata are best treated by resection. Of course, any tumor showing the least suspicion of malignant transformation should be treated exactly like a carcinoma.

(2) *Carcinomata.* The surgical treatment of carcinoma of the colon or rectum may be divided into curative and palliative.

Curative Treatment of Carcinomata of the Colon and Rectum

Complete excision of all of the cancerous tissues and involved lymph areas is the only permanent cure recognized at present. Unfortunately the peculiar pathological and, we might say, biological tendencies of carcinoma of the large intestine make one often feel quite hesitant in predicting an operative cure. However, experience has taught us that the percentage of permanent cures is larger by operative means than by any other known method. In our opinion recurrence after five years is very exceptional, so that for practical purposes freedom from recurrence for this period indicates a permanent cure.

General Considerations Involved in Resection of the Intestine for Carcinoma. *Indications for Operation.* Modern surgical technique in the hands of a competent operator has resulted in the use of more aggressive measures in the treatment of carcinomata of the intestine. An early diagnosis in a patient otherwise in good health is conducive of the best results. More-

over the growth should not be fixed to the surrounding structures nor should extensive lymphatic involvement be present. Under these conditions, there should be no choice of operation other than complete resection, including all of the lymphatic area involved. We have often been agreeably surprised at the excellent results obtained in patients of advanced age and generally considered to be poor risks. We shall therefore include only complete resection of the affected area as the operative cure of carcinoma of the colon or rectum. Radical resection should be attempted even when there is a possibility that small areas of carcinomatous tissue might be left behind. It must be attempted even in the presence of extensive lymph-node involvement, as all enlarged lymph-nodes are not cancerous. It should also be remembered that most cancerous growths are rendered inoperable only by reason of their local extension.

Preliminary Colostomy. Some surgeons maintain that the best routine procedure is to make a preliminary colostomy about one week before resection, in order to prevent fecal material from contaminating the wound area.

Inguinal Colostomy. The operation can be easily performed under local anesthesia when necessary. After the usual preoperative preparation (morphine-atropine, cleansing of skin), the abdomen is opened by means of a left rectus incision just below the umbilicus. The intestine is pulled out between the muscle fibers, which help in the future control of bowel movements. A loop of the sigmoid is chosen and a glass rod passed through an avascular portion of the mesocolon of the upper part of the bowel. Skin sutures are passed at either angle of the wound. Under either end of the glass rod a piece of gauze is placed to prevent injury to the skin. The peritoneum is sewed around the bowel by means of four to six interrupted plain catgut sutures, and the wound closed by means of silkworm gut sutures passed through the skin, fascia and back again through the fascia and skin. In this way the wound is closed

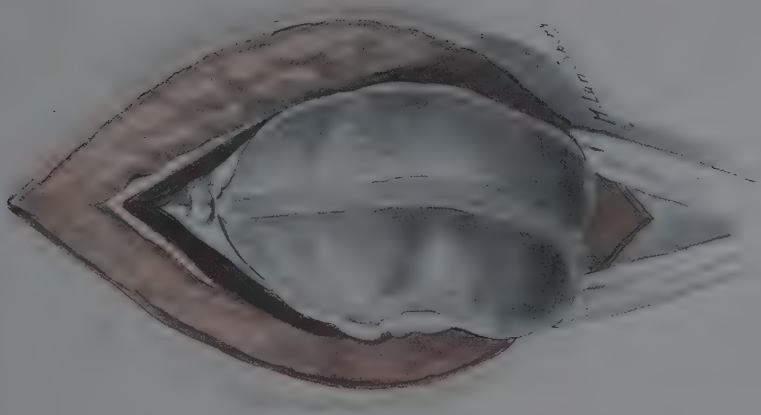

FIG. 95. COLOSTOMY. 2. SUTURING THE PERITONEUM AND ANCHORING THE PERITONEUM BELOW.

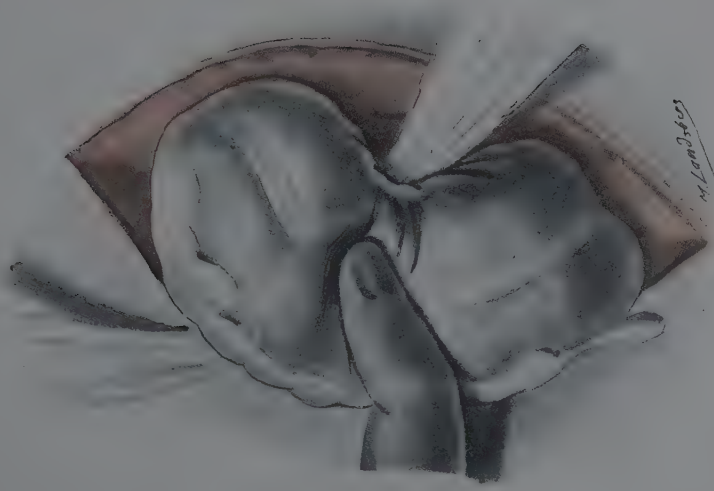

FIG. 94. COLOSTOMY. 1. DELIVERY OF A KNUCKLE OF SIGMOID. BECAUSE OF A RATHER SHORT MESENTERY GAUZE TRACTION IS BEING UTILIZED.

snugly around the bowel. Finally a piece of rubber tissue is wrapped around the gut to prevent anything adhering to it, and over this is placed some gauze, held in position by adhesive straps at some distance away from the bowel.

Two or three days later a small transverse incision is made in the insensitive wall of the protruding gut, of sufficient size to short circuit the fecal column. A week later the bowel is completely divided, the operator taking proper precautions against hemorrhage. The result is two stomata: an upper, leading into the descending colon, and a lower, communicating with the rectum. The patient may wear an abdominal belt, the part covering the artificial anus being made of smooth rubber with a pad of absorbent cotton interposed. Good voluntary control is obtained by contraction of the rectus fibers, especially if the incision and protruding portion of gut are small. A simple diet is chosen and, if necessary, some astringent to control any slight diarrhea.

In Tuttle's method, an incision about three inches in length is made through the skin and superficial fascia in a line with the fibers of the external oblique muscle, about 1 inch above and 1½ inches inside of the anterior superior spine of the ileum. The sigmoid is brought through a slit in the internal oblique muscle, and then through a canal made between the external oblique and skin, for a distance of approximately 2 inches. The skin opening is then made just above Poupart's ligament. Efficient voluntary control is secured by this method.

Lynch, instead of bringing the gut through a slit in the internal oblique and then under the skin, draws it through the wound. A bundle of muscle fibers is separated from the lower lip of the external oblique and the gut is pulled through this opening by means of forceps. Another bundle is selected from the upper lip and the gut pulled through the upper opening. In this way a figure-of-eight sphincter is formed.

In making the stoma, Tuttle first makes a transverse incision which bisects the gut. From the middle of this incision another vertical one is made to the apex of the upper limb of the gut. The result is two triangular flaps which roll backward and curl up in the upper segment of gut. The straight flap in the lower segment falls downward and inward practically closing the lower aperture. Closure may be effected by suturing the edges of the T-wound together without opening the peritoneal cavity.

Transverse Colostomy. For growths located in the sigmoid, a transverse colostomy is indicated. A vertical rectus incision is made extending downwards for a distance of about 2 inches from a point a little above the umbilicus. After opening the peritoneal cavity the great omentum is pulled into the wound until the transverse colon appears. A knuckle of this portion of the large intestine is chosen as near the splenic flexure as possible, providing no undue tension is exerted upon the stomach. A small avascular area is chosen in the great omentum, an opening is made and the colon pushed up through it. A glass rod is passed beneath the knuckle of gut, the ends of the rod resting vertically upon the abdomen. The angles of the skin incision are closed as in the case of inguinal colostomy above described.

Lumbar colostomy is sometimes performed when the sigmoid cannot be brought up into the inguinal wound or, on the right side, in preference to cecostomy. With the patient lying on the side and a sandbag underneath the loin, an oblique incision is made about midway between the last rib and iliac crest. This incision starts at a point about 1½ inches in front of a vertical line drawn just posterior to the middle of the iliac crest and is carried upwards and backward for about the same distance behind the vertical line. The anterior edge of the quadratus lumborum is found, the transversalis fascia is opened and the colon exposed. A small portion of the gut is circumscribed by sutures attaching it to the skin. If peritoneum is encountered (mesentery for the ascending colon) the same procedure as in inguinal colostomy is used.

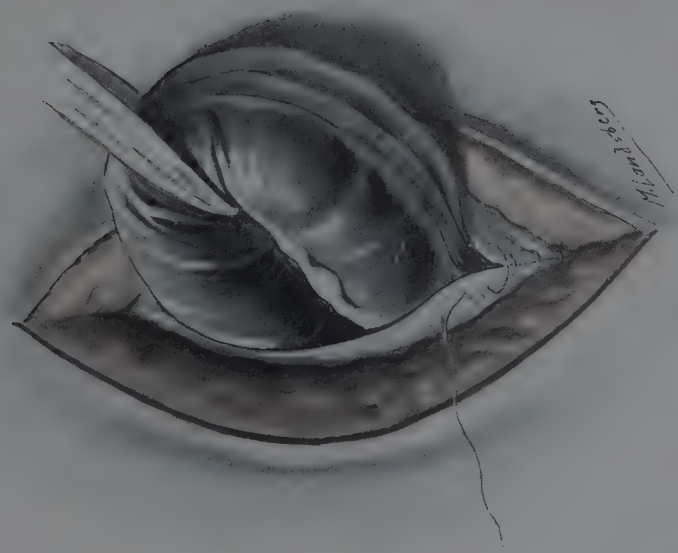

FIG. 97. COLOSTOMY. 4. SUTURING THE FASCIA, INCLUDING THE LONGITUDINAL BAND.



FIG. 96. COLOSTOMY. 3. ANOTHER VIEW OF STEP 2.

Cecostomy is performed when some anatomical abnormality prevents the carrying-out of a colostomy procedure, or when the carcinoma is situated very high up in the large intestine. A right oblique incision is made about midway between the umbilicus and anterior superior spine. The abdominal cavity is opened and a knuckle of cecum brought forth. After walling off

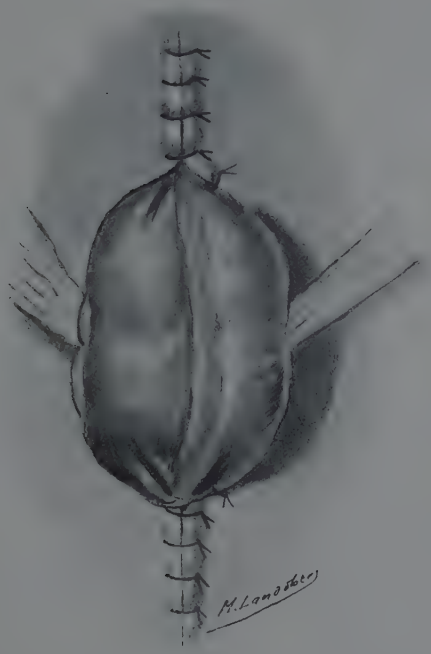

FIG. 98. COLOSTOMY. 5. SKIN SUTURED. GUT ANCHORED ONLY AT ANGLES. THIS STEP IS FOLLOWED LATER BY A CROSS INCISION WITH THE CAUTERY.

the gut with gauze, a small opening is made in the cecum and a rubber tube of about 12 mm. diameter is pushed into the canal and sewed in by sutures which invert the intestinal wall about it. Further protection is secured by a purse-string suture outside of the inversion stitch. The ends of the purse-string suture are continued through peritoneum and aponeurosis and tied

in order to fix the rubber tube firmly to the abdominal wall. The latter is then closed about the tube. The drainage material will be chiefly fluid.

Paul's Colostomy Method. Paul's method of performing a colostomy is to expose a knuckle of colon as in the inguinal method. The wound is then packed off by gauze and the colon completely divided. Paul's glass tubes are sutured in either stoma by means of silk, and a side-to-side suture of the exposed gut is made with silk. About four weeks later an opening is made with the enterotome in the partition formed by the sewing-together of the adjoining walls of exposed gut. It takes about a week to reestablish the continuity of the bowel but many months may elapse before the external opening closes up. To facilitate closure, the edges of the opening in the colon are dissected free, inverted and closed. The skin and deeper tissues are then approximated.

Closure of Colostomy Wound. The closing of a colostomy wound may be done by either the extraperitoneal or intraperitoneal method, depending upon the type of procedure originally used in making the stoma. If the bowel has not been completely divided, the former method may be used. After the bowel has been thoroughly cleaned by cathartics the opening in the colon is dissected free and closed by means of a double row of sutures. The colon and peritoneum are now dissected from the anterior abdominal wall and the gut left in the roomy pocket thus formed. The abdomen is then closed.

In the intraperitoneal method an incision is made at some distance from the colostomy. The peritoneal cavity is opened and intestine dissected free so that the entire colostomy area and adjoining colon can be drawn out of the abdomen. Necrotic and unhealthy intestinal tissue is then dissected away or, if necessary, a small resection may be done. An end-to-end anastomosis is next made or, if only a hole is left, a wedge-shaped section is taken out of the gut, the base being on the side opposite, not adjoining, the mesentery. This precaution assures preservation of the blood supply to the joined edges.

FIG. 99. PERINEAL RESECTION OF THE RECTUM (FEMALE). I. PURSE-STRING SUTURE SHUTS OFF THE ANAL ORIFICE. COCCYX EXPOSED BY INCISION MADE POSTERIOR TO THE ANUS. COCCYX IS EXCISED. NOTE INCISION IN POSTERIOR VAGINAL WALL.

The intestinal opening is then closed with through-and-through catgut sutures reenforced by a layer of peritoneal sutures. A rubber-tissue drain is left in place at the site of the intestinal closure, instruments and gloves are changed, and the abdomen closed. The drain is removed in about two days. A rectal tube is left in place at the time of operation and gentle irrigation with water is given twice daily for several days. Mild catharsis (liquid petrolatum, saline cathartics) is used daily in order to keep the stools as liquid as possible.

Complete Perineal Resection of the Rectum. About seven to ten days are allowed to elapse after the colostomy operation. During this time the bowel below the opening is irrigated with peroxide or permanganate solution several times daily. Usually at the time of the short-circuiting operation the surgeon may get some idea of the extent of neoplastic involvement through the abdominal incision. As regards the choice of an anesthetic, the ideal method is probably sacral anesthesia. Narcosis and ether, nitrous oxide and oxygen, local anesthesia and spinal anesthesia are some of the usual methods in use, singly or combined.

The principles underlying the choice of anesthetic are: (1) The avoidance of postoperative vomiting. Herniation or hemorrhage may result therefrom. (2) The avoidance of shock associated with mesenteric or peritoneal traction. As a general rule there is very little bleeding in a carefully performed operation. Attention to the minutest details is conducive to the best results in all patients, but especially in the type of poor risk so often encountered. Resection of the rectum by the perineal method may be used in cases where the growth is situated in the anus or rectum as far up as the rectosigmoidal junction. Small growths in the latter situation may be removed, however, if the sigmoid is long. Fixation of the tumor mass to surrounding structures will, of course, limit the usefulness of this particular method of resection. Assuming that the patient has been given a reasonable opportunity to gain

strength by means of a nutritious diet and to overcome the toxicity incident upon statis, the following procedure is used. While a preliminary colostomy is undoubtedly desirable, it has occasionally been deemed advisable not to subject the patient to any further delay. It is questionable, however, whether a period of two or three weeks makes any serious difference in the ultimate outcome of the case. A preliminary colostomy is always the best procedure except in cases of acute hemorrhage.

The patient receives several peroxide irrigations of the lower bowel the day preceding, and the morning of, the operation. Morphine sulphate gr. $\frac{1}{6}$ and atropine gr. $\frac{1}{100}$ are administered to the patient about one-half hour before being brought to the operating room. All undue excitement is avoided in the preoperative preparations. The patient is deprived only of breakfast. The lithotomy position is used and the rectum washed out with full strength hydrogen peroxide. A catheter of suitable size is tied into the urethra of a male patient in order to act as a guide during the operation. In women, the vagina is thoroughly irrigated and iodinized. The rectum is packed with gauze, the skin is iodinized and surgical asepsis begun. Some operators occlude the anus by means of a subcutaneous purse-string silk suture. An elliptical incision is made around the anus starting at the base of the sacrum and encircling the anus about one inch distant anteriorly. The incision is continued deeper into the ischiorectal fossae, the operator being careful not to open the rectum. The external sphincter is divided anteriorly and posteriorly. The coccyx, and, if necessary, part of the sacrum, are disarticulated. An opening is made in the levator ani muscle and the rectum. The mesorectum and fatty tissue together with the lymph-nodes are gently peeled from the sacrum. If the mesorectum cannot be peeled off, it is cut close to the bone by means of scissors with a very long handle curved on the flat, and the cavity packed with plain sterile gauze. The index finger is then hooked over the levator ani muscle and it is separated from the rectal wall on either side by means of scissors. After finding the proper line of

FIG. 100. PERINEAL RESECTION OF THE RECTUM (FEMALE). 2. LEVATORES ANI HAVE BEEN CUT. LATERAL LIGAMENT IS BEING CLAMPED.

FIG. 101. PERINEAL RESECTION OF THE RECTUM (FEMALE). 3. THE RECTUM IS DISSECTED AWAY FROM THE BLADDER AND URETHRA (AND FROM THE PROSTATE, IN THE MALE). IF NECESSARY, PERITONEUM IS INCISED IN ORDER TO BRING DOWN THE SIGMOID.

FIG. 102. PERINEAL RESECTION OF THE RECTUM (FEMALE). 4. LIGATION OF THE SUPERIOR HEMORRHOIDAL ARTERY.

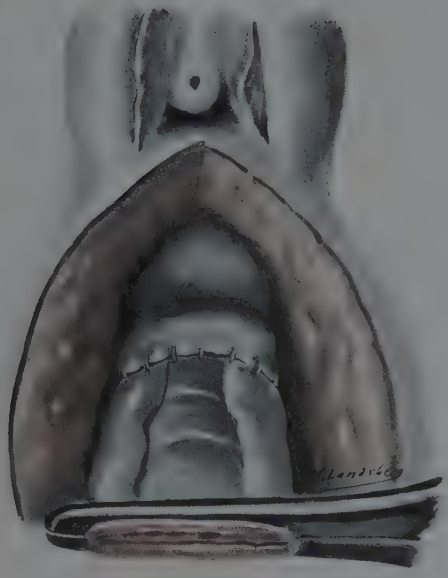

FIG. 103. PERINEAL RESECTION OF THE RECTUM (FEMALE). 5. THE RECTUM IS EXCISED BETWEEN CLAMPS BY MEANS OF THE ELECTRIC CAUTERY. THE PERITONEUM IS CLOSED BY MEANS OF INTERRUPTED SUTURES.

FIG. 104. PERINEAL RESECTION OF THE RECTUM (FEMALE). 6. FASCIA AND LEVATORES ANI CLOSED (VENTRAL VIEW).

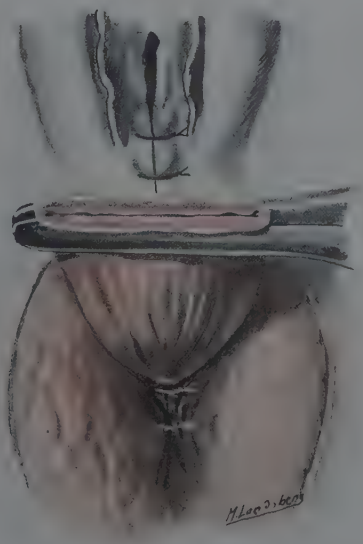

FIG. 105. PERINEAL RESECTION OF THE RECTUM (FEMALE). 7. SAME AS STEP 6, DORSAL VIEW. VAGINAL INCISION CLOSED.

cleavage the operator very carefully dissects the bowel anteriorly from the urethra and prostate. When the peritoneum is reached it can be peeled off gently and in many cases need not be opened. If it must be opened in order to bring down the bowel, gauze is immediately packed in to prevent the small intestines from coming into the wound. The rectum is next freed from its lateral supports, placing two clamps on each ligament to prevent bleeding from the middle hemorrhoidal artery. If this precaution is not observed, the resulting hemorrhage is likely to cause the surgeon a great deal of trouble and unnecessarily delay the operation. The lateral ligaments are cut between the forceps. The rectum should then come down easily. If it fails to do so, the hand is introduced posteriorly and carefully swept around the rectum, separating it from other attachments until it can be brought down through the anus. The operator should not pull on the bowel or use unnecessary force at any stage as the mesentery may be torn and severe he norrhage ensue. The healthy intestine having been brought outside the anus, the peritoneum is closed by interrupted catgut sutures attached to the anterior wall of the bowel. The peritoneum should not be sewed too snugly around the bowel nor should a continuous suture be used as either is very likely to be followed by stricture of the intestine. The levator is picked up and sutured to the bowel and the dead space in front is closed with No. 1 chromic catgut. A few interrupted sutures are taken through the muscular layer of the bowel and the tissue inside of the sphincter in order to approximate the sphincter and bowel. The sphincter itself is next sutured anteriorly and posteriorly and then the levator ani muscle with its fascia for a distance of about one-half inch. The rest is allowed to remain open until after the bowel has been amputated and sutured. A nick is nade in the bowel anteriorly and the mucosa carefully examined to make sure of absence of growth as well as to deter nine whether or not the blood supply is adequate. The incision is then carried all around the bowel and the mucous membrane is caught with T-forceps, care

being taken when the mesentery is reached that all of the blood-vessels have been ligated. The mucosa is sutured to the skin and a drainage tube inserted into the bowel. The remainder of the pelvic diaphragm is now closed except for an opening sufficiently large to admit a drainage tube around which gauze is lightly packed. A safety pin is passed through each drainage tube for anchorage and some fluffed gauze packed around externally. The patient is placed upon one side with legs well extended and buttocks strapped with adhesive.

Mummery invaginates the stump of the sigmoid and closes the peritoneum and remainder of the wound without drainage. If the posterior vaginal wall be involved it is removed together with the rectum.

After-treatment, except for patients in poor condition, consists in allowing water by mouth for twenty-four hours and then gradually increasing the quantity and variety of food so that by the third day the patient is on a regular liberal diet. Within one week to ten days after operation the patient is encouraged to get out of bed. For the first week the bowels are regulated by warm saline irrigation followed by the injection of olive oil. At the end of this period oil, calomel or cascara are administered by mouth. For troublesome distention, gastric lavage may be used. Hypodermoclysis or transfusion has often been resorted to in order to tide a patient over a critical period. In recent years we have given one preliminary unmodified blood transfusion just before operation and when necessary, another before the patient leaves the table. Since this procedure has been instituted at St. Bartholomew's Hospital the operative risk has been definitely lessened.

In this connection it might be stated that our custom has been to secure a suitable donor (professional or voluntary) one day before the scheduled time for operation. Our standards for judging a suitable donor are:

(1) Freedom of donor from infectious disease.

(2) Donor to be in robust health.

These two criteria are judged by means of a thorough physical examination and a Wassermann test.

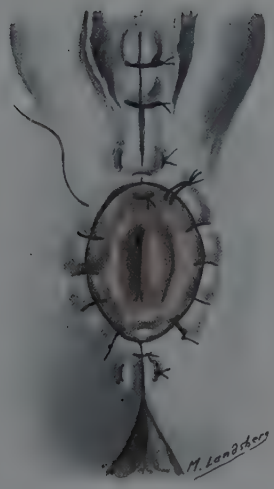

FIG. 106. PERINEAL RESECTION OF THE RECTUM (FEMALE). 8. REBUILDING OF THE PERINEUM AND MAKING OF A PELVIC SUPPORT POSTERIORLY. (A DRAIN IS PLACED IN THE HOLLOW OF THE SACRUM.)

FIG. 107. PERINEAL RESECTION OF THE RECTUM (FEMALE). 9. THE COMPLETED PERINEUM.

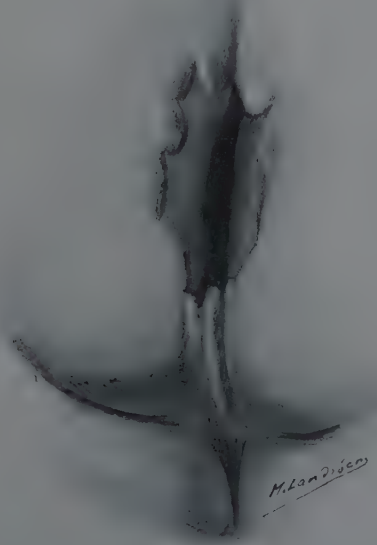

FIG. 108. PERINEAL RESECTION OF THE RECTUM. 10. THE RESULT AT THE END OF FOUR WEEKS AFTER A PERINEAL RESECTION OF THE RECTUM.

(3) Donor to possess a normal red blood-cell count and a hemoglobin of 90 per cent.

(4) Donor and recipient to be in the same blood group (Moss or Jansky).

(5) Donor and recipient not to cross agglutinate (direct blood matching).

The Combined Operation (Abdominoperineal Excision). When the carcinoma is situated slightly above or below the peritoneal reflection, the combined operation is unquestionably the best one. Were it not for a high mortality rate this would be the preferred operation in all cases of cancer of the rectum. The combined method has many advantages over the perineal or sacral operations. It insures a bloodless procedure and allows the operator great freedom in a scrutiny of the liver and lymph-nodes, thereby aiding in the determination of whether the patient should be left with an artificial anus or the sigmoid be brought down and attached to the skin. Our technique is a combination of sacral anesthesia with blocking of the sympathetic at the bifurcation of the aorta, tying-off of the sigmoidal and superior hemorrhoidal arteries and the making of a new peritoneal diaphragm so that the abdominal wound can be closed before proceeding with the perineal portion of the operation.

There are two methods which may be followed: one, whereby the continuity of the bowel is not disturbed and, after excision of the tumor, the bowel is sutured to the anus or skin; the other, whereby the patient is left with an artificial anus, all of the bowel together with the perisigmoidal and perirectal fat and glands below the artificial anus being removed. This is the operation which a great many surgeons believe should have preference over all others, as it is the most radical and insures a better chance of permanent cure. Each of these operations has its advantages and has a definite place in the surgery of the large intestine. No dogmatic statements can be made to apply to all patients. Each case must be judged individually according to the conditions found at the time of operation.

The patient having been prepared in the usual manner, the rectum is irrigated with hydrogen peroxide. The patient is placed on one side and the sacral plexus anesthetized. This is done by inserting the needle into the opening of the sacral canal in the midline at a point just above the last sacral spinous process. The needle is passed at an angle of about 15° and if the fingers are sensitive the point can usually be manipulated into the sacral opening without great difficulty. Cocaine or novocaine may be injected. The trocar is reinserted in the needle and the whole left in place until anesthesia has been obtained. Some operators prefer magnesium sulphate solution to cocaine or novocaine.

The patient is then placed in the prone position and, the abdomen having been properly prepared, an incision is made in the median line and continued to one side of the umbilicus, preferably the left. It is very important to make a large incision so that the operator may not be hampered in his work. The fascia is incised, recti separated and abdomen opened in the usual manner. The patient is now placed in the Trendelenburg position. Before proceeding with the operation the small intestine must be packed off. One large laparatomy pad is used (about the size of an ordinary towel). The table is now returned to the horizontal position. A self-retaining abdominal retractor is placed in position, thereby allowing easy access to all parts of the pelvis. The surgeon needs very little assistance for the subsequent steps of the operation. It is an advantage to be relieved of the always intrusive assistant's hand. At this point the mode of procedure may take one of two courses:

Procedure A. The sigmoid is pulled out of the wound and held taut, thus making the sigmoid artery stand out prominently. The peritoneum is incised just above the point of origin of the sigmoid artery. A pair of scissors curved on the flat is passed into the peritoneal opening and the peritoneum gradually separated from the blood-vessels and glandular tissue.

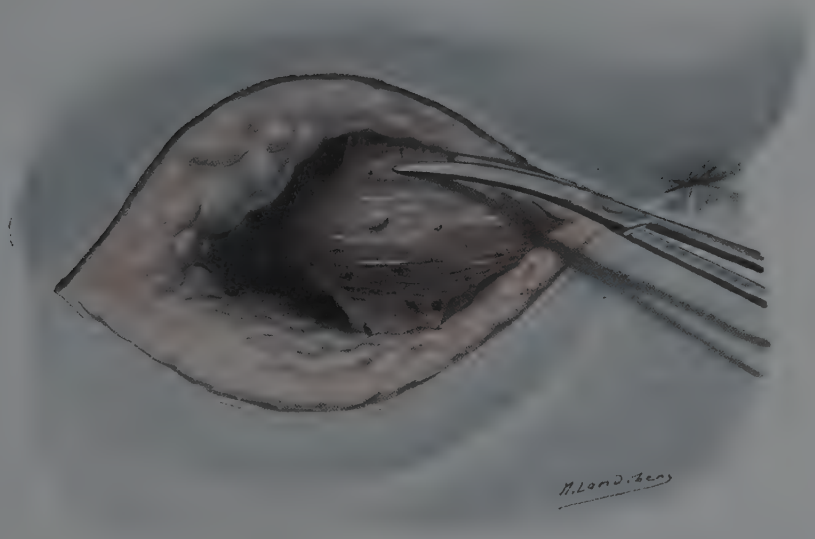

FIG. 109. COMBINED OPERATION FOR CARCINOMA OF THE RECTUM. PRESERVATION OF THE RECTAL SPHINCTER (MALE).

FIG. 110. COMBINED OPERATION FOR CARCINOMA OF THE RECTUM. PRESERVATION OF THE RECTAL SPHINCTER (MALE).

A thin spatula-retractor is slipped into the incision and, using this as a guide, the peritoneum is incised parallel to the gut down to the peritoneal reflection. The gut is then turned over to the other side and the same process is repeated. The sigmoidal artery is double-tied and cut between the ligatures. By means of scissors curved on the flat all of the fatty tissues and glands can be scooped out without difficulty. The superior hemorrhoidal artery is next double tied and cut between the ligatures. This having been done, the rectum can be separated from its attachment to the sacrum as far down as the levator ani muscle. Care should be taken, however, not to injure the middle sacral artery. If this artery be preserved intact the operation is a bloodless one. A piece of gauze is now packed into the pelvic wound. The rectum is separated from the bladder and prostate or uterus and vagina, as the case may be, by gradual dissection with the fingers. The gauze is then removed from the pelvis. Having loosened the gut sufficiently so that the bowel can be brought down to the anus without tension and being satisfied that the blood supply is intact, the procedure will vary according to conditions encountered.

Procedure B. If a permanent colostomy is decided upon the following procedure is adopted: the abdomen is thoroughly walled off by pads and the bowel divided between two clamps by means of a Pryor clamp-cautery. The latter minimizes the chance of infection and has the still further advantage of sealing both ends of the bowel so that there is hardly any possibility of infection resulting from this source. The proximal end of the divided bowel is covered with a gauze pad and tied with tape. The distal end of the bowel is held up by an assistant, and the operator, having first tied the superior hemorrhoidal artery, proceeds to remove the distal portion in the following manner:

Both layers of the peritoneum are cut and the bowel separated from the sacrum posteriorly as far down as the levator ani muscle; the peritoneum is

separated from the bladder or uterus; the bowel is then separated from the bladder and prostate or uterus and vagina. This having been accomplished, a Wales bougie is passed into the rectum and the gut tied over the bougie by means of a strong tape. The bougie is now withdrawn and in so doing the bowel is inverted.

At this stage great care should be taken to free the lateral peritoneal attachments of the rectum so that the subsequent operation of removing the distal end from below may be much easier and shock minimized. The peritoneum forming the pelvic diaphragm is closed and all raw surfaces covered with peritoneum. The proximal end of the gut may be left in the wound, in a separate opening located at some distance from the original wound, or it may be brought out between the external and internal oblique muscles as in any permanent artificial anus. A Paul tube is inserted in the proximal end of the gut and the wound closed in the usual manner. Whichever method is adopted a Paul tube should be tied in the gut to prevent leakage and infection.

When the sigmoid is involved, especially at or near the apex, one of several procedures may be followed. Unfortunately, however, two of the operations, viz., resection with end-to-end anastomosis and resection with lateral anastomosis, are followed by a high mortality on account of the leakage of septic material. It occurred to the late Dr. Tuttle that it would be much safer if the tumor with the involved glands could be brought entirely out of the abdominal cavity and then be removed at a subsequent sitting. As a result he developed the following technique, known as the three-step operation:

Tuttle's Three-step Operation. An incision about 4 inches in length is made outside of the left rectus muscle. A self-retaining retractor is fixed in place, the patient placed in the Trendelenburg position, and the small intestine walled off. The sigmoid is brought out of the abdomen and the

peritoneal covering of the mesosigmoid is slit along for a distance well above and below the tumor. It is then peeled back to the posterior abdominal wall, exposing the blood-vessels and the surrounding tissues and lymph-nodes, loosening the attachment of the gut and allowing it to be brought out upon the abdominal wall. The blood-vessels supplying the part of the bowel involved by the growth are exposed by pulling or milking away toward it the surrounding lymph-nodes and fatty material. The arteries and veins can then be clearly seen, and the main vessel supplying the involved region is cut and tied in two places. The gut is thus loosened and can be pulled freely out of the abdominal cavity. The stump of the blood-vessels is pushed back between the two peritoneal layers of the mesosigmoid which are then stitched together, covering up all of the denuded surface in the peritoneal cavity. The two legs of the loop of the sigmoid are now brought together by one row of sutures running along the mesenteric border and well within the peritoneal cavity, and then by another row taken for the same distance through the long muscular bands. Two flat sutures of the bowel are thus approximated.

With the tumor well outside of the abdomen, the peritoneum and then the skin are stitched about the two legs. The whole is covered with rubber tissue and left in situ for twenty-four to seventy-two hours, according to the condition of the patient. If there be any indication of obstruction, a puncture can be made in the upper leg, allowing gas to escape; or if gangrene should be imminent in the exposed loop, there is no reason why it could not be excised any time after eighteen hours or even less. The growth can be removed at the end of twenty hours, if necessary, without causing any complications. When the gut is excised it should be done by a v-shaped incision so that there may be sufficient tissue left for bringing the ends together at a later time.

It will be observed that since the main blood-vessel supplying this loop has been ligated there will be little or no hemorrhage in the resection. There is no danger of peritoneal infection as this cavity will have been closed

off after the first five or six hours. Almost a week should elapse before the clamp is put in to cut away the spur. A Pryor hysterectomy clamp or enterotome should be introduced well into the two legs of the artificial anus. At the end of three to seven days the clamp will cut through and come away. A No. 8 Wyeth modified Wales bougie is then inserted through the rectu n and passed beyond the artificial anus. The tip will usually emerge from the artificial anus but it must be carried on into the upper leg of the spur. Its elasticity will press the spur backwards and cause the mucosa of the artificial anus to roll inward. The bougie is left in for two hours, three times a day, until the wound caused by cutting away of the spur has healed and a wide aperture has been left for the downward passage of fecal material.

The final steps are as follows: The edges of the artificial anus are dissected away from the skin and fascia of the abdominal wall down to the peritoneum; the aperture in the gut is closed by one row of through and through silk sutures and one of fine chromic gut Lembert sutures, which must be carefully placed. The peritoneum is stripped from the abdominal wall for about half an inch all around the wound and all cicatricial tissue and fascia trimmed away. Three or four double anchoring sutures threaded upon agate buttons are passed across the wound and out through the skin on each side about one inch from the margin. After these have been tightened an ordinary subcutaneous suture brings the skin together. The buttons serve as bases for the deep sutures to rest upon and prevent their cutting into the skin, thus rendering them much less painful than the ordinary tension sutures. If the wound should gape, the button could be twisted like a tourniquet, bringing the edges in closer approximation

In resection of the rectum, when the tumor is situated at or near the peritoneal reflection, it is sometimes difficult to unite the ends of the bowel except under tension. In such cases Mummery's procedure has proved very

satisfactory. A glass or heavy rubber tube is passed through the distal end leaving about one-half inch exposed. The proximal end of the gut is pulled over and fastened to the tube by means of a tape or purse-string suture. The distal end is then tied to the tube just below and in the same manner. An assistant now pulls the tube down, causing the upper or proximal end to become invaginated into the lower or distal end. A continuous Lembert suture completes the operation. Kelly's operation is indicated where, after the removal of the tumor, the distal end of the gut is cut so high or close to the peritoneal reflection that difficulty in manipulation is an obstacle to anastomosis. The lower end of the intestine is closed in the usual manner and a longitudinal incision is made anteriorly through the peritoneum and rectum. The rest of our technique differs from that of Kelly in that instead of sutures we use a rubber tube which is introduced into the proximal end of the gut and over which the intestine is tied by means of a tape or purse-string suture. It is then passed down through the anterior rectal slit and, after dilation of the sphincter, delivered through the anus by an assistant. The proximal end of the bowel is then slightly invaginated by traction and union is secured by means of Lembert sutures. The tube is held in position and prevented from retracting into the bowel by means of adhesive or by suture to the skin.

We have in recent years obtained beautiful results in carcinomata of the rectum by removal of the tumor through the abdominal route, leaving the patient with a colostomy. Six to twelve months later the colostomy is freed and the limb of gut inserted into the rectal stump. The various steps in this procedure are illustrated in the accompanying drawings made from one of our patients.

Resection of the Sigmoid. An abdominal incision is made to the outer side of the left rectus muscle. After the abdomen has been opened the patient is placed in the Trendelenburg position and the small intestine is walled off from the field of operation by means of gauze pads. The sigmoid

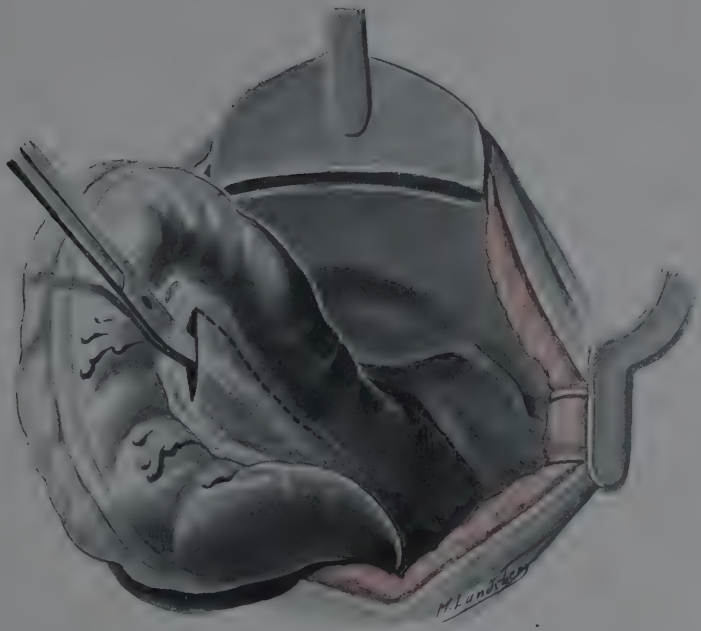

FIG. 111. ABDOMINAL RESECTION OF THE SIGMOID OR RECTUM. 1. SIGMOID LOOP DELIVERED AND PERITONEAL LAYERS BEING PEELED OFF ON EITHER SIDE.

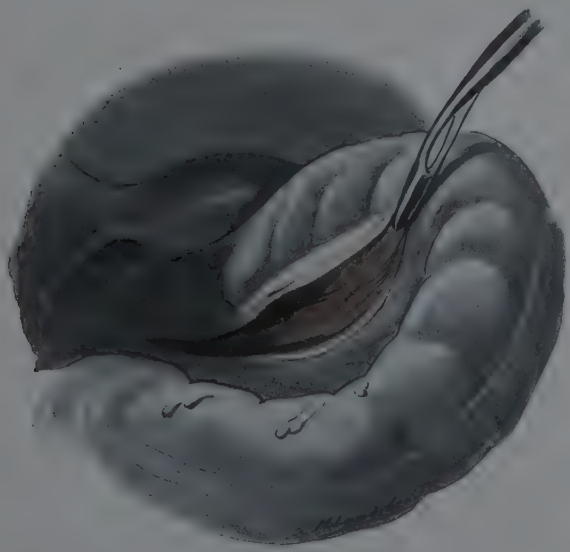

FIG. 112. ABDOMINAL RESECTION OF THE SIGMOID OR RECTUM. 2. A LATER STAGE OF THE PROCEDURE DESCRIBED IN STEP 1.



FIG. 114. ABDOMINAL RESECTION OF THE SIGMOID OR RECTUM. 4. RECTUM CUT AWAY FROM SIGMOID AND RECTAL STUMP BURIED BELOW THE PERITONEAL DIAPHRAGM. THE PERITONEUM IS BEING CLOSED OVER THE STUMP, THE SIGMOID BEING BROUGHT OUT FOR COLOSTOMY.

FIG. 113. ABDOMINAL RESECTION OF THE SIGMOID OR RECTUM. 3. THE VASCULAR SUPPLY TO THE SIGMOID AND RECTUM EXPOSED.

containing the growth is now isolated and the mesentery examined for involved lymph structures.

The amount of gut to be resected is then determined and four clamps are placed, two on each side, at some distance from the growth. The diseased bowel is removed by cutting between the clamps. If sufficient bowel is left

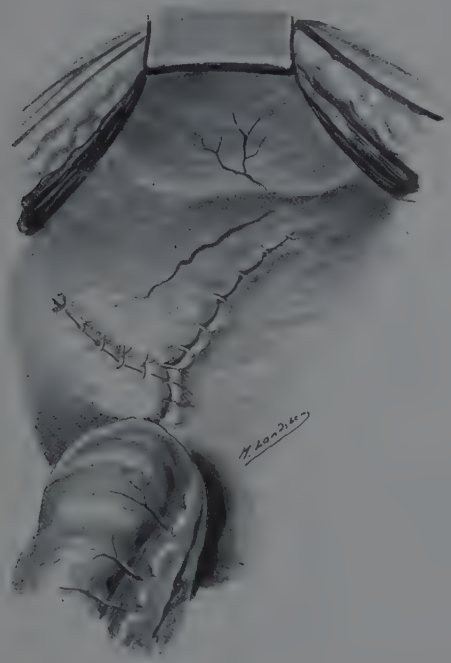

FIG. 115. ABDOMINAL RESECTION OF THE SIGMOID OR RECTUM. 5. PERITONEUM COMPLETELY CLOSED OVER.

after the resection for the proximal and distal limbs to overlap, each is closed by a purse-string suture and both are united by the usual methods of suture in lateral anastomosis. The latter is preferable to end-to-end union in this particular situation. If lateral union cannot be made without tension the outer leaf of the mesentery of the descending colon should be incised. Perhaps the ligaments supporting the splenic flexure may also be divided, thus

allowing the transverse colon to come down. The use of either method will facilitate anastomosis.

THE OPERATIVE TREATMENT OF CARCINOMATA LOCATED IN OTHER PARTS OF THE COLON. In cancer at the splenic flexure all attachments above and to the outer side of the splenic angle must be severed in order to permit freedom of access to the diseased area. A growth situated in the transverse colon can usually be excised without much difficulty, as that portion of the large intestine can readily be withdrawn from the abdominal cavity. Success-



FIG. 116. RESTORATION OF THE RECTOSIGMOID AFTER RESECTION OF THE RECTUM. I. THE HEALED COLOSTOMY WOUND.

ful removal of cancer located in the hepatic flexure is unusual as in this region there is no mesentery and adhesions form very early. Carcinoma of the cecum may be excised by removing the entire cecal angle. The peritoneum fixing the cecum and ascending colon to the posterior abdominal wall is severed and the involved gut freed together with the tissues of the iliac fossa. The ileocolic and cecal arteries are ligated as well as the right colic if there is involvement of the glands along the right ileocolic artery. After ligation of the right colic, it is necessary to remove most of the ascending colon which is supplied by it.

Clamps are applied to the colon and ileum and the entire cecal angle is cut away. The ileum may then be implanted into the side of the ascending colon (the opening of which has been closed) or an end-to-end anastomosis may be

FIG. 117. RESTORATION OF THE RECTOSIGMOID AFTER RESECTION OF THE RECTUM. 2. COLOSTOMY HAS BEEN EXCISED. MUMMERY TUBE TIED INTO THE SIGMOID STUMP.

made. If a large part of the ascending colon has been removed, the ileum may be implanted in the transverse colon.

In rare instances it is advisable to do a colectomy. A median vertical incision about 6 inches in length is made, having the umbilicus as its center.

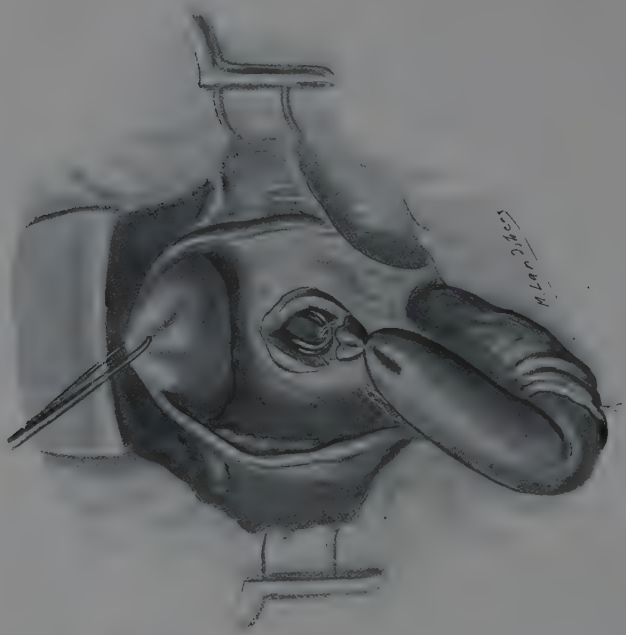

FIG. 119. RESTORATION OF THE RECTOSIGMOID AFTER RESECTION OF THE RECTUM. 4. SPONGE FORCEPS INSERTED IN THE RECTAL CANAL AND THROUGH THE RECTAL WALL. A STRING TIED TO THE MUMMERY TUBE IS GRASPED BY MEANS OF THE FORCEPS AND THE SIGMOID PULLED INTO THE RECTUM.

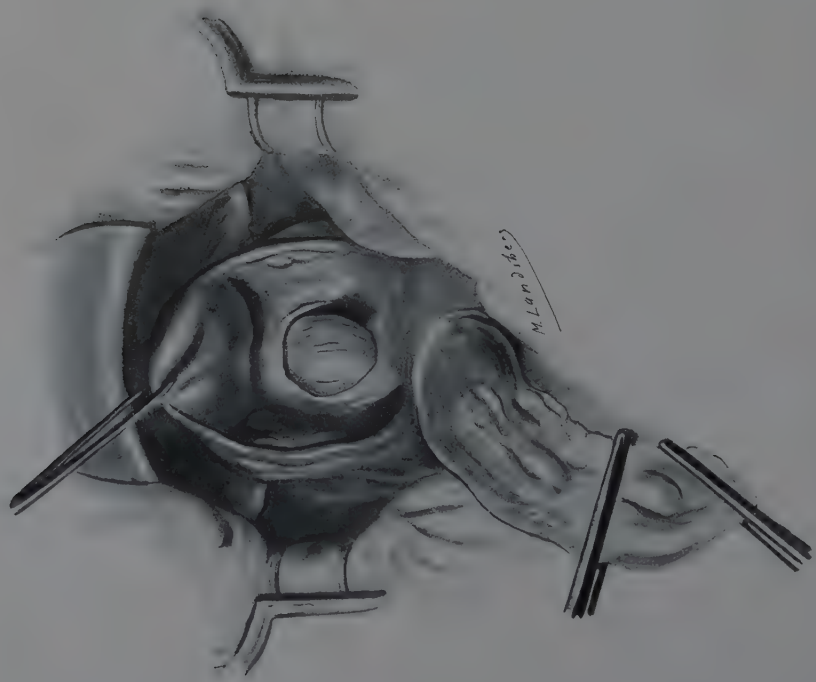

FIG. 118. RESTORATION OF THE RECTOSIGMOID AFTER RESECTION OF THE RECTUM. 3. EXPOSURE OF THE RECTAL STUMP.

The transverse colon is held up by an assistant and the middle colic artery tied about 1 inch from the junction of the bowel and mesentery. After the middle colic artery has been tied a fairly large slit can be made in the transverse mesocolon and the hand passed into the lesser cavity. With one hand in the lesser cavity the great omentum and gastrocolic omentum can be stripped over the colon. It may require two or three sutures to prevent hemorrhage but this part of the operation can be accomplished within a few

FIG. 120. RESTORATION OF THE RECTOSIGMOID AFTER RESECTION OF THE RECTUM (FEMALE). 5. RECTOSIGMOID ANASTOMOSIS CLOSED OFF BY FIXING THE UTERUS TO THE SIGMOID AND VISCERAL PERITONEUM, THUS PRODUCING A SURGICAL RETROVERSION. IN ORDER TO OVERCOME THIS PATHOLOGICAL CONDITION A VENTRAL SUSPENSION OF THE UTERUS IS MADE.

minutes and with very little trauma. With forceps and a long suture of iron-dyed linen the colon is gradually tied off. By passing a suture back and forth and tying a little at a time no raw edges are left and the colon can be removed within a very reasonable time. After the colon has been thoroughly freed from its attachment to the mesocolon, an anastomosis is made between the ileum and sigmoid. After the anastomosis has been made, the upper end of the sigmoid, at a point about 1 inch above the anastomosis, is turned in and the excessive colon removed.

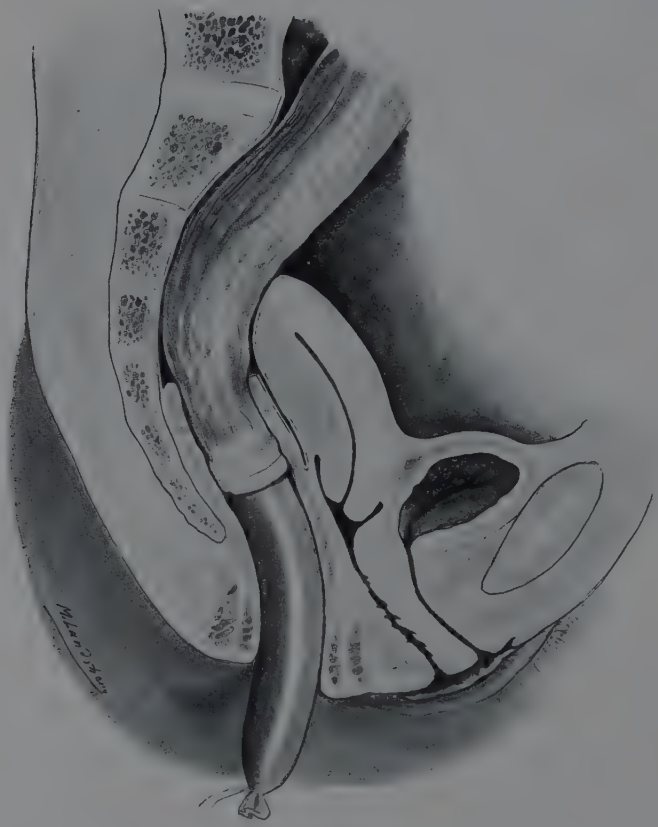

FIG. 121. RESTORATION OF THE RECTOSIGMOID AFTER RESECTION OF THE RECTUM. 6. THE COMPLETED OPERATION (SAGITTAL SECTION). NOTE THE SIGMOID STUMP INVAGINATED INTO THE RECTUM.

Chapter VI

THE EXCISION OF LYMPHATIC AREAS DRAINING MALIGNANT NEOPLASMS OF THE COLON AND RECTUM

Chapter VI

THE EXCISION OF LYMPHATIC AREAS DRAINING MALIGNANT NEOPLASMS OF THE COLON AND RECTUM

Every satisfactory method of operative treatment of malignant neoplasms of the colon and rectum must provide for the complete extirpation of the lymphatic area draining the portion of intestine involved. Operative conditions and care in gross pathological diagnosis will often determine the extent to which the procedures suggested can be carried out. For this reason the ideal procedures for lymphatic extirpation are given but the surgeon may be compelled to modify these in individual cases. We may arbitrarily consider the operative treatment of malignant neoplasms of the colon and rectum from two aspects: (1) General considerations involved in resection of the intestine for carcinoma and (2) Excision of the lymphatic area. The former may be successfully carried out by any number of well-recognized methods. The latter requires an intimate knowledge of the gross and microscopic lymphatic distribution and is by far the most important factor responsible for the majority of permanent cures. By "lymphatic area" we refer to all of the primary lymph-nodes and lymphatic vessels draining a diseased area together with the tissues in which the vessels lie.*

The Lymphatic Area of the Ileocecal Region. *Anatomical Considerations.* The abdominal lymph-vessels are closely associated with the arteries and veins. Of these, the ileocolic artery is concerned with the blood supply of the ileocecal region. It arises from the superior mesenteric artery near the third part of the duodenum, leaves the mesentery at the

* The material for the above vascular and lymphatic description was obtained for the most part from the published investigations of Jamieson and Dobson.[48]

lower border of that portion of the intestine and continues downwards and outwards behind the parietal peritoneum towards the ileocecal angle. At a point about 2.5 cm. distant from the angle the artery breaks up into the appendicular, anterior and posterior ileocolic, ileal and colic branches. It also gives off a right colic branch but this vessel may arise directly from the superior mesenteric artery. The ileocolic artery is surrounded along its entire course by a chain of ten to twenty lymph-nodes continuous with the nodes around the trunk of the superior mesenteric artery. The remaining nodes are placed in relationship with the terminal branches of the ileocolic artery:

(1) The anterior ileocolic nodes are usually about three in number and lie in the ileocolic fold close to the wall of the cecum. The highest node is usually the largest.

(2) The posterior ileocolic nodes lie for the most part in the angle between the ileum and cecum but some are situated on the posterior surface of the cecum in the groove between this portion of the colon and ileum. One node may occasionally be seen between the layers of the mesoappendix near the cecum.

(3) The appendicular node is located between the layers of the mesoappendix at or near the free border, sometimes lying upon the appendicular artery.

(4) The ileal nodes are intimately associated with the ileal branch of the ileocolic artery.

(5) The right colic nodes lie along the inner border of the ascending colon and in close contact with it. They are associated with the colic branch of the ileocolic and branches of the right colic arteries.

Lymphatic vessels from any part of the appendix run past the nodes in the immediate vicinity of the organ to those of the main ileocolic chain and may even reach the upper nodes of this chain, which lie on the duodenum.

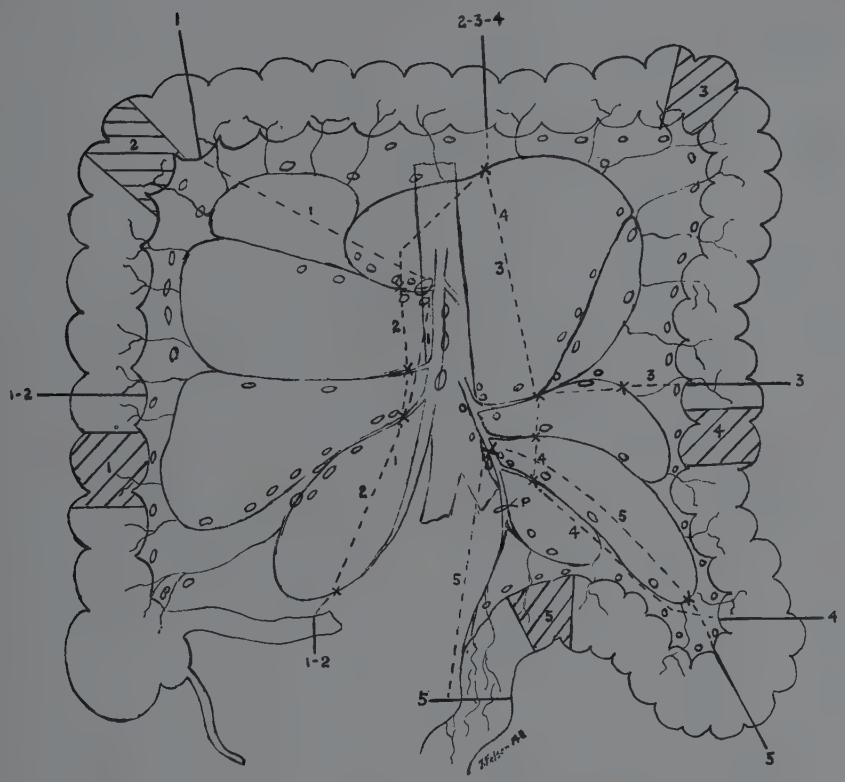

FIG. 122. (SAME AS FIG. 10). INTESTINAL RESECTION FOR CARCINOMA OF THE COLON OR RECTUM WITH COMPLETE EXCISION OF THE LYMPHATIC DRAINAGE AREA. (SOLID LINES INDICATE GUT RESECTION, INTERRUPTED LINES SIGNIFY LYMPHATIC AREA TO BE EXCISED): 1. MALIGNANCY OF THE ASCENDING COLON, HEPATIC FLEXURE OR FIRST PART OF THE TRANSVERSE COLON. 2. MALIGNANCY AT ANY POINT BETWEEN THE HEPATIC FLEXURE AND MIDDLE OF THE TRANSVERSE COLON. NOTE: TWO POINTS FOR RESECTION OF THE GUT ARE SHOWN FOR BOTH 1 AND 2. THE WIDER AREAS OF RESECTION SHOULD BE PRACTICED WHEREVER POSSIBLE. 3. MALIGNANCY OF THE SPLENIC FLEXURE. 4. MALIGNANCY OF THE DESCENDING COLON. 5. MALIGNANCY OF THE LOWER SIGMOID AND FIRST PART OF THE RECTUM (FELSEN).

Thus any node of the ileocolic group may be a primary node for the appendicular lymphatics.

Most of the lymphatic vessels from the body and base of the cecum end in the anterior and posterior ileocolic nodes. Some of these vessels, however, together with those from the apex of the organ, frequently pass these nodes to reach the high nodes of the ileocolic chain. Some lymphatic vessels of the cecum may ascend in the mesoappendix and freely communicate with the vessels of the appendix.

Surgical Considerations. It is possible to remove all nodes and vessels draining the cecum. The method of procedure is as follows: The peritoneum over the third part of the duodenum is divided and the ileocolic vessels located. The vessels are exposed and cleaned of all surrounding adipose tissue and nodes by gauze stripping. Care is taken not to injure the duodenum. The artery and vein are divided between ligatures, the former being divided near the superior mesenteric trunk. This procedure cuts off the blood supply of the ascending colon. The peritoneum is then divided from the duodenum to a point on the colon where the resection will be made. Any necessary ligations of the branches of the middle colic and right colic are carried out. The peritoneum of the anterior layer of the mesentery is divided in a line reaching obliquely downwards to the ileum. The ileocolic and right colic vessels and nodes, adipose tissue and overlying peritoneum are stripped off as far as the ileum and cecum and outwards to the colon. Care must be taken not to injure the ureter. The cecum is lifted up and peritoneal reflections from it as well as the outer side of the colon are divided. Part of the posterior layer of the mesentery of the small intestine is also cut. The cecum and appendix, the whole of the ascending colon and terminal portion of the ileum, together with the ileocolic and right colic vessels and nodes, are now free. The colon and ileum are divided at previously selected points and the entire mass is removed from the abdomen. The ileum should not be divided closer than

15 cm. from the ileocecal valve in order to conserve the ileocolic artery supplying the cut end.

It will be noted that in the above procedure the cecum, appendix, ascending colon and terminal portion of the ileum are removed together with the entire ileocolic chain of lymph-nodes and intervening tissue containing the lymph vessels.

Lymphatic Area of the Colon. *Anatomical Considerations.* The lymphatics of the remainder of the colon are also intimately associated with the vascular distribution. The superior mesenteric artery supplies three branches to the large intestine, the ileocolic, right colic and middle colic. The first has already been described. The right colic artery most often is a direct branch of the superior mesenteric. Less often it arises from the ileocolic and occasionally may be represented as a branch of the middle colic and ileocolic. The middle colic artery comes off the superior mesenteric on a level with the lower border of the pancreas and passes downwards and outwards across the superior mesenteric vein to enter the transverse mesocolon, between whose leaves it runs downwards, forwards, and to the right towards the hepatic flexure. About midway in its course in the mesocolon it divides into two branches which diverge and subdivide again close to the colon. These four secondary branches form three arcades: (1) With the ileocolic or right colic under the hepatic flexure; (2) under the right end of the transverse colon; (3) with the left colic artery. This arcade is very long and lies close to the gut along the distal two-thirds of the transverse colon and encloses in its concavity a large area of mesocolon devoid of any large blood-vessels. The middle colic artery may merely divide near the hepatic flexure into two branches forming two arcades: one with the ileocolic or right colic, the other with the left colic. Here there is no middle arcade. The middle colic artery therefore supplies part of the ascending colon, the hepatic flexure, and the right and middle thirds of the transverse colon.

Secondary arcades, if present, are usually found under the hepatic flexure. Accessory middle colic arteries may occasionally be encountered.

The inferior mesenteric artery arises from the abdominal aorta about 5 cm. above its bifurcation. It descends to the left in front of the aorta, the left psoas muscle and left common iliac artery to enter the mesorectum as the superior hemorrhoidal artery. It is accompanied in its lower part by the inferior mesenteric vein. The left spermatic vessels and ureter lie just to the outer side. The inferior mesenteric artery is covered only by peritoneum and subperitoneal tissue and is surrounded by a sympathetic plexus. The sigmoid and left colic branches are given off from the outer side. The left colic arises just below the duodenum and runs outward toward the lower pole of the left kidney to meet the inferior mesenteric vein and turn upwards towards the splenic flexure. Near the hilus of the kidney the vein turns inwards across the artery. Beyond this point the artery is paralleled by the left colic vein. At the lower border of the pancreas it curves forward into the transverse mesocolon and terminates by dividing into two branches at the splenic flexure. The right branch forms an arcade with the middle colic lying under the transverse colon; the left bends downward to form an arcade with the highest sigmoid artery or with its own branches. The highest sigmoid artery may arise from the left colic.

The sigmoid arteries arise from the inferior mesenteric artery or the left colic or both. The highest branch runs outward between the lower pole of the kidney and iliac crest to supply the lower end of the descending colon and part of the sigmoid. The remaining sigmoid arteries (one to three) descend in front of the psoas to enter the mesosigmoid. The lowest sigmoid artery may be found just to the outer side of the common iliac artery. The individual sigmoid arteries form anastomosing arcades in the mesosigmoid. The lowest sigmoid and superior hemorrhoidal arteries do not form an arcade but are diverging limbs of the inferior mesenteric artery. In order to maintain an

adequate blood supply to the rectosigmoidal area a ligature would therefore be applied above the point of divergence (see Fig. 9).

The superior hemorrhoidal vein is a continuation of the inferior mesenteric. Ascending to the outer side of the artery for approximately 5 cm. it crosses the sigmoid arteries and turns to join the left colic artery which it accompanies for a distance of 3 to 5 cm. It then returns to and crosses the superior hemorrhoidal artery to form an arch below the pancreas beneath which the vein finally disappears to join the splenic or superior hemorrhoidal.

The lymph-nodes draining the colon are scattered along the course of the blood-vessels and may be divided into: (1) The ileocolic chain; (2) the middle colic chain; (3) the left colic chain; (4) the inferior mesenteric chain.

Jamieson and Dobson have made a very practical subdivision of each chain into these groups: (1) Epicolic; (2) paracolic; (3) intermediate; (4) main.

The epicolic nodes lie on the intestinal wall underneath the peritoneum and in the appendices epiploicae. They are most numerous in the sigmoid flexure.

The paracolic nodes lie along the inner margin of the intestine from the ileocecal region to the rectum and are usually found between the arterial arcades and intestine or on the arcades.

The intermediate groups of nodes are found about the stem of the middle colic, left colic and sigmoid arteries midway between their points of origin and the intestine. In the case of the middle colic artery most of the nodes are grouped about the primary bifurcation. On the left colic artery the largest mass of nodes is to be found just above the crossing of the inferior mesenteric vein. On the upper sigmoid arteries the intermediate nodes are retroperitoneal, lying between the iliac crest and the lower pole of the kidney. On the lower sigmoid arteries they lie in the base of the mesosigmoid. The intermediate lymph-node groups receive their tributaries from the paracolic nodes and some vessels direct from the intestine.

The main groups are distributed as follows: The main middle colic group lies on the middle colic artery as it enters the transverse mesocolon and receives tributaries from the intermediate and paracolic nodes or even from the intestine direct. The main left colic group lies upon the horizontal part of the artery, near its origin, and receives tributaries from the left colic intermediate and paracolic nodes. Other nodes of the main left colic group are to be found on the terminal portion of the inferior mesenteric vein and their lymphatics communicate with the left colic intermediate, superior mesenteric, celiac and lumbar lymph-nodes. The inferior mesenteric main group is distributed around the stem of the artery as far as the main left colic group with which it joins and becomes continuous with the lumbar glands. The upper part of the inferior mesenteric main group receives paracolic and intermediate lymphatics as well as some direct vessels. The lower part receives tributaries from the paracolic glands along the lowest part of the sigmoid flexure as well as some direct vessels. The lowest part of this group is almost in contact with the rectosigmoidal junction and receives most of the direct vessels therefrom. It is important to note that the inferior mesenteric main group sends many efferent vessels into the lumbar nodes so that the former may be regarded as a lateral extension of the latter. The inferior mesenteric main group receives tributaries from the intermediate group on the sigmoid arteries, paracolic nodes and some direct vessels from the sigmoid flexure.

To summarize we may state the following: The lymphatic vessels arising in the intestinal coats, as described in a previous section, leave the colon chiefly along the entering blood vessels. Some are interrupted immediately in the epicolic nodes lying in the appendices epiploicae or on the sacculi. The efferent vessels from these nodes, together with uninterrupted lymphatics from the colon, proceed inwards to end for the most part in the paracolic nodes. Some vessels, however, avoid the paracolic group to reach

the intermediate nodes together with the epicolic and paracolic efferent vessels. Occasionally these vessels run directly to the main group. It will also be seen from the above description that direct vessels to the main groups from the hepatic and sigmoid flexures are more common than from elsewhere on the colon. From the splenic flexure the lymphatic vessels never get beyond the intermediate group. The lymphatics with very few exceptions accompany the blood-vessels so that avascular areas are comparatively free. From the left third of the transverse colon few vessels reach even the intermediate left colic group as most are interrupted by the paracolic nodes. From the middle third of the transverse colon no vessels reach the intermediate middle colic group. From the left half or two-thirds of the transverse colon, moreover, some vessels run into the gastrocolic omentum to reach the nodes at the hilus of the spleen. Jamieson and Dobson, using Gerota's injection method, noted that a suspension of Prussian blue in turpentine and ether, injected into the nodes lying along the left colic artery and arched portion of the mesenteric vein, eventually appeared in the terminal portion of the inferior mesenteric vein and in the superior mesenteric and splenic veins. This seems to be quite conclusive evidence of a communication between the lymphatic and venous systems in the abdomen.

In those portions of the colon supplied by long arterial arcades the paracolic glands at some distance from the diseased area may become involved. The reason for this is that lymphatic vessels emerging from the colon opposite the center of an arcade must travel for some distance parallel to the intestine before reaching an arterial trunk along which they pass to reach the main groups. It is therefore the best procedure to remove the paracolic nodes for some distance on either side of a malignant growth, together with a considerable portion of the intestine and the lymphatics connecting them. This is especially true in the transverse colon. It may be readily understood from the above descriptions that complete extirpation

of the lymphatic area is not always possible (e.g., splenic flexure). As a general rule, local and general conditions permitting, every attempt should be made to excise the entire lymphatic area regardless of the presence or absence of enlarged lymph-nodes.

Surgical Considerations. (1) Malignancy of the ascending colon, hepatic flexure or first part of the transverse colon. The primary lymphatic area comprises the epicolic and paracolic nodes, the intermediate and main group nodes of the middle colic chain. The surgical procedure will therefore be to tie the middle colic artery near its origin and remove the mesocolon from this point up to the bowel. This cuts off the blood supply to the upper part of the ascending colon and two-thirds of the transverse colon. It thus becomes necessary to excise that portion of intestine between the middle of the ascending colon and the junction of the middle and distal thirds of the transverse colon. Anastomosis may then be effected between the ileum and sigmoid (after closure of both stumps). Or we may include the terminal ileum, cecum and lower part of the ascending colon in the portion of intestine removed. Ileum is then anastomosed to the remaining portion of the transverse colon.

(2) Malignancy of the middle of the transverse colon. Most of the lymphatics of this region run only as far as the paracolic nodes. It is therefore necessary to remove only as much colon on either side of the growth as will permit a satisfactory anastomosis.

(3) Malignancy of the splenic flexure. Most of the lymphatics from this region pass into the epicolic and paracolic nodes. Some vessels may run directly to the splenic nodes. The lymphatic area to be excised will therefore include the epicolic, paracolic and the intermediate nodes lying on the branches of the left colic artery and also the nodes at the hilus of the spleen. The last-mentioned nodes can hardly be effectively excised. Operative efforts must therefore be practically limited to the left colic chain. The left colic

artery and vein are tied as they leave the inferior mesenteric vein. The bowel is freed by incising the peritoneum to the outer side of the descending colon and splenic flexure. The peritoneum and subperitoneal tissues containing the nodes and vessels from the posterior abdominal wall are stripped off. From the point of ligature of the left colic artery the peritoneum is incised upwards to a selected point on the transverse colon (depending upon how much of the transverse colon is supplied by the middle colic artery. This is usually the junction of the middle and distal thirds of the transverse colon. The peritoneal incision is continued downward and outward to the lower part of the descending colon. The gut is divided as shown in the diagram and an end-to-end anastomosis effected.

(4) Malignancy of the descending colon. The lymphatic area includes the epicolic and paracolic nodes as well as the intermediate nodes on the branches of the left colic artery and those on the first sigmoid. Some lymphatics may run to the nodes at the hilus of the spleen. The left colic artery is tied as it leaves the inferior mesenteric vein and the first sigmoid artery is ligated near its origin. The remainder of the operation is the same as for the splenic flexure except that the colon will be divided in the first part of the sigmoid flexure.

(5) Malignancy of the upper and middle sigmoid. This portion of the colon is drained by the epicolic and paracolic nodes, the intermediate nodes on the sigmoid arteries and the main group on the inferior mesenteric artery. The inferior mesenteric artery and vein are exposed, the peritoneum over them divided and as many nodes of the main group as possible stripped off from the origin of the left colic down to the lowest sigmoid branches. The sigmoid arteries are tied at their origin, preserving, if possible, the lowest branch. The descending colon is then freed and divided above at its junction with the sigmoid flexure and below in the lower part of the sigmoid. This procedure removes most of the mesosigmoid including the intermediate,

paracolic and epiploic nodes and most of the main group draining this part of the sigmoid. An anastomosis is then made between the descending colon and sigmoid stumps. If the lowest sigmoid artery has been ligated the colon must be divided below the pelvic brim due to lack of anastomosis between the lowest sigmoid and superior hemorrhoidal arteries.

(6) Malignancy of the lower sigmoid and first part of the rectum. The lower portion of the sigmoid flexure is drained by the epicolic and paracolic nodes as well as the intermediate and main groups lying about the inferior mesenteric artery not higher than the origin of the left colic. The upper incision is made from this point to a point on the sigmoid well beyond the limits of the growth. Anastomosis between the intact left colic and sigmoid arteries insures the blood supply of the upper sigmoid. The lower incision is made from just below the origin of the left colic artery to a point on the rectum determined by the blood supply (middle and inferior hemorrhoidal and sacral arteries).

The inferior mesenteric artery and vein are exposed and ligated just below the origin of the left colic artery. A long incision is then made through the peritoneum on the outer side of the mesorectum and mesosigmoid. The descending colon and sigmoid are then stripped off towards the midline. The ureter and spermatic vessels are not to be injured. The mesosigmoid is then divided from the point of ligature of the inferior mesenteric to about the middle of the sigmoid flexure while at the same time endeavoring to preserve the secondary sigmoid arches. The peritoneum on the inner side of the artery is divided down to the mesorectum. The entire mass is then stripped off forwards from the hollow of the sacrum; the sigmoid is divided at the middle of the flexure and at the upper part of the rectum.

The above procedure removes the lower half of the sigmoid and upper part of the rectum, most of the inferior mesenteric vessels with accompanying nodes and lymphatics and the surrounding subperitoneal tissue. The point

of the rectal incision is determined by releasing the clamps to see if the cut end bleeds freely (means preservation of the middle and inferior hemorrhoidal blood supply). The operation may be terminated by a colostomy. At some future time a rectosigmoidal anastomosis may be made by the invagination method (see Fig. 119).

(7) Lymphatic supply of the rectum and anus. Poirier and Cuneo[93] divide the lymphatic distribution to the anus and rectum according to the mode of origin into: (*a*) the mucocutaneous network, and (*b*) network of the muscular coat. Each may, in turn, be subdivided into inferior, middle and superior regions.

The inferior mucocutaneous region corresponds to the skin at the anal margin. This lymphatic network consists of two superimposed layers, one embedded in the skin and the other subcutaneous. The middle mucocutaneous region corresponds to the skin-bordered area of the anus, the upper limit being formed by the white line. These lymphatics run in a vertical direction. The superior mucocutaneous lymphatic region corresponds to the anal and rectal mucosa. In the former the lymphatic network is quite poor while the latter is extremely rich, being made up of superimposed mucous and submucous layers.

The muscular lymphatics unite with the collecting trunks from the mucocutaneous region.

The vessels arising in the inferior mucocutaneous region form three to five trunks on each side and run upward towards the inguinal region coursing along the internal aspect of the thigh, over the perineum or perineocrural fold. They terminate in the superficial inguinal nodes.

The lymphatics of the middle region may be divided into the indirect and direct. The former ascend in the columns of Morgagni and terminate in the network of the rectal mucosa. The direct efferents perforate the rectal wall to terminate as follows:

Some perforate the rectal wall just above the levator ani, ascend on the lateral rectal wall, traverse the pararectal nodes to join the lymphatics coming from the superior region to end in the nodes of the mesorectum. Others accompany the middle hemorrhoidal artery to terminate in a node situated on that vessel at some distance from the lateral wall of the pelvis. The remaining efferents emerge beneath the insertion of the levator ani and follow the inferior hemorrhoidal vessels. Very often, however, these lymphatics merely run a short distance in the adipose tissue of the ischiorectal fossa, perforate the levator ani and terminate in a node situated at the origin of the internal pudic artery.

The lymphatics of the superior region perforate the muscular coat of the rectum at various levels and run obliquely upward and backward to reach the nodes of the mesorectum. In their course they traverse the pararectal (anorectal) nodes which vary in number from four to seven, being placed between the muscular and serous coats of the rectum. They are usually found in the ampullar region. The nodes in the mesorectum are grouped about the superior hemorrhoidal artery and are always of considerable size.

Chapter VII

THE TREATMENT OF CARCINOMATA OF THE COLON AND RECTUM BY NON-SURGICAL AND PALLIATIVE PROCEDURES

Chapter VII

THE TREATMENT OF CARCINOMATA OF THE COLON AND RECTUM BY NON-SURGICAL AND PALLIATIVE PROCEDURES

A. The Roentgen Ray and Radium

The advances made in recent years in the therapeutic use of the roentgen ray have been applied to carcinomata of the large intestine. Erlanger and others have claimed permanent cures in some cases. Bowing and Anderson[10] state that rectal growths are but slightly affected by the roentgen ray. They state that even the results with the higher voltages (200,000 or more) have been disappointing. Metastatic nodules and lymphatic involvement, on the other hand, are more susceptible, being inhibited from further growth or actually destroyed. Bowing, working in the Mayo Clinic, uses a 23 cm. skin-to-target distance, a filter of 3 or 4 mm. of aluminum, a spark gap of 23 to 24 cm. between blunt points and a current of 5 ma. (milliamperes) sent through a broad focus standard Coolidge tube for 5 to 6 min. The rays are directed to the pelvis through nine portals of entry (four anterior, four posterior, one perineal). In a later technique, homogeneous radiation of short wave lengths is secured by means of copper filtration and higher voltage. May[73] advises a preliminary laparotomy with the establishment of an artificial anus in the sigmoid so that the operator and roentgenologist may determine the extent of the carcinomatous involvement. About two weeks later treatment, planned according to conditions found at the time of operation, is carried out. Bundles of rays, as hard as possible, are directed at the tumor and its adjoining lymphatics. He uses two posterior fields (rays directed obliquely in the posterior axillary line), two abdominal fields (obliquely in the anterior axillary line) and a perineal. The last receives

only 80 per cent of the erythema dose because of the sensitiveness of the mucosa of the anus and vagina.

Radium C with its alpha, beta and gamma rays is the therapeutic principle used in the treatment of carcinomata by means of radium. It may be in the form of a salt or emanations prepared by the Duane series of mercury pumps. Every avenue of approach is utilized in order to thoroughly radiate all portions of involved tissue. The radium may be inserted by means of needle points directly into the diseased area. The emanation may be applied directly to the surface of the diseased area, or finally, the so-called external or deep radiation method may be used. Quick[96] uses a combination of buried emanation, filtered radium externally and, if necessary, surgical exposure. Depending upon the size and distribution of the tumor, the dosage of buried emanation varies from 10–40 mc. (millicuries), or a total of 1,320–5,280 mc. hours. In the case of annular growths 0.5 mm. platinum tubes in a string are arranged end-to-end in a small rubber tube which, in turn, is encased in a larger rectal tube with a metal end. A sufficient number of tubes is used to cover the limits of the growth. With this technique Quick has been able to use a dosage of 500 mc. hours per tube without causing any severe reaction. For carcinoma localized to one segment of the rectal wall he uses a solid rubber rectal bougie grooved to accommodate the required number of platinum tubes. In carcinoma of the anterior rectal wall in females, lead or brass plaques of 2 mm. thickness and about 4 sq. cm. in surface area are used as filters for radium applied through the vagina. The plaques are separated from the posterior vaginal wall by a distance of approximately 1 cm. In this way 800 mc. per hour may be given in addition to that within the rectum. When necessary, radiation may be affected through the sacral or left lower quadrant areas. Here a 70 sq. cm. radium pack filtered by 2 mm. of brass and placed at a distance of 10 cm. from the skin is used, giving a dosage of 20,000 mc. hours.

Kelly and Ward[52] implant needles carrying the emanation directly into the tumor mass by means of the proctoscope or sigmoidoscope. The needles are left in place until they slough out. Applied in this way 1 mc. of radium emanation is said to destroy 1 c.c. of tumor tissue. Direct application to the diseased area is secured by means of little gauze carriers with pockets for the radium tubes. Lead filters are used and the adjacent normal tissue properly protected. Deep radiation is carried out by means of thick lead cylinders suspended over the patient by a car and crane. In this way the rays may be focused in any direction. The sacral and coccygeal areas, perineum and, in extensive pelvic involvement, the groin and suprapubic regions are used.

The effects of radiation may be summarized as follows. The mucosa as a result of irritation becomes erythematous and edematous. There is a profuse discharge of mucus. At a later stage there may be an increase in the mucus discharge accompanied by some bleeding. A localized peritonitis or perineal abscess may form. Ulcers are occasionally seen in cases of carcinoma of the rectum or colon treated by *x*-ray or radium, probably as a result of overdosage. These ulcers are very slow in healing. They are also prone to occur on unprotected healthy surfaces. Among the systemic effects the following have been noted: anorexia, nausea, vomiting, weakness, urgency, frequency, painful urination, fever and general toxemia.

B. Palliative Treatment of Carcinomata of the Colon and Rectum

A great number of patients apply for medical attention too late for radical surgical treatment. For this great class of unfortunates the physician's or surgeon's duty lies in making them as comfortable as possible and prolonging their lives. Several simple measures are available depending upon existing conditions.

(1) Diet. Our aim should be to furnish easily assimilated foods of high caloric value, non-irritating and small in bulk, with a minimum of post-

digestive debris. Milk, eggs, beef juice, boiled fruits and concentrated strained gruels are examples of such foods.

(2) Drugs. The underlying principles should be to strengthen the patient (tonics), keep the stools soft and to effect narcosis when necessary. As a general tonic, tincture of nux vomica is of value. To produce soft stools, olive oil, liquid petrolatum or cathartics may be used. For narcosis, morphine and codeine are invaluable. Potassium permanganate irrigations will usually take care of obnoxious discharges and odors. Injections of colloidal selenium have been used extensively abroad without much success.

(3) Mechanical Measures. For impaction of feces above a growth, water, glycerine or oil enemata may be tried. If unsuccessful, a colonic tube, catheter, scoop or even the finger may be used.

(4) Surgical Procedures. One of several procedures may be used depending upon the condition encountered.

(*a*) *Colostomy*, performed early, has often prolonged life for many years in apparent comfort. The lower bowel should be frequently irrigated and proper care taken of the colostomy opening.

(*b*) *Curettage.* This procedure is often valuable when the tumor is located in the rectum, on the posterior or lateral walls, below the peritoneal reflection. There is great danger of injuring the urethra, bladder, or, in women, of opening the peritoneal cavity. The operation is performed under anesthesia using a blunt curette with or without the cautery. Bleeding is controlled by hot irrigations and the bowel being packed with vaseline gauze except for a small channel for the rectal tube. The packing is removed at the end of thirty-six hours. This may be followed by the application of radium and the entire procedure repeated as often as necessary.

(*c*) *Diathermy.* In this method a high frequency current of low potential is used, the effect being a coagulation necrosis.

Chapter VIII

THE RESULTS OF VARIOUS METHODS OF TREATMENT OF CARCINOMATA OF THE COLON AND RECTUM

Chapter VIII

THE RESULTS OF VARIOUS METHODS OF TREATMENT OF CARCINOMATA OF THE COLON AND RECTUM

Surgical Procedures. The following table summarizes the operative results obtained by various surgeons.

Table V

POSTOPERATIVE RESULTS IN THE TREATMENT OF CARCINOMATA OF THE RECTUM

Surgeon or Institution	No. of cases	Mortality, per cent	Longevity, per cent			Remarks
			1–3	3–5	Over 5 yrs.	
Mayo Clinic[96]	430	15.0	....	33.0	28.5	Excepting cases operated upon less than 3 yrs. before
Kuttner[59]	316	9.0	....	32.5	21.6	16.4 per cent over 8 yrs.
Collected records by Pennington[86]	966	....	....	22.0	....	12.8 per cent over 10 yrs.
Lynch[67]	335	16.0	25.7	16.4	12.8	Radical excision
Hartman[40]	1,665	15.8				
Hartwell[41]	....	26.0				
Tuttle[117]	100	13.0	30.0	26.0	21.0	15 per cent for 5–10 yrs.
Zinner[126]	201	16.8	....	....	....	6 per cent for 10–16 yrs.

Majerus[71] reports the following results in a series of operative cases with carcinomata located in other parts of the large intestine:

Table VI

POSTOPERATIVE RESULTS IN THE TREATMENT OF TUMORS OF THE COLON (MAJERUS)

Location of tumor	Cases	Deaths	Mortality, per cent
Cecum to hepatic flexure	24	3	12.5
Transverse colon	6	1	16.6
Splenic flexure and ascending colon	11	5	45.5
Sigmoid flexure	19	7	36.8
	60	16	26.7

It is very misleading to place credence in any statistics of results following operative removal of carcinomata of the large intestine (especially the rectum) without a clear understanding of the factors governing mortality in this condition. We shall attempt to enumerate a few of the important factors:

(1) The mortality depends upon the type of operation, and the judgment and skill of the operator. Tuttle compiled an interesting table indicating the operative results obtained in rectal carcinoma with various types of procedure. Mummery and Moynihan show similar variations in the figures given in their publications.

(2) One can never predict the extent of involvement by the size of the visible or palpable tumor. Some very small carcinomata show extensive lymphatic involvement and even metastatic deposits in the liver.

(3) There seem to be varieties of virulence in carcinomata of the colon or rectum without any discernible differences in histopathological structure.

(4) Unoperated cases of carcinoma of the rectum, proved by histological examination, have often outlived all expectations.

(5) Patients regarded as good risks by skilled operators often fail to survive the same operative procedure borne well by admittedly poor risks. The uncertain factors of individual resistance to tissue trauma and shock play an important rôle in all radical resections.

(6) Some surgeons accept patients in late stages of the disease in the hope that one life unexpectedly saved more than compensates for several premature deaths.

(7) There is no definite criterion for judging the permanency of a cure. As the late Dr. Tuttle has expressed it: "There is no period at which cancer may not recur." If statistics were collected for cases diagnosed as carcinoma but left entirely alone or with colostomy only, the longevity period might compare favorably with the statistics of some surgeons.

TABLE VII

POSTOPERATIVE RESULTS IN THE TREATMENT OF RECTAL CARCINOMA BY THE USE OF VARIOUS METHODS (TUTTLE)

Method	No. of cases	Mortality, per cent
Kraske	6	33
Bone flap	25	16
Perineal	40	5
Vaginal	3	0
Combined operation	8	37.5
Abdominal	9	11
Local excision	5	0
Intrarectal resection	1	0
Curettage and electrocautery	3	0

RADIATION. Following are the figures given in the more recent publications of radiologists interested in this field:

TABLE VIII

RESULTS OF RADIOTHERAPY OF CARCINOMA OF THE COLON AND RECTUM

Radiologist or Institution	Number of cases	Cured, per cent	Longevity period, per cent			Remarks
			1–3	3–5	Over 5 yrs.	
Kelly and Ward[52]	200	11	..		7*	
May and Holfelder[73] (Schneider's Clinic)	51	..	..	26.3	..	26.3 per cent represents two and one-half years or more
Quick[96]	161	..	..	....	..	All advanced cases. 8 per cent entirely free for four months to four years

* Fourteen out of a total of 22 cases. Table IX in Kelly and Ward's article shows only 13 instead of 14 cases as stated in the text.

Improvement under radium is usually indicated by fibrosis of the tumor mass and diminution in the size of the growth. Bleeding stops, any discharge that may be present decreases, pain is alleviated and septic absorption lessened. Radiation in the treatment of epithelioma of the anus has proved more useful than in rectal carcinoma.

One of our patients (4577, 1203) had received intensive treatment with radium for a period of two and a half years preceding operation. At the end of this time there was found an actively growing adenocarcinoma of the rectum with extensive fibrosis.

The following table (Table IX) gives a concise summary of the causes of death in a series of cases of carcinoma of the rectum as reported by Tuttle, Lynch and Zinner.

TABLE IX

CAUSES OF DEATH FOLLOWING THE SURGICAL TREATMENT OF CARCINOMA OF THE RECTUM

Tuttle (13 deaths in series of 100 operative cases):

5—Infection
2—Shock
2—Embolism
1—Proliferating ulcers of the stomach
1—Sloughing sigmoid
1—Pneumonia
1—Secondary hemorrhage

Lynch (last 10 deaths of known etiology in series of 100 operative cases):

6—Infection
1—Paralytic ileus
3—Shock

Zinner (34 deaths in series of 201 operative cases):

13—Peritonitis
9—Sepsis
5—Pneumonia
2—Infection of the genitourinary system
1—Collapse
1—Pulmonary embolus
1—Marasmus
1—Hemorrhage
1—Uremia

Conclusions. An understanding of the anatomical and pathological conditions underlying epithelial tumors of the colon and rectum as herein presented is necessary for a true appreciation of the operative difficulties involved in treatment.

The great lesson that stands out before every experienced surgeon and pathologist dealing with carcinomata of the colon and rectum is early diagnosis with early radical operative interference. A small carcinoma usually means an early localized lesion. The exceptions occur with sufficient rarity to warrant no departure from this maxim.

Chapter IX

OTHER TYPES OF PRIMARY NEOPLASMS OF THE COLON AND RECTUM

Chapter IX

OTHER TYPES OF PRIMARY NEOPLASMS OF THE COLON AND RECTUM

A. Lymphoblastoma (Lymphosarcoma)

A very useful classification of tumors arising in lymphoid tissue has been offered by Ewing. A great deal of confusion in particular exists as to one type of tumor in arising in lymphoid tissue—the sarcoma. According to the author aforementioned there are three elements in lymphoid tissues capable of giving rise to tumors: (1) Lymphocytes, giving rise to the lymphocytoma as found associated with simple lymphoma, tuberculous lymphoma, lymphatic leucemia, pseudoleucemia and malignant lymphocytoma. (2) Reticulum cells of the follicles and pulp, the basis of large round-cell hyperplasia or neoplasia, as found in granuloma malignum, myeloid leucemia, Hodgkin's disease and large cell lymphosarcoma. (3) Endothelial cells of the pulp and cavernous sinuses, giving rise to endothelial hyperplasia or neoplasia as seen in the endothelial hyperplasia of tuberculosis and endothelioma.

FIG. 123. LYMPHOSARCOMATOUS DEPOSIT IN THE INTESTINAL WALL. SPECIMEN 522½.

The close relationship, however, between reticular cells and lymphocytes as well as reticular and endothelial cells and the possibility of transformation of one to the other militates against the aforementioned classification. Mallory includes under the lymphoblastomas neoplastic lymphoid formation associated with lymphosarcoma, lymphoma, lymphocytoma and lymphatic leucemia as well as most so-called "round-cell sarcomata."

The earliest papers on the subject of intestinal sarcoma were written by A. Debrunner[24] (1883), E. Pick[91] (1884), G. Newton Pitt[92] (1889), Ludwig Orth[83] (1890), M. Baltzer[3] (1892), and Smoler[105] (1898). A very careful study of sarcoma of the small intestine was made by Libman (1900) in which he reviewed all of the medical literature to date. Blauel[7] (1900) described sarcoma of the colon. In 1901 Jopson and White[50] made their excellent contribution to the study of sarcoma of the large intestine.

Frequency. Sarcoma of the intestine is rare. Of 191 cases of "sarcoma of the intestines" reported in medical literature, Crowther[22] found that the majority consisted of small round-cell (68), lymphosarcoma (48) and spindle-cell (22) varieties. In a review of this work Graves[37] concluded that 119 of these cases belonged to the group of lymphoblastomas and added 130 cases (including 3 of his own) making a total of 249. In a series of 212 cases reported by Baltzer[3] (14), Rademacher[97] (140) and Key[53] (58) the majority appear to belong to the lymphoblastomas and many are fibroblastic.

Pathology. The mucosa or submucosa is probably the point of origin of all lymphosarcomas of the large intestine. The cells of origin lie in the solitary lymph follicles. Ewing[29] holds that two specific cells participate in the neoplastic process, giving rise to two forms of lymphosarcoma: (1) the reticulum cell in the germinal center of the follicle and pulp cords, and (2) the lymphocyte.

The first gives rise to the reticulum cell or large round-cell sarcoma. The second is the cell type which forms the basis of the malignant lymphocytoma. As already stated the close relationship between the reticular cell and lymphocyte makes this division acceptable from the standpoint of convenience rather than from any known distinctive embryological or histological differences between these two cells. The reticulum of lymphosarcoma is usually distributed quite irregularly, varying in amount from little or none to thickened areas of fibrosis. The pure lymphoid type is not

always present. Plasma cells, eosinophiles and normal lymphocytes may be present and probably indicate the presence of a secondary inflammation. The presence of these cells, moreover, is very suggestive of an infectious granuloma. Regressive changes are rare in lymphosarcoma. The locally aggressive character of this type of tumor is evidenced by the prompt invasion of practically every contiguous tissue. In the case of large blood-vessels, however, the adventitia is readily invaded while the media remains most resistant. Occlusion of blood-vessels by bulky growths may lead to necrosis of the tumor. The neoplastic cells are of the small or large round-cell type (mononuclear cells with abundant cytoplasm) lying irregularly in a meshwork of delicate fibrils. Fragile blood-vessels and many small lymphocytes accompany these tumor cells. Jopson and White hold that the muscular coats of the large intestine are very resistant to the invasion of these tumor cells and even after infiltration of the entire intestinal wall may persist as the only remains of the former gut. The subserous coat is not at all resistant so that a great part of the tumor mass is likely to be found between the peritoneum and whatever remains of the muscular coat. The serosa is rarely perforated. Dilatation of the gut, sometimes aneurysmal in character, is a frequent accompaniment of lymphosarcoma of the intestine. Several theories have been offered in explanation of this unusual condition. Jopson and White call attention to the early involvement of the submucosa, including its plexus of nerves, as a possible cause of dilatation in lymphosarcoma of the large intestine. Some observers explain a similar condition in the small intestine as being due to early infiltration and paralysis of the muscular fibers with subsequent dilatation of the gut by accumulated feces. Usually lymphosarcoma involves the entire circumference of the large intestine in a rather limited area, thus producing a rounded tumor without dilatation. Aneurysmal dilatation may be due to stretching of an infiltrated wall or to extensive ulceration and breaking-down of the tumor mass. In some cases the intestine

may be converted into a thick-walled tube, the infiltration extending over a considerable area of bowel. In the transverse colon the tumor tends to spread in the great omentum. The usual degenerative processes consist of ulceration of the mucosa over the tumor mass or necrosis within the tumor leading to cavity formation or occasionally to perforation.

Bearing in mind the above characteristics of primary lymphosarcoma of the large intestine we may briefly summarize its clinical-pathological course. The early stage is represented by a localized thickening of the submucosa. The process spreads laterally in this layer and finally succeeds in invading the more resistant muscularis which it partially destroys. It then appears as a subserous tumor which soon forms adhesions to surrounding structures. Rapid growth with central necrosis and superficial ulceration produces a bulky, cavity-containing tumor which usually not only does not narrow the lumen of the gut but may actually produce an aneurysmal dilatation. Baltzer[3] describes large polypoid growths protruding into the lumen of the gut without ulceration. Rarely stenosis or perforation may result. Chronic peritonitis with chylous ascites has been observed. To the naked eye the tumor masses are whitish to reddish in color, moderately firm to scirrhous, poorly outlined and of fairly homogeneous structure.

Clinical Aspects. *Location.* Of 12 cases mentioned by Nothnagel[81] the tumor process was distributed as follows: 1 duodenum; 3 jejunum; 4 ileum; 3 cecum; 1 rectum. Of Smoler's[105] 13 cases, 2 were primary in the large intestine. Treves[115] states that lymphosarcoma is rare in the colon alone and is much more common in the small than in the large intestine. Of 18 cases described by him only 1 case was in the colon alone, the common seat being the ileocecal region. Excluding the rectum he gives the small intestine as the most common site of lymphosarcoma. Libman holds that sarcoma occurs quite as frequently in the rectum as in the small intestine. He quotes Krueger's 38 cases distributed as follows: 16 small intestine;

1 ileum and cecum; 2 cecum; 1 appendix; 1 transverse colon; 1 small and large intestine; and 16 rectum. In a series of 22 cases collected by Jopson and White, excluding sarcoma of the rectum, the distribution of the tumors was as follows: 7 cecum, ileum and appendix; 5 cecum and ileum; 3 cecum and ascending colon; 4 transverse colon; 1 descending colon; and 2 sigmoid. Thus it will be seen that 14 of these tumors were located in the large intestine alone. From a study of the above figures it may be concluded that lymphosarcoma of the intestine is most commonly found in the ileocecal region or rectum. It is interesting to note that, according to Paneth[85] and Rosenheim,[100] in the rectum lymphosarcoma differs little in its manifestations from carcinoma of the same region.

Age. The disease may occur at any age. In the Jopson and White series (22 cases) the greatest number occurred in the first decade and the next greatest in the fourth decade.

Sex. There seems to be little or no difference in frequency as regards sex (12 male and 10 female, Jopson and White).

Symptoms and Signs. A tumor mass can usually be seen or palpated. In the 22 cases just mentioned a mass was palpated in 16 and in the following regions: 7 right iliac fossa; 2 umbilical; 1 epigastric; 4 to left of midline. The frequent detection of a tumor mass in the right iliac fossa is due to the relative frequency of lymphosarcoma in the ileocecal region. As felt through the abdominal wall the tumor is usually hard and smooth or nodular. As a rule it is movable and quite tender. Emaciation may be present to an extreme degree. There is usually a moderate increase in temperature, especially just before death. There may be edema of the lower extremities. Some gastro-intestinal symptoms are usually present: abdominal pain, anorexia and vomiting. Intestinal obstruction is rare even in advanced cases and those complicated by intussusception (ileocecal region).

Clinical Course. Rapid cachexia often with superimposed secondary infection in nonoperated cases leads to death within one to eighteen months. Some acute cases may be confused with acute appendicitis, probably as a result of appendicular involvement in the tumor process. Thus, Warren[121] reports a case of round-cell sarcoma of the ileocecal angle and corresponding portion of the mesentery in a boy suffering from what appeared to be chronic appendicitis with acute exacerbations.

Metastatic Deposits. Metastases appear early in the regional lymph-nodes and may extend to other organs. In the Jopson and White series the areas involved were as follows: abdominal lymph-nodes, 68.4 per cent; peritoneum, 26.3 per cent; small intestine, 10.5 per cent; lungs, 10.5 per cent; kidneys, 10.5 per cent; spleen, 10.5 per cent; liver, 15.7 per cent. Other lymph-nodes, the epididymis and spermatic cord, mesentery, orbit and secondary growths in the large intestine are also mentioned as the seats of metastatic deposits. The most common sites of metastases therefore are the abdominal lymphatics. The dissemination of tumor cells is through the mesentery, with early involvement of the nodes.

Prognosis. The prognosis will depend upon the period at which the disease is detected. Generally the disease process has advanced extensively before the patient appears for examination.

Treatment. Resection of involved intestine and lymphatic drainage areas should be practiced in every early case. Invasion of the blood-vessels and metastatic deposits other than in the regional lymph-nodes are probably not present in early cases. Radiotherapy is still in an experimental stage but holds forth some promise for the future. Where resection cannot be practiced, arsenic or Coley's fluid may be used.

B. Other Neoplastic Formations Associated with the Lymphoid Structures of the Large Intestine

Gastrointestinal Pseudoleucemia. This condition of the gastrointestinal tract is characterized by a diffuse primary hyperplasia of the lymphoid structures which lacks the destructive nature of lymphosarcoma and yet is not accompanied by an increase in the white cells of the blood. The pathological process may involve the gastrointestinal tract in its entirety or to a limited extent and may be associated with similar lesions of other lymphoid structures in the body. The disease was described by Briquet,[12] Stoerck,[109] Carrington, Hadden, Pitt and others, including a recent contribution by Symmers[111] who reviewed the literature to date (1909). The last author records 11 cases, including one of his own. The glandular involvement and blood picture strongly resemble Hodgkin's disease. In Symmers' case there was a bilateral enlargement of the cervical lymph-nodes with involvement of the mucosa of the entire gastrointestinal tract from pylorus to anus by myriads of nodular masses of different sizes so closely packed that hardly an area of intact mucosa remained. Most of these tumor masses were conical in shape and embedded in the mucosa by a broad base. A few were suspended full in the lumen by delicate pedicles. The Peyer's patches were hyperplastic and a large pedunculated mass 4 cm. in height was found at the beginning of the ascending colon. Enlargement of the cervical, mediastinal, retroperitoneal and other lymph-nodes, with preservation of their outlines, enlargement of the spleen and generalized peritonitis of unknown etiology have been described.

Microscopically there appears to be an extensive increase in lymphoid follicles which become greatly enlarged and eventually fuse. These lymphoid collections occupy the mucosa and submucosa replacing almost entirely the normal glandular elements. Symmers describes numbers of small circum-

scribed, richly cellular lymphoid foci arranged around the periphery of individual nodules. These were in strong contrast to the centers of the nodules, which were occupied by loosely arranged, diffusely distributed, medium-sized, lymphoid cells. Mitoses are usually not found and there is no tendency to invade resecting structures. In the case of Wells and Maver the pylorus was partly occluded while in Stoerck's case the process penetrated the wall of the colon and bore a strong resemblance to sarcoma.

It will be seen therefore that gastrointestinal pseudoleucemia is a condition involving an orderly proliferation of lymphocytes which usually show no tendency to invade surrounding tissues. The resulting tumors are therefore quite benign.

Leucemic Lymphoma. In leucemia there may be seen growths resembling the lymphatic tissue of lymph-nodes originating in the solitary nodules of the intestinal wall. In lymphatic leucemia the nodes exhibit a marked hypertrophy of the lymph follicles which fuse with the pulp cords and convert the entire structure into a diffuse lymphoid tissue. In other cases the lymph follicles seem to be compressed by the newly formed lymphocytes in the pulp cords. In myelogenous leucemia the pulp cords are increased in size by the presence of myelocytes which distend the cords, obliterate the sinuses, cause atrophy of the lymph follicles and may even infiltrate the capsule or surrounding fat. Giant cells and nucleated red blood-cells may be present.

C. Other Atypical Lymphoid Tumors of the Large Intestine

Sternberg describes a condition of leucosarcoma with multiple nodules in the serous membrane and in the intestinal musculature. These nodules were composed of atypical, large cells like those seen in leucemic infiltrations.

Moritz describes a lymphosarcoma of the cecum accompanied by involvement of the spleen, lymph-nodes and bone marrow, with a blood picture resembling leucemia.

The gastrointestinal form of Hodgkin's disease resembles both tuberculosis and lymphosarcoma. The lesions are likely to be found in the stomach, ileum and cecum. There are local ulcerations, swelling of the regional lymph-nodes and microscopic lesions resembling those found in Hodgkin's disease. There is a diffuse cellular hyperplasia and a reticulum supporting proliferating lymphocytes, plasma cells, eosinophiles, endothelium and endothelial giant cells. Most of these cases are interpreted as lymphosarcoma.

D. Fibroblastoma

The basic cell type in this class of tumors is the fibroblast or connective-tissue cell. The large intestine is an extremely rare site for primary fibroblastomas. The latter may be divided into two types: fibroma and fibrosarcoma (spindle-cell sarcoma).

Fibroma. A pure fibroma of the colon or rectum is rarely found. Dewis in a search of the literature found reports of only three cases: 1 descending colon (Jansen[49]) and 2 rectum (Heurtaux[44]). He adds a case of his own in which a small fibroma was found about 4 inches above the ileocecal valve, resulting in intussusception. Most fibromata of the intestine are of the mixed type (adeno-, myo-, myxo-).

Fibromata may be divided into hard and soft varieties, depending upon their histological structure. These tumors are usually slow growing, encapsuled and benign in their clinical course. Because of the difficulty in distinguishing between some fibromata and fibrosarcomata it may be of interest to review more closely the cellular elements. The fibroblast is usually a flat elongated cell with one or more cytoplasmic processes at each end. This cell produces three kinds of fibrils: fibroglia, collagen and elastic fibrils. The nucleus of the fibroblast is vesicular, flat and oval. The fibroglia fibrils are straight or slightly curved and run along the surface of the cytoplasm. The collagen fibrils lie free between the cells, are more delicate than the preceding

and run parallel in wavy bundles. The elastic fibrils are fine or coarse and form an interlacing network. Tumors arising from fibroblasts usually grow very slowly (fibroma) but may grow with great rapidity (fibrosarcoma). The cells of tumors arising from fibroblasts resemble the normal type with oval nuclei, and produce fibroglia, collagen fibrils and occasionally elastic fibrils. The collagen fibrils are always more abundant. In a fibroma the fibroglia fibrils, like the fibroblasts, are few in number, the tumor being composed chiefly of interlacing bundles of collagen fibrils. The cells and fibrils are sometimes joined together in small or large bundles which run in different directions. If the bundles and strands are closely woven the resulting fibroma is of the hard variety; if loosely woven or edematous a flabby, soft mass results, soft fibroma. Fibromata grow expansively and form rounded nodular masses surrounded by a fibrous capsule. A benign tumor, the fibroma of the large intestine is of importance only because of its size or location.

In this connection it may be of interest to mention an inflammatory condition known as fibromatosis of the colon. Boyd[11] states that cases of carcinoma operated upon and clearing up after colostomy are in reality examples of fibromatosis. This condition simulates the hypertrophic form of tuberculosis. It may affect any part of the large intestine but most frequently the pelvic colon and rectum. The wall of the bowel for a varying distance is thickened owing to the presence of a dense inflammatory tissue in the submucosa. The mucosa is nodular or polypoid and may be ulcerated. This pathological condition is probably of infectious origin.

Fibrosarcoma (spindle-cell sarcoma). This type of tumor in the large intestine arises chiefly from the muscular coat and produces a large solid or cystic mass lying external to an intact mucosa. Histologically, a great deal of confusion exists owing to the occurrence of spindle cells in tumors arising from cells other than the fibroblast of fibrosarcoma (e.g., tumors of

unstriated muscle, epithelium of the basal layers of the skin or renal pelvis, the dural endotheliomata). But knowing the source of the tumor there remains a definite neoplastic process arising from fibroblastic tissue and characterized by rapid growth and great malignancy, the fibrosarcoma. In contradistinction to the fibromata, the fibrosarcoma is made up of rapidly growing cells which have little tendency to differentiate (the fibroglia and collagen fibrils being seen with difficulty). Multinucleated giant cells with multiple mitoses may be present and are capable of producing fibrils like the other tumor cells. The stroma is composed for the most part of blood-vessels lined with a single layer of endothelium. The most active proliferation takes place in the cells adjoining the blood-vessels. A varying amount of connective tissue may be present.

The fibrosarcoma is rapidly invasive and gives rise to metastases chiefly by way of the blood stream. Upon section the cut surface is even and resembles fish flesh (Mallory).

E. Myxosarcoma

This type of tumor is said to arise from the submucosa and affects chiefly the cecum and appendix. It may contain large cysts.

F. Melanoblastoma (Melanoma, Melanosarcoma)

This is a comparatively rare but very interesting primary tumor in the intestine. Viborg observed melanomata in horses. Brugnone also described the condition in 1781. In man melanoma was first mentioned in 1806 by Laënnec. In 1863 Ashton described melanoma in his work on diseases of the rectum and anus. Virchow[118] published a case in 1869 and Curling in 1883 cited a case previously reported by Moore. In 1877 Mollière in his "Traité des Maladies du rectum" described all of the cases reported to date. After various other reports (Tuffier,[116] Paneth, Schmidt, Petersen, Barner, Zimmerman, Breuer,

Raecke and Sigerist) the classical treatise of Quénu and Hartmann[94] appeared in "Chirurgie du rectum." Most of the following data were obtained from the excellent treatise by Chalier and Bonnet.[16]

Age. In 55 cases reported by Chalier and Bonnet the age varied from twenty-two to seventy-seven years, the majority occurring between the ages of forty and seventy (39 cases out of 55). Ewing observed a cecal melanosarcoma in a child of eight years.

Sex. Thirty-seven, men; eighteen, women.

Location and Size. Melanoma of the intestine occurs almost exclusively in the rectum and arises from the anal orifice or low down in the ampulla. It usually produces a single circumscribed mass varying in size from a pea to an infant's head. Multiple melanosarcomata have been reported, however, by Schümann[104] (one in the ampulla, the other higher up in the rectum), Martin and Rives[72] (one in the ampulla, the other in anus), Tuffier and François-Dainville,[33] Ciechomski,[18] Wiener.[123]

Pathology. The tumor mass is nodular or bulky. The polypoid form is very common, the pedicle being short and thick. Tuffier describes the general appearance to be not unlike a tonsil covered with mucus. Meurier describes a case in which the rectum was encased in a cylindrical tumor mass. Ewing found the ileocecal orifice surrounded by a lobulated tumor. The growth arises and expands in the submucosa and only occasionally does the mucosa ulcerate, giving the appearance, as Sandner[101] describes it, of a mucosa which has been opened by a large incision, enucleating a neoplastic mass. The tumor is usually of a bluish color when covered by mucosa, black when ulcerated. Subcutaneous hemorrhage may give it a violaceous tinge. The consistence is elastic and firm, soft or fluctuating. The caliber of the rectum is little obliterated by the tumor, which, in general, is not thicker than 2 to 3 cm. The mass does not circumscribe the intestinal wall like carcinoma.

The melanotic nature of the tumor, moreover, is not always visible in the gross.

Arising and spreading in the submucosa, the mucosa generally remains movable over the tumor and is not invaded by it. The muscularis is compressed by the neoplastic infiltration between it and the mucosa. The perirectal tissue, especially the ischiorectal fossa, is sometimes invaded. The sacrococcygeal and inguinal nodes become involved, the latter in anal melanomata. Metastases occur most often in the liver.

Chalier and Bonnet divide melanomata of the rectum according to their microscopic structure into four types: (1) round cell; (2) fusiform cell; (3) globular and fusiform cells; (4) giant cell.

The mucosa of the rectum is separated by the muscularis mucosae from the tumor-cell masses which infiltrate the submucosa and muscularis. The cells are small, rounded, fusiform or polyhedral with round vesicular nuclei and scanty cytoplasm. The tumor is usually lobulated, the lobulations being separated by a richly vascularized tissue. The pigment is distributed throughout the entire mass, in the connective tissue and around vessels. Eventually the tumor cells may penetrate the mucosa.

The dark-brown pigment is an iron-free metabolic product of the cells and, according to Chalier and Bonnet, may be found as follows: (1) Fine granules filling the cytoplasm of the tumor cells. These granules may form discrete, polygonal, rounded or spindle-shaped masses in the cell. (2) Fine granules in the connective tissue surrounding the rows of neoplastic cells; and (3) large masses two or three times the size of the tumor cells, round or spindle in shape, and probably made up of fused cells filled with pigment.

Chalier and Bonnet believe that primary melanomata of the anorectal region are cutaneous epitheliomata capable of becoming tumors of the rectum by progressive infiltration along the submucosa, becoming pedunculated or

secondarily ulcerated in the rectum. The correctness of this view is somewhat doubtful as most rectal melanomata are found in the ampulla. If the rectal melanomata are of epidermal origin they are probably best explained on the basis of misplaced tissue rests. A simpler explanation, however, may be found in tracing their origin to groups of chromatophores located in the submucosa (Ewing).

Symptoms. Aside from occasional tenesmus and frequent anal discharge there are very few symptoms. There is little or no pain, constipation or occasional diarrhea. Chalier and Bonnet describe a soot-tinged fluid covering the feces.

Diagnosis. Digital examination and proctoscopy make the diagnosis quite simple. It is well to examine the inguinal nodes for metastatic involvement.

Treatment. Radical operation is indicated in early cases but is usually resorted to too late to be of any avail. This type of tumor is always malignant and frequently gives rise to metastases by way of the blood and lymph streams before the primary tumor has given any evidence of its presence.

G. Lipoblastoma (Lipoma)

Lipoma of the large intestine is a relatively rare tumor and usually arises in the submucosa or appendices epiploicae of the colon. Ehrlich[27] collected 52 cases of submucous lipomata in a search through the literature. These tumors were located as follows: 3 stomach; 6 duodenum; 6 jejunum; 9 ileum; 24 large intestine (including cecum, sigmoid and rectum); 4, location not mentioned.

Dewis[25] in an excellent account of benign intestinal tumors states that intestinal lipomata (including small and large intestine) occur next in frequency to adenomata. He reports 44 cases of intestinal lipomata collected from the literature. Hiller[46] and Ward[120] have reviewed the subject. Of the

44 cases above mentioned the fatty tumors were located as follows: 6 duodenum; 4 jejunum; 7 ileum; 2 cecum; 5 colon; 5 sigmoid; 6 rectum; 2 "small intestine"; 1 "intestine"; 6 not stated. In 9 of these cases the tumor was expelled spontaneously, while in 21 intussusception occurred. The subserous lipoma may be eventually set free in the peritoneum. Ewing observed a large fatty tumor (4 by 10 cm.) surrounding the appendix, which was the seat of a chronic suppuration. The frequent occurrence of intussusception associated with the presence of a lipoma of the intestine is worthy of note. Zum-Busch reports an ileocecal invagination caused by a Meckel's diverticulum at the apex of which there was a lipoma. Heurtaux reports a lipoma, 5.7 by 4.8 cm. in size, in the upper portion of the descending colon, associated with invagination; Voss[119] describes a pedunculated nodular lipoma of the rectum associated with prolapse. Ray[98] reports a submucous lipoma of the sigmoid situated at the apex of an intussusception. Richardson[99] saw a lipoma of the cecum causing an ileocecal invagination which reached as far as the sigmoid. Very large retroperitoneal lipomata have been observed (Madelung, Waldeyer, Adami).

The age at which this type of tumor has been found in the intestine varies from eighteen to eighty-three years. Le Garde reports a large lipoma situated high up in the rectum in a man of sixty-five.

The lipoma is usually a firm, rounded, lobulated, elastic tumor which is sharply circumscribed from the surrounding tissue. The presence of a connective tissue capsule enables one to easily shell the lipoma out of the tissue in which it is embedded. Usually benign, this type of tumor may prove harmful because of its large size or location. The lipoma grows slowly and expansively. The consistence is that of normal fat but varies according to the amount of fibrous connective tissue present or because of secondary changes. It may possess a pedicle which occasionally atrophies. The lipoma has a peculiar structure in that each lobule contains a nutrient blood-vessel

which, in turn, is a branch of the main vessel supplying the tumor. The lobules vary in size and the supporting stroma is irregular in its distribution. The cells are usually those of the adult type, held together by a small amount of connective tissue and supplied with capillary blood-vessels. The fat cells may be large and overdistended with fat or may produce the small embryonal type with central nucleus and granular cytoplasm. Often there may be seen collections of polyhedral cells in which the fatty deposits are incomplete. Ewing believes that it is from such groups, isolated or lying along blood-vessels, that the growth of lipoma chiefly occurs. Occasionally the young cells contain a granular lipoid pigment as is found in xanthoma cells. The vascular supply of a lipoma is usually quite rich, the arterioles running out in the stroma of the lobules and dividing into capillaries. The lymph vessels may be overdeveloped leading to structural changes indicative of another type of tumor. Thus Borst observed the transformation of a lipoma into a fibrous lymphangioma. Occasionally, lipomata undergo necrosis, cyst formation, calcification, mucinous, waxy, myxomatous or sarcomatous degeneration.

H. Liomyoblastoma (Liomyoma)

Liomyomata are not very commonly found in the intestine and are usually of the mixed fibrous type. The tumor masses may be single or multiple, Nazzari describing 40 small tumors in 1 case and as many as 120 in another. Dewis found records of 40 cases in the literature. Steiner's[106] monograph on the subject is most complete. He describes their location as subperitoneal, in which case they are likely to produce diverticula, or as submucous, in which case they may cause stenosis or intussusception. Boettcher[9] and Lode[63] describe three types of intestinal myoma:

(1) Small multiple nodular or polypoid tumors arising from local proliferation in the muscularis. The mucosa is free.

(2) Broad thick tumor masses which form in the muscle layers, the mucosa becoming adherent to the tumor.

(3) The large subserous polypoid myoma which may project into the peritoneum.

Dewis divides intestinal myomata into the external type, growing from the outside of the intestinal wall and usually possessing a pedicle, and the intra-intestinal or internal form.

Both gastric and intestinal liomata are likely to be associated with uterine fibromyomata and they appear to originate from isolated portions of smooth muscle. Intestinal liomata vary in size from a miliary tumor to one of considerable dimensions, are spherical or lobulated, of a reddish-grey color and quite dense in consistency. An abundance of connective tissue will produce a very hard tumor. Some, however, are soft and edematous. Occasionally one may note dilated blood-vessels or cysts formed by dilated lymphatics. Occasionally glandular structures may be present, corresponding to the adenomyoma of Trappe.[114] Thus, Cohen found areas of pancreas in an intestinal myoma. Vascular congestion may give a dark mottled appearance to a myoma. Upon section the tumor exhibits characteristic convoluted markings from the presence of intertwining bands of muscle cells. Being sharply circumscribed, the tumor usually shells out of the tissue in which it is embedded quite easily. Ribbert finds that the blood supply of myomata is rather scanty as compared with that of the surrounding tissue, and nutrition is maintained chiefly by the lymphatics. Probably for this reason myomata grow very slowly, remain stationary in their growth for long periods and are subject to regressive changes. The blood-vessels of a myoma may be normal in structure or composed chiefly of hypertrophic muscle cells and deficient adventitia.

Microscopically, the smooth-muscle cell is found to be the unit of growth. This type cell is long and spindle-shaped with a rod-shaped nucleus and dense acidophil cytoplasm. Longitudinal striations are present in the latter due to the presence of myoglia fibrils. These fibrils are delicate and separated

except at the ends of the cell where they fuse. Smooth-muscle cells are always surrounded by collagen fibrils which bind them together and are products of the fibroblasts which are interspersed among the muscle cells. The tumor cell is usually somewhat thicker and shorter than the normal type, the nucleus is larger and richer in chromatin and the cytoplasm less acidophil. Actively growing tumors begin to exhibit a malignant character by an increase in the size of the muscle cells, the formation of giant cells and disappearance of the connective-tissue stroma (malignant liomyoma, liomyosarcoma). The presence of mitotic figures is generally regarded as evidence of capacity for infiltration and producing metastases. Defective blood-vessel walls are significant (Krische,[57] Langerhans,[61] Williams,[124] Beesten,[5] Moser,[76] Basso).

Myomata are frequently subject to regressive changes such as fatty degeneration, hydropic degeneration, necrosis, hyaline degeneration or calcification. Adenoid tissue may develop about included glandular tissue. Mast cells may be very numerous. Infection, pedunculation, hyaline changes in the stroma or closure of the blood-vessels hasten degeneration. The formation of abdominal adhesions may accelerate the growth of a myoma.

In a study of 40 cases of intestinal myoma Dewis found the location to be as follows: 17 small intestine (3 duodenum; 2 jejunum; 11 ileum; 1 undefined); 9 large intestine (1 appendix; 3 cecum; 4 colon; 1 sigmoid); 4 undefined; 10 rectum. Hollander reports an invagination of the colon 15 cm. in length containing a myoma about the size of a prune. As in the case of the adenomata and lipomata the tumor acts as a foreign body, which the intestine makes strenuous efforts to expel. The result is often pedunculation of the tumor or intussusception of the gut. Konig describes a polypoid myoma of the rectum in a girl of seventeen.

Intestinal myomata may occur at any age. They are slowly progressive in their growth but after a long period may come to a standstill or regress. The treatment is local excision or resection in cases giving symptoms. The

use of the roentgen ray has been suggested as it seems to have proved quite successful in the treatment of some uterine myomata.

I. Angioma

Angiomata of the intestinal tract are extremely rare and usually of the blood-vessel type. The vessels are embedded in a scanty connective-tissue stroma and may be of the capillary or cavernous type. Of the two, the former is the more frequent and often grows with considerable rapidity. Multiplication of endothelial cell layers with active mitosis, papillary endothelial projections into the blood-vessel lumen, occlusion of vessels by the tumor cells, marked increase in fibrous tissue, fatty degeneration or even a tendency to invade the surrounding tissues may be found in angiomata. The true cavernous angioma consists of large irregular cavities separated by septa of connective tissue covered on either side by endothelial cells. This type of tumor probably originates within the larger blood-vessels. March reports a nevoid growth in the rectum completely surrounding the bowel occurring in a girl of ten suffering from repeated hemorrhage of the bowel since the age of two. Barker reports a case occurring in a man of forty-five who had complained of bloody stools since boyhood. A severe diarrhea was also present. The wall of the rectum was thickened for about 11.5 cm. of its lower extent by a nevoid growth. Microscopically, the tumor was seen to be a cavernous nevus involving both the mucosa and submucosa. Lehman described as an interfascicular endothelioma a diffuse thickening of the entire intestine with secondary growths in the liver.

J. Résumé of Benign Tumors of the Colon and Rectum

In order of frequency, benign tumors of the large intestine are lipoma, fibroma, myoma, angioma and lymphangioma. The fibroma, myoma and lipoma of the internal type are not as frequent as in the small intestine, while the external lipoma is relatively common in the large intestine due to

the excessive development of the appendices epiploicae. The clinical symptoms of benign intestinal tumors are those of obstruction or irritation of the intestinal mucosa (as evidenced by discharge and diarrhea). The obstruction may be partial or complete and symptoms of ileus may develop even though the tumor is considerably smaller than the bowel lumen. The course is usually a chronic one, many patients having symptoms for years. Bloody stools may accompany the presence of any of the above tumors except fibroma. Anemia and cachexia may supervene in chronic cases.

Dewis compiled an instructive table of benign intestinal tumors, their location, relative frequency and association with intussusception.

BENIGN INTESTINAL TUMORS (DEWIS)

Tumor	Intussusception
Angioma, 3 (rectum, 2)	0
Fibroma, 5 (rectum, 2)	2
Myoma, 40 (rectum, 10)	9
Lipoma, 44 (rectum, 6)	16

LOCATION OF TUMOR

Location	Angioma	Fibroma	Myoma	Lipoma	Adenoma	Total
Duodenum	0	0	3	6	4	13
Jejunum	0	0	2	4	3	9
Ileum	0	2	11	7	7	27
Appendix	0	0	1	0	0	1
Cecum	0	0	3	2	2	7
Colon (including sigmoid)	0	1	5	10	30	46
Rectum	2	2	10	6	81	101
Small intestine	1	0	1	2	0	4
Intestine	0	0	4	7	0	11
Total	3	5	40	44	127	219

From the table on the preceding page, it will be seen that the relative occurrence of adenomata and all other benign tumors is as follows:

Tumor	Small intestine, per cent	Large intestine, per cent	Rectum, per cent
Adenoma	11.0	25.2	63.8
All other benign tumors	48.1	27.1	24.8

K. Cysts of the Large Intestine

Cysts of the large intestine are very rare. Ayer, in a review of enteric and mesenteric cysts divides the former as follows:

(1) Cysts arising from glandular structures of the intestinal wall. These are usually located in the mucosa and result from inflammatory occlusion of the gland mouths and continued accumulation of secretion. Fränkel[32] reports a case of a four-year-old child having multiple cysts between the mucosa and serosa, but chiefly in the former. He also reports a 2.5 cm. rounded cyst at the ileocecal region projecting into the lumen of the gut. Krogius,[58] reviewing sixteen post-mortem examinations of enteric cysts, reports four occurring on the ileocecal valve. Most of these cysts present themselves on the convex surface of the gut, springing from the submucous, subserous or possibly intermuscular layers.

(2) Parasitic cysts (hydatid) are likely to be found in the mesentery but may occur in the intestinal wall and are due to the echinococcus. The cyst wall is laminated and the characteristic scoleces or hooklets or both are found in the cyst cavity.

(3) Cysts due to degenerative changes in malignant growths.

Thalheimer[120] reports a case of intestinal gas cysts lying just beneath the serosa of the ileum and associated with tremendous dilatation of the stomach. Approximately 30 cases of intestinal gas cysts have been reported in the literature. Gas cysts with glistening walls are found in one or all coats of the

intestine with the exception of the mucosa. They vary in size from microscopic dimensions to several centimeters. Arzt found that the contained gas was rich in hydrogen but most observers have found the gaseous contents quite like atmospheric air. The cysts are lined entirely or in part by endothelium. In most cysts, as one follows the periphery there is evident a marked transition from the flattened narrow endothelial cells to cubical, cylindrical cells, syncytial masses or even multinuclear giant cells. These giant cells may also be present in the surrounding connective tissue and are usually located in the lymph spaces or capillaries.

These cysts usually cause no intestinal symptoms but are associated with other diseased conditions of the gastrointestinal tract. The etiology is quite obscure. The current theories attribute their origin to (1) congenital anomaly; (2) infection of the intestinal wall with gas-producing bacteria entering through minute lesions of the mucosa; and (3) localized proliferation of the lymphatic endothelium causing obstruction and damming-back of the lymph. Gas of unknown origin collects in the lymphatics, cysts form and giant cells appear in response to irritation by the contained gas (Arzt).

BIBLIOGRAPHY

1. Anschutz. *Mitt. G. G.*, 3. See Ewing, J. Ref. 29.
2. Bailey, F. R. A Text-book on Histology. N. Y., 1916, p. 232.
3. Baltzer, M. Ueber primäre Dunndarmsarcome. *Arch. f. klin. Chir.*, Berl., 1892, xliv, 717.
4. Batzdorff, E. Ein Beitrag zur Frage des primären Appendixcarcinoms. *Arch. f. klin. Chir.*, Berl., 1912, xcviii, 76–105. (Excellent bibliography.)
5. von Beesten, C. Myommetastasen in Leber, Lunge und in der Musculatur. Path.-anat. Arb. . . . Joh. Orth. Z. . . . Prof.-Jubil., Berl., 1903, p. 231–236.
6. Bernouille, E. Magen-Darmkrebs in den beiden ersten Lebensdezennien. (Inaugural Dissertation, Bâle). Berl., 1907.
7. Blauel. Ueber Sarcome der Ileocecalgegend. *Virchow's Arch. f. path. Anat., etc.*, Berl., 1900, clxii, 487.
8. Boas, I. Beiträge zur Kenntnis der Rektumkarzinome nebst Bemerkungen zur Frühdiagnose. Berl., 1906, 32 pp.
9. Boettcher, A. Einige Bemerkungen über Darmmyome. *Virchow's Arch. f. path. Anat., etc.*, Berl., 1886, civ, 1–10.
10. Bowing, H. H., and Anderson, F. W. The treatment by radiation of cancer of the rectum. *Am. J. Roentgenol. & Rad. Therap.*, N. Y., March, 1923, x, 230–239.
11. Boyd, W. Surgical Pathology. Phila., 1925, p. 306.
12. Briquet, P. In Cruveilhier, J. C. Atlas of the Descriptive Anatomy of the Human Body. 1835, ii, 34.
13. Cannon, W. B. *Am. J. Physiol.*, Boston, 1902, vi, 251.
14. Carman, R. D. Roentgenologic signs of cancer of the colon. *J. Radiol.*, Omaha, May, 1923, iv, No. 5, 149.
15. Carman, R. D., and Fineman, S. The roentgenologic diagnosis of diseases of the colon. *J. Radiol.*, Omaha, Nov., 1923.
16. Chalier, A., and Bonnet, P. Les tumeurs mélaniques primitives du rectum. *Rev. de chir.*, Par., 1912, xlvi, 914–957; 1913, xlvii, 233–255, 372–391, 563–588.
17. Cheatle, G. L. The spread of cancer in the lower part of the large intestine. *Brit. M. J.*, Lond., Feb. 7, 1914, i, 303–304.
18. Ciechomski, A. [Melanosarcoma of the rectum.] *Gaz. lek.*, Warszawa, Oct. 8, 1910, s. 2., xxx, 970–977.
19. Clar. See Nothnagel, H. Ref. 80.
20. Cole, P. P. The intramural spread of rectal carcinoma. *Brit. M. J.*, Lond., 1913, i, 431–433.
21. Cripps, H. Cancer of the Rectum. Jacksonian Prize Essay. Ed. 3. Lond., 1890.
22. Crowther, C. Studio dei sarcomi primitivi dell' intestino tenue con contributo di tre casi originali. *Clin. chir.*, Milano, 1913, xxi, 2107–2144.

23. Czerny. Zur Darmresection. *Berl. klin. Wchnschr.*, 1880, xvii, 637–642.
24. Debrunner, A. Drei Fälle von Sarkome des Darmes im Kindesalter. Inaugural Dissertation, Zurich, 1883 (quoted by L. Orth).
25. Dewis, J. W. A small fibroma of the ileum resulting in obstruction of the bowel. *Boston M. & S. J.*, 1906, clv, 427–433.
26. Doering, H. Die Polyposis intestini und ihre Beziehung, zur carcinomatösen Degeneration. *Arch. f. klin. Chir.*, Berl., 1907, lxxxiii, 194–227.
27. Ehrlich. Zur Kasuistik der Intestinallipome. *Beitr. z. klin. Chir.*, Tübing., 1911, lxxi, 384–395.
28. Elting, A. W. Primary carcinoma of the vermiform appendix with a report of three cases. *Ann. Surg.*, Phila., 1903, xxxvii, 548–574.
29. Ewing, J. Neoplastic Diseases. Ed. 2. Phila., 1922, p. 348.
30. Ewing, J. *Op. cit.*, p. 667. Table compiled from statistics.
31. Ewing, J. *Op. cit.*, p. 673.
32. Fränkel, E. Ueber Cysten im Darmkanal. *Virchow's Arch. f. path. Anat., etc.*, Berl., 1882, lxxxvii, 275.
33. François-Dainville, E. Sarcome mélanique du rectum avec adénopathie inguinale. *Bull. et mém. Soc. anat. de Par.*, Jan., 1904, lxxix, 39; Sarcome mélanique ano-rectal, avec adénopathie inguinale. *Ibid.*, July, 1908, lxxxiii, 380–384.
34. Gant, S. G. Cancer of the rectum *N. York M. J.*, July 21, 1906, lxxxiv, 111–114.
35. Garrard, W. A. A case of carcinoma of the colon occurring in a child. *Quart. M. J.*, Sheffield, 1896–1897, v, 234–237.
36. Goeckel, M. Ueber die traumatische Entstehung des Carcinoms mit besonderer Berücksichtigung des Intestinaltractus. *Arch. Vdk.*, 1896, ii, 461–490.
37. Graves, S. Primary lymphoblastoma of the intestine. *J. Med. Research*, Bost., 1919, xl, 415–431.
38. Gray, H. Anatomy, Descriptive and Applied. Lond., 1923.
39. Handley, W. S. The surgery of the lymphatic system. *Brit. M. J.*, Lond., Apr. 16, 1910, p. 927–928.
40. Hartmann, H. Traitement opératoire direct du cancer du rectum. *J. de chir.*, Par., 1913, xi, 693–702.
41. Hartwell, J. A. The radical treatment of cancer of the rectum with particular reference to the value of inguinal colostomy. *Ann. Surg.*, Phila., Sept., 1905, xlii, 399–444.
42. Hauser, G. Das Cylinderepithel-Carcinom des Magens und des Dickdarms. Jena, 1890.
43. Hertz, A. F. The passage of food along the human alimentary canal. *Guy's Hosp.Rep.*, Lond., 1907, lxi, 389–427.
44. Heurtaux, A. Note sur les tumeurs bénignes de l'intestin. *Arch. prov. de chir.*, Par., 1899, viii, 710–712.
45. Hewitt, J. H., and Howard, W. T. Chronic ulcerative colitis with polyps. *Arch. Int. Med.*, Chicago, May, 1915, xv, 714–723.
46. Hiller, T. *Beitr. z. klin. Chir.*, Tübing., 1899, xxiv, 509.
47. Jamieson, J. K., and Dobson, J. F. Excision of the cecum and ascending colon with the corresponding lymphatic area. *Lancet*, Lond., 1908, i, 149–151.

48. Jamieson, J. K., and Dobson, J. F. The lymphatic system of the cecum and appendix. *Lancet*, Lond., 1907, i, 1137–1143.
The lymphatics of the colon. *Proc. Roy. Soc. Med.*, Lond., 1909, ii, 149–174.
49. Jansen. *Compt. Rend. de la Soc. de méd. de Riga*, April 16, 1886. *Rev. de sc. med.*, Par., xxiv, 637 (from Heurtaux, *Op. cit.*).
50. Jopson, J. H., and White, C. Y. Sarcoma of the large intestine. *Am. J. M. Sc.*, Phila., 1901, cxxii, 807–828.
51. Kelly, A. O. J. Primary carcinoma and endothelioma of the vermiform appendix. *Am. J. M. Sc.*, Phila., 1908, n.s., cxxxv, 851–856.
52. Kelly, H. A., and Ward, G. E. A clinical study of radium therapy in carcinoma of the rectum. *Surg., Gynec. & Obst.*, Chicago, Nov., 1923, xxxvii, 626–634.
53. Key, E. Zur Kasuistik des Rektalsarcoms. *Nord. med. Ark.*, Stockholm, 1908, s. 3, viii, afd. 1, No. 13, 1–11.
54. Körte, W. Erfahrungen über die operative Behandlung der malignen Dickdarm-Geschwülste. *Arch. f. klin. Chir.*, Berl., lxi, 403–462.
55. Konjetzny, G. E. Zur Frage der primären Appendixcarcinome. *Deutsche Ztschr. f. Chir.*, Leipz., 1910, ciii, 365–373.
56. Kraske, P. Erfahrungen über den Mastdarmkrebs. *Samml. klin. Vortr.*, Leipz., 1897–1900, n.s., li-lxxx, 771–851. Chirurgie.
57. Krische. Inaugural Dissertation. Göttingen, 1869.
58. Krogius, A. Enterokystom und Darmverschluss. *Ztschr. f. klin. Med.*, Berl., 1903, xlix, 1–4.
59. Kuttner, H. Bericht über 800 (1021) Rektumkarzinome. *München med. Wchnschr.*, 1920, lxvii, 799–800.
60. Lagutière and Dupuytren, G. Le Médecine Opératoire. iv, 218.
61. Langerhans, R. Demonstration eines Präparates von myoma laevicellulare malignum. *Berl. klin. Wchnschr.*, 1893, xxx, 338–339.
62. Lisfranc, J. Cancer du Rectum. Vidal, 1842.
63. Lode, A. Ein subseröses Myom des ileum nebst Bemerkungen über Darmmyome. *Wien. klin. Wchnschr.*, 1894, 381–383.
64. Louart, A. E. F. Cancer du Gros Intestin dans la Jeunesse. Paris Thèse, 1900, p. 1–96.
65. Lubarsch, O. Ueber den primären Krebs des Ileum, nebst Bemerkungen über das gleichzeitige Vorkommen von Krebs und Tuberculose. *Virchow's Arch. f. path. Anat., etc.*, Berl., 1888, cxi, 280–317.
66. Lusk, W. C. Excision of the rectum for cancer. *Surg., Gynec. & Obst.*, Chicago, Aug., 1908, vii, 113–226.
67. Lynch, J. M. Cancer of the rectum and pelvic colon. *J. A. M. A.*, Chicago, 1917, lxix, 1775.
68. McGrath, B. F. Intestinal diverticula: their etiology and pathogenesis. *Surg., Gynec. & Obst.*, Chicago, 1912, xv, 429.
69. McVay, I. R. Involvement of lymph-nodes in carcinoma of the rectum. *Ann. Surg.*, Phila., 1922, lxxvi, 755–767.
70. McWilliams, C. A. Primary carcinoma of the vermiform appendix. *Am. J. M. Sc.*, Phila., 1908, n.s., cxxxv, 822–850.

71. Majerus, F. Zur Diagnose und Chirurgie des Dickdarmcarcinoms. *Beitr. z. klin. Chir.*, Tübing., 1920, cxviii, 363–396.
72. Martin, J., and Rives. Sarcome mélanique du rectum. *Bull. et mém. Soc. anat. de Par.*, May, 1908, lxxxiii, 289.
73. May, E. A. Surgical and roentgen treatment of carcinoma of the rectum. *Am. J. Roentgenol. & Rad. Therap.*, N. Y., March, 1924, xi, 246–251.
74. Mayo, W. J. A study of the rectosigmoid. *Surg., Gynec. & Obst.*, Chicago, 1917, xxv, 616–621.
75. Moschcowitz, A. V. Primary carcinoma of the appendix. *Ann. Surg.*, Phila., 1903, xxxvii, 891–917.
76. Moser. Ueber Myosarkom des Magens. *Deutsche med. Wchnschr.*, Berl. & Leipz., 1903, 133–135, 157–160.
77. Mummery, J. P. L. Diseases of the Rectum and Colon and Their Surgical Treatment. Lond., 1923.
78. Neugebauer, F. Ueber gutartige Geschwülste, Carcinome und sogenannte Carcinome des Wurmfortsatzes. *Beitr. z. klin. Chir.*, Tübing., 1910, lxvii, 328–358. (Excellent bibliography.)
79. Niemack, J. *Ann. Surg.*, Phila., 1902, xxxvi, 104–108.
80. Nothnagel, H. Encyclopedia of Practical Medicine. Phila., 1907.
81. Nothnagel, H. Specielle Pathologie und Therapie. xvii. Erkrankungen des Darmes und de Peritoneum.
82. Oehler, J. Ueber Rectumcarcinome. *Beitr. z. klin. Chir.*, Tübing., 1913, lxxxviii, 593–630.
83. Orth, L. Ueber die Sarkome des Darmes, Mesenteriums und retroperitonealen Raums. Inaugural Dissertation. Heidelberg, 1890.
84. Oseki, S. Polyposis intestini adenomatosa mit Carcinoma recti. *Deutsche Ztschr. f. Chir.*, Leipz., 1912, cxviii, 463–472.
85. Paneth, J. Ueber einen Fall von melanotischem Sarcom des Rectums. *Arch. f. klin. Chir.*, Berl., 1883, xxviii, 178.
86. Pennington, J. R. Carcinoma of the rectum and pelvic colon. *J. A. M. A.*, Chicago, Nov. 25, 1922, lxxix, 1829–1830.
87. Pennington, J. R. The end-results of operations for cancer of the rectum. *J. A. M. A.*, Chicago, 1918, lxxi, 1892–1897.
88. Petrow, N. W. Ein Fall von multiplen Polypen im Magen und Darm mit Übergang in Carcinom. *Centralbl. f. Chir.*, Leipz., 1896, xxix, 542.
89. Phifer, C. H. Cancer of the rectum and sigmoid in childhood and adolescence. *Ann. Surg.*, Phila., 1923, lxxvii, 711–720.
90. Philipp, P. W. Ueber Krebsbildungen im Kindesalter. *Ztschr. f. Krebsforsch.*, Berl., 1907, v, 326–416.
91. Pick, E. Primäres Sarcom des Dünndarms. *Prag. med. Wchnschr.*, 1884, ix, 96–98.
92. Pitt, G. N. *Tr. Path. Soc. Lond.*, 1889, xl.
93. Poirier, P., and Cuneo, B. The Lymphatics. 1913, p. 186–191. (Trans. by Leaf, C.)

94. QUÉNU, E., and HARTMANN, H. Sarcomes mélaniques du rectum. Chirurgie du Rectum. Paris, 1899, ii, 344.
95. QUÉNU, E., and LANDEL, G. Cancers du rectum et de l'anse sigmoide avec polyposi du gros intestini. *Rev. de chir.*, Paris, 1899.
96. QUICK, D. The treatment of cancer of the rectum by radium. *Am. J. Roentgenol. & Rad. Therap.*, N. Y., Dec., 1921, n.s., viii, 746–755.
97. RADEMACHER, B. Das primäre Sarkom des Dünndarms, etc. (Inaugural Dissertation, Jena.) Berl., 1908.
98. RAY, J. H. A case of acute intussusception of the sigmoid colon due to a subserous polypoid lipoma, etc. *Lancet*, Lond., 1905, i, 507. Also *Med. Chron.*, Manchester, 1904–1905, xiii, 370–378.
99. RICHARDSON, M. H. Tumor of caecum causing intussusception, etc. *Tr. Am. Surg. Ass.*, Phila., 1892, x, 205–209.
100. ROSENHEIM. In Eulenburg, A. Real-Encyclopädie der gesammten Heilkunde. Ed. 3, Wien u. Leipz., 1893. (Article on Tumors of the Intestine.)
101. SANDNER, F. Ein Fall von primärem Melanosarcom des Rectums. Inaugural Dissertation. Erlangen, 1904.
102. SCHLIEPS, W. Ueber das primäre Carcinom des Jejunum und Ileum. *Beitr. z. klin. Chir.*, Tübing., 1908, lviii, 722–761.
103. SCHÖNING. See Nothnagel, H. Ref. 80.
104. SCHÜMANN, E. Ueber das Sarcoma recti. *Deutsche Ztschr. f. Chir.*, Leipz., 1909, ii, 422.
105. SMOLER, F. Zur Kentniss des primären Darmsarcome. *Prag. med. Wchnschr.*, 1898, xxiii, No. 13, 14.
106. STEINER, R. Ueber Myome des Magen-Darmkanals. *Beitr. z. klin. Chir.*, Tübing., 1898, xxii, 1; 407.
107. STERN. See Nothnagel, H. Ref. 80.
108. STÖHR, P., and LEWIS, F. T. A Text Book of Histology. Ed. 2, Phila., 1913, p. 245.
109. STOERK, O. Zur Pathologie des gastro-intestinalen adenoiden Gewebes. *Wien. klin. Wchnschr.*, 1904, xvii, 91–96.
110. SYMINGTON. Quoted from Gray, H. *Op. cit.*
111. SYMMERS, D. Certain unusual lesions of the lymphatic apparatus. *Arch. Int. Med.*, Chicago, 1909, iv, 218–237.
112. THALHEIMER, W. Gas cysts of the intestine. *Proc. N. York Path. Soc.*, 1913, n.s., xiii, 5–12.
113. THOREBECKE, W. Über das familiäre Auftreten von Darmpolypen. *Deutsche Ztschr. f. Chir.*, Leipz., 1914, cxxvi, 553–578.
114. TRAPPE, M. Über geschwulstartige Fehlbildungen von Niere, Milz, Haut und Darm. *Frankf. Ztschr. f. Path.*, Wiesb., 1907, i, 109–123.
115. TREVES, F. Intestinal Obstruction. N. Y., 1899, p. 268.
116. TUFFIER. Contribution à l'étude du sarcome mélanique du rectum. *Arch. gén. de méd.*, Par., Jan., 1888, xxi, 28–38.
117. TUTTLE, J. P. Cancer of the rectum. *N. York M. J.*, Sept. 5, 1908, lxxxviii, 433–440.

118. Virchow, R. Pigment und diffuse Melanose der Arachnoides. *Virchow's Arch. f. path. Anat., etc.*, Berl., 1859, xvi, 180–182.
119. Voss. Lipom i Rektum med. Invagination af Tarmen. *Norsk Mag. f. Laegevidensk.*, Kristiania, 1880, s. 3, x, 618–621.
120. Ward, S. B. Lipoma of the intestine. *Albany M. Ann.*, 1904, xxv, 14–28.
121. Warren, J. C. Sarcoma of the mesentery of the cecum. *Boston M. & S. J.*, 1898, cxxxviii, 177–178.
122. Whipham, T. R. C. A case of primary carcinoma of the vermiform appendix. *Lancet*, Lond., 1901, i, 319–320.
123. Wiener, G. Ueber ein Melanosarkom des Rectums und die melanotischen Geschwülste im Allgemeinen. *Beitr. z. path. Anat. u. z. allg. Path.*, Jena, 1899, xxv, 322.
124. Williams, J. W. Myoma sarcomatodes uteri; sarcoma mucosae uteri et myomata uteri; melano-sarcoma corporis et cervicis uteri. *Ztschr. f. Heilk.*, Berl., 1894, xv, 140–184.
125. Winkler, K. Untersuchungen über das Wachstum und die Verbreitung des Mastdarmkrebses. *Beitr. z. klin. Chir.*, Tübing., 1924, cxxxi, 112–128.
126. Zinner, A. Ueber den Mastdarmkrebs. *Arch. f. klin. Chir.*, Berl., 1909, xc, 933–988.

The following authors have also been freely consulted:

Aschoff, L. Pathologische Anatomie. Leipz., 1921.
Delafield, F., and Prudden, T. Text Book of Pathology. N. Y., 1922.
Gaylord, H. R., and Aschoff, L. The Principles of Pathological Histology. Phila. & N. Y., 1901.
Hewlett, R. T. Pathology, General and Special. Lond., 1923.
Lubarsch, O. Die Allgemeine Pathologie. Wiesb., 1905.
MacCallum, W. G. A Text-book of Pathology. Ed. 3. Phila., 1924.
Ribbert, H. Lehrbuch der allgemeinen Pathologie. Leipz., 1923.
Schmaus, H. Grundriss der pathologischen Anatomie. Wiesb. 1919.
Ziegler, E. General Pathology. N. Y., 1921.

INDEX OF NAMES

ADAMI, 235

Albu, 42
Allingham, 97
Amster, J. L., 55, 61, 127
Anderson, F. W., 243
Anschutz, 106, 110, 111, 243
Arzt, 242
Aschoff, L., 56, 248
Ashton, 231
Ayer, 241

BAILEY, F. R., 227, 243

Baish, 112
Baltzer, M., 208, 222, 224, 243
Barker, 239
Barner, 231
Basso, 238
Batzdorff, E., 243
von Beesten, C., 238, 243
Bernouille, E., 101, 243
Bilton, vii
Bland-Sutton, J., 50
Blauel, 222, 243
Boas, I., 111, 243
Boettcher, A., 236, 243
Bonnet, P., 232, 233, 234, 243
Borst, 236
Bowing, H. H., 207, 243
Boyd, W., 230, 243
Breuer, 231
Brill, 110
Briquet, P., 227, 243
Brugnone, 231

CANNON, W. B., 28, 243

Carman, R. D., 130, 131, 243
Carrington, 227
Chalier, A., 232, 233, 234, 243
Cheatle, G. L., 69, 243
Ciechomski, A., 232, 243
Clar, 101, 243
Clogg, H. S., vii
Cohen, 237
Cole, P. P., 27, 110, 243
Cripps, H., 13, 94, 100, 243
Crowther, C., 222, 243
Cruveilhier, J. C., 243
Cuneo, B., 203, 246
Curling, 231
Czerny, 97, 243

DE BOVIS, vii

Debrunner, A., 222, 244
Delafield, F., 248
Dewis, J. W., 229, 234, 236, 237, 238, 240, 244
Dobson, J. F., vii, 22, 191, 197, 244, 245
Doering, H., 94, 95, 244
Dupuytren, G., 13, 245

EDWARDS, 107

Ehrlich, 234, 244
Elting, A. W., 244
Ewing, J., 3, 34, 43, 50, 77, 86, 221, 222, 232, 234, 235, 236, 244

FELSEN, 22, 50, 56, 130, 193

Fineman, S., 130, 131, 243
Fränkel, E., 24, 244
François-Dainville, E., 232, 244

GANT, S. G., 107, 244

Garrard, W. A., 101, 244
Gaylord, H. R., 248
Goeckel, M., 106, 244
Graves, S., 222, 244, 228
Gray, H., 13, 20, 244

HADDEN, 227

Handley, W. S., 28, 244
Hartmann, H., vii, 113, 232, 244, 247
Hartwell, J. A., 113, 244
Hauser, G., 42, 94, 244
Hertz, A. F., 28, 29, 244

Heurtaux, A., 226, 235, 244
Hewitt, J. H., 244
Hewlett, R. T., 248
Hiller, T., 234, 244
His, 5
Holfelder, 215
Hollander, 238
Howard, W. T., 244

JAMIESON, J. K., vii, 22, 191, 197, 244, 245
Jansen, 229, 245
Jones, 113
Jopson, J. H., 222, 223, 225, 226, 245

KAUFMAN, 42, 110
Keith, 29
Kelly, A. O. J., 245
Kelly, H. A., 215, 245
Key, E., 222, 245
Konig. 238
Konjetzny, G. E., 245
Körte, W., 106, 110, 111, 245
Kraske, P., 89, 106, 245
Krehl, L., 53
Krische, 238
Krogius, A., 241, 245
Krueger, 224
Kuttner, H., 213

LAËNNEC, 231
Lagutière, 245
Landel, G., 95, 247
Langerhans, R., 43, 238, 245
Le Garde, 235
Lewis, F. T., 5, 26, 247
Libman, 222, 224
Lisfranc, J., 13, 245
Lode, A., 236, 245
Lonart, A. E. F., 101, 245
Lubarsch, O., 3, 42, 43, 94, 245, 248
Lusk, W. C., 112, 245
Lynch, J. M., 94, 97, 100, 106, 107, 112, 149, 213, 216, 245

MACCALLUM, W. G., 248
McGrath, B. F., 88, 245
McVay, I. R., 69, 245
McWilliams, C. A., 53, 245
Madelung, 235
Majerus, F., 213, 246
Mallory, 221, 241
Marchand, F., 53
Martin, J., 232, 246
Maver, 228
May, E. A., 207, 215, 246
Mayo, W. J., 97, 110, 246
Meurier, 242
Miles, 77
Mollière, 231
Moore, 231
Moritz, 228
Moschcowitz, A. V., 246
Moser, 238, 246
Moynihan, 214
Mummery, J. P. L., 29, 42, 43, 76, 77, 94, 107, 112 133, 164, 176, 214, 246

NAZZARI, 236
Neugebauer, F., 246
Niemack, J., 42, 94, 246
Nothnagel, H., 101, 111, 224, 246

OEHLER, J., 69, 100, 106, 110, 246
Orth, L., 222, 246
Oseki, S., 89, 95, 246

PANETH, J., 225, 231, 246
Paul, 154
Pennington, J. R., 69, 97, 101, 107, 110, 113, 213, 246
Peterman, 110, 111
Peterson, 231
Petrow, N. W., 42, 94
Phifer, C. H., 101, 246
Philipp, P. W., 101, 246
Pick, E., 222, 246
Pitt, G. N., 222, 227, 246
Poirier, P., 203, 246
Pollard, vii
Powell, 131
Prudden, T., 3, 248

QUÉNU, E., 93, 95, 232, 247
Quick, D., 208, 215, 247

RADEMACHER, B., 222, 247
Raecke, 232
Rawling, 110
Ray, J. H., 235, 247
Ribbert, H., 3, 237, 248
Richardson, M. H., 235, 247
von Rindfleisch, 3
Rives, 232, 246
Rosenheim, 225, 247

SANDNER, F., 232, 247
Sappey, 28
Schlieps, W., 110, 247
Schmaus, H., 248
Schöning, 97, 247
Schümann, E., 232, 247
Sigerist, 232
Smith, A. J., 34, 94
Smoler, F., 222, 224, 247
Steiner, R., 236, 247
Stern, 97, 247
Sternberg, 228
Stöhr, P., 5, 26, 247
Stoerck, O., 227, 228, 247
Symington, 247
Symmers, D., 227, 247

THOREBECKE, W., 42, 94, 95, 247
Thyng, 5
Trappe, M., 237, 247
Treves, F., 224, 247
Tuffier, 231, 232, 247
Tuttle, J. P., 106, 107, 112, 149, 150, 174, 213, 214, 215, 216, 247

VERSE, 42
Viborg, 231
Virchow, R., 43, 213, 248
Voss, 235, 248

WALDEYER, 235
Ward, S. B., 209, 215, 234, 248
Warren, J. C., 226, 248
Wells, 228
Whipman, T. R., 248
White, C. Y., 50, 222, 223, 225, 226, 245
Wiener, G., 232, 248
Williams, J. W., 238, 248
Wilson, 88
Winkler, K., 248
Wood, F. C., 53

ZIEGLER, E., 248
Zimmerman, 231
Zinner, A., 69, 213, 216, 248
Zum-Busch, 235

INDEX OF SUBJECTS

ABDOMINOPERINEAL excision, 167

Adenocarcinoma, 61, 65, 71, 73, 75, 79, 81, 83, 85, 99, 103, 105, 109, 117, 120, 123, 125, 127, 129, 135, 137, 139, 141
  eosinophilic infiltration in, 52
  gelatinous, 87
Adenoma, 42–50
  atypical, 43
  destruens, 63, 68, 86
  of rectum, treatment of, 145
  origin of, 42
  papillary, 43, 45
  parts affected by, 42
  pathology, gross, 42
    microscopic, 43
  polypoid, 39, 41, 45, 63
    classification of, 49
    seats of, 42
    treatment of, 95
    without symptoms, 96
  treatment of, 145
  villous, treatment of, 145
Adenomata, multiple, 49
After-treatment in complete perineal resection of rectum, 164
Age factor in carcinoma, 97, 100
    in lymphosarcoma, 225
    in melanoblastoma, 232
    in papilloma, 94
Anal canal, gross anatomy of, 14–15
  warts, 93, 145
Anastomosis of arteries in colon, 21
Anatomical conditions as factors in production of carcinoma, 106
  considerations of lymphatic area in ileocecal region, 191
    in colon, 195
Anatomy of colon and rectum, 11–30
  applied, 24
  gross, 11
  microscopic, 26
Anesthetic, choice of, in perineal resection of rectum, 157
Angioma, 239
  pathology of, 239
Anus, lymphatic supply of, 23, 197
  nerve supply of, 30
Appendix, carcinoma of, 53, 55
  classification of 71 cases, 53
  growth, 53
  heterotopic groups of cells in, 56
  location, 53
  microscopic appearance, 53
  structure, 53
Arteries of colon, 19–21
  anastomosis of, 21
Ascending colon, gross anatomy of, 11
Atypical character of cells in carcinoma, 51
  lymphoid tumors of large intestine, 228

BARIUM enema, constituents of, 132
    in roentgen-ray diagnosis of tumor of colon, 130
Barium-meal examination in roentgen-ray diagnosis of tumors of colon, 130
Benign tumors, 93
    pre-existing, as factor in production of carcinomata, 106
    résumé of, 239
Blood supply of colon and rectum, 14
Bloody stool as symptom of carcinoma, 112

CARCINOMA, 50–89
  advance along lymphatics, 76, 77
  age of incidence of, 97, 100
  associated with diverticulum of colon, 88
  at ileocecal junction, 86
  cells, atypical, 51
    desmoplastic properties of, 52
    loss of polarity of, 52
    overgrowth of, 51
  cicatricial character of many, 51
  degenerative changes in, 51
  diagnosis of, 112
    by digital examination, 113
    by ocular examination, 113
    by palpation, 113
    importance of early, 112, 217
  distribution of, in large intestine, 110
  duration of symptoms, 106
  equilibrium between epithelium and connective tissue in, 51

Carcinoma, etiology of, 106
extent of tumor mass, 107
general pathological considerations, 51
gross appearance of, 76
characteristics of, 50
heterotopia in, 51
hyaline swelling of fibrous tissue in, 51
in upper colon, operative treatment of, 184
indications for operation in, 145
induration in, 51
intestinal obstruction in, 89
invasive properties of, 52, 69, 76, 77
involvement of lymph nodes in, 69, 76, 77
laboratory aids in diagnosis of, 130
lymph-node enlargement in, 51
melanoma, 89
microscopic appearance of, 51
non-operative treatment, 207–211
of appendix, 53. *See also* Appendix, carcinoma of.
of large intestine, origin of, 56
spread, 69
of rectum, removal by abdominal route, 177
of sigmoid, 86
of transverse colon, 86
palliative treatment of, 209
pathological changes in, 50
pathology of, 50
power to produce distant metastatic tumors, 52
radiation treatment of, results of, 215
rectal, methods of extension, 77
recurrent, 52, 76
remote results of, 89
results of various methods of treatment of, 113–217
scirrhous, 87
secondary results of, 133
sex factor in, 106
site of, 107
squamous-cell, 87
surgical curative treatment in cecum, 185
in hepatic flexure, 184
in rectum, 157
in sigmoid, 177
in splenic flexure, 184
in transverse colon, 184
symptoms and signs of, 111
blood in stool as, 112
diarrhea as, 111
duration of, 106
obstruction as, 112
pain as, 106
tendency for more extensive involvement of deeper layers, 69
Carcinoma, treatment of, curative, 145
types, 86
Cause of tumors, three elements in, 221
Cecostomy, 153
Cecum, carcinoma of, surgical treatment of, 185
lymphosarcoma of, 228
Cell types in tumors of colon and rectum, 4
Cells in carcinoma, atypical qualities, 51
desmoplastic properties, 52
loss of polarity in, 52
overgrowth, 51
eosinophilic infiltration of, in adenocarcinoma, 51
Cicatricial character of many carcinomata, 51
Clinical aspects of adenoma, 49
of angioma, 239
of carcinoma, 93
of fibroma, 230
of leiomyoma, 238
of lipoblastoma, 235
of lymphosarcoma, 224
of melanosarcoma, 232
of papilloma, 35
of pseudoleucemia, 227
Closure of colostomy wound, 154
Coccygeus, 19
Colectomy, 185
Colitis polyposa, 42
cystica confused with benign polyp or polypoid adenoma, 43
Colon, anatomy of, applied, 24–25
gross, 11–24
arterial supply of, 19–21
as site of neoplastic disease, 3
ascending, gross anatomy of, 11
descending, gross anatomy of, 12
development of, 4–8
fibromatosis of, 230
histological structure of, 26–27
of mucosa, 26
of muscularis, 27
of serosa, 27
of submucosa, 26
lymphatic area of, anatomical considerations, 195
surgical considerations, 200
vessels of, 21–23
microscopic study of, 27
microscopic anatomy of, 26–28
movement in, 29
nerve supply of, 23, 29
operative treatment of carcinoma in upper, 184
palliative treatment of carcinoma of, 209
physiology of, 28–30

Colon, physiology of, food, time required for passage of, 28–29
pigmentation of, 50
sigmoid flexure, gross anatomy of, 12
splenic flexure, gross anatomy of, 12
transverse, gross anatomy of, 11
venous supply, 21
Colostomy, 210
closure of wound, 154
extraperitoneal, 154
inguinal, 146
method of Lynch, 149
of Tuttle, 149, 150
intraperitoneal, 154
lumbar, 150
method of Paul, 154
preliminary, 146
transverse, 150
Combined operation, 167
final steps in, 176
methods, 167, 168, 173
Tuttle's three-step, 174
preparation of patient for, 168
Course, clinical, of lymphosarcoma, 226
Cure, surgical, of carcinoma, permanency of, 214
Curettage, 210
Cutaneous wart, 35
Cysts, 241
arising from glandular structures, 241
due to degenerative change, 241
gas, 241
parasitic, 241

DEFECATION, normal, 29

Degenerative changes in carcinoma, 51
Descending colon, gross anatomy of, 12
Desmoplastic properties of cells in carcinoma, 52
Development of colon and rectum, 4
Developmental anomalies as factor in production of carcinoma, 106
Diagnosis, necessity for early, 112, 217
of carcinoma, importance of early, of the colon, 217
of the rectum, 112, 217
of epithelial tumors, laboratory aids in, 130
of melanoblastoma, 234
of tumors of colon, barium enema in roentgen-ray, 130
barium-meal in roentgen-ray examination in, 130
roentgen-ray in, 130
Diarrhea as symptom of carcinoma, 111
Diathermy in the palliative treatment of carcinoma, 210
Diet, 209
Digestion, time required for intestinal, 28
Diverticula with associated carcinoma, 88
Drugs in the palliative treatment of carcinoma, 210

ENDOTHELIAL cells as cause of tumor, 221

Enema, barium, in roentgen-ray diagnosis of tumor of colon, 130
Eosinophiles, infiltration by, in adenocarcinoma, 52
Epithelial tumors, *see also* Neoplasms.
clinical aspects of primary, 93–141
laboratory aids in diagnosis of, 130
primary, 33–95
surgical treatment of, 145–188
Examination in diagnosis of carcinoma, digital, 113
ocular, 113
of rectum, digital, 24
proctoscopic, 25
roentgen-ray, in diagnosis of tumors of colon, 130
Excision, abdominoperineal, 167
of lymphatic areas draining malignant neoplasms, 189–204
Extent of carcinoma, 107

FASCIA, anal, 19

Fasciae of pelvic outlet, 15–19
anal, 19
pelvic, 17
superficial, 15
triangular ligament, 15
Fibroblastoma, 229
Fibroma, 229
pathology of, 229
varieties of, 229
Fibromatosis of colon, 230
Fibrosarcoma, 230
pathology of, 230
Food, time required for passage through parts of large intestine, 28–29
Frequency of sarcoma, 222

GAS cysts, 241

Gastrointestinal pseudoleucemia, 227
Gelatenous adenocarcinoma, 87
Growth of carcinoma of appendix, 53

HEPATIC flexure, carcinoma of, surgical treatment, 184
Heterotopia in carcinoma, 51
Heterotopic cells in carcinoma of appendix, 56
Hodgkin's disease, 229
Hyaline swelling of fibrous tissue in carcinoma, 51
Hypodermoclysis in complete perineal resection of rectum, 164

ILEOCECAL junction as seat of carcinoma, 86

Induration in carcinoma, 51
Inflammatory conditions, chronic, as factors in production of carcinoma, 106
Inguinal colostomy, 140
Inhibitory nerves of colon, 29
Intermediate groups of lymph nodes, 23, 197
Intestine, indications for resection of, 145
Invasive and destructive properties of carcinoma, 52
Involvement of lymph nodes in carcinoma of large intestine, factors in, 69, 214
Ischiorectal fossa, 19

LABORATORY aids in diagnosis of epithelial tumors, 130
Leucemic lymphoma, 228
  pathology of, 228
Leucosarcoma, 228
Levator ani, 18
Ligament, triangular, 15
Liomyoblastoma, 236
Liomyoma, 236
  associated with uterine fibromyoma, 237
  microscopic appearance, 237
  pathology of, 236
Lipoblastoma, 234
  age, 235
  characteristics, 235
  pathology of, 235
Lipoma, 234. *See also* Lipoblastoma.
Location of lymphosarcoma, 224
  of melanosarcoma, 232
Lumbar colostomy, 150
Lymph nodes, 23, 192
    enlargement of, in carcinomatous ulcer, 51
    involvement in carcinoma, 69
Lymphatic area of anus, 203
    of colon, anatomical considerations of, 195–200
        arteries, 196
        lymph nodes, 197
        veins, 197
      surgical considerations of, 200
Lymphatic area of colon, surgical considerations of,
        ascending colon, 200
        descending colon, 201
        sigmoid, 201, 202
        splenic flexure, 200
        transverse colon, 200
        upper rectum, 186
    of ileocecal region, 191
      anatomical considerations of, 191
        nodes, 192
      surgical considerations of, 194
    of rectum, 203
  areas draining malignant neoplasms, excision of, 191–204
  vessels in wall of large intestine, 28
    of anus, 23
    of colon, microscopic study of, 27
Lymphoblastoma, 221, 222
  age, 225
  clinical course, 226
  frequency, 222
  location, 224
  metastatic deposits, 226
  origin, 221
  pathology, 222
  prognosis, 226
  sex, 225
  symptoms and signs, 225
  treatment, 226
Lymphocytoma, malignant, 222
Lymphoid tumors of large intestine, atypical, 228
Lymphoma, leucemic, 228
Lymphosarcoma, 221
  age of incidence of, 225
  characteristics of, 223
  clinical aspects of, 224
  course of, 226
  location of, 224
  metastatic deposits in, 226
  of cecum, 228
  of intestine, 222
    frequency of, 222
    pathology of, 222
  prognosis of, 226
  sex factor in, 225
  symptoms of, 225
  treatment of, 226
Lynch's method of inguinal colostomy, 146

MALIGNANT neoplasms, excision of lymphatic areas draining, 188, 191–204
Melanoblastoma, 231

Melanoblastoma, age, 232
diagnosis, 234
location, 232
pathology, 232
pigmentation in, 233
sex factor, 232
size, 232
symptoms, 234
treatment, 234
Melanoma, 89, 231
Melanosarcoma, 231. *See also* Melanoma, Melanomata.
pathology of, 232
Melanosis, 50
Metastatic deposits in carcinoma, 69
in lymphosarcoma, 226
tumors, distant, produced by carcinoma, 52
Methods of treatment of carcinoma, results of various, 213–217
Mortality in surgical treatment of carcinoma, 214
Motor nerves of colon, 29
Movement in colon, type of, 29
Mucosa, absence of pain in, in colon and upper rectum, 25
coat of colon, 26
of rectum, 28
Multiple poliposis, *see* Polyposis, multiple.
Muscles of pelvic outlet, 15–19
coccygeus, 19
levator ani, 18
obturator internus, 19
piriformis, 19
Muscular coat of colon, 27
of rectum, 28
Myomata, age, 238
location, 238
regressive changes in, 238
types, 236
Myxosarcoma, 231

NEOPLASMS, malignant, excision of lymphatic areas draining, 191–204
primary, other types of, 221–242
Neoplastic disease, definition of, 3
Nerve supply of anus, 30
of colon, 23, 29
of rectum, 30
Non-operative treatment of carcinoma, 207–210

OBSERVATIONS on pigmentation of the colon (Felsen), 50
Obstruction of intestine in carcinoma, 89, 112
Obturator internus, 19
Operation, combined, for carcinoma of rectum, 167
indications for resection, 145

PAIN, absence of, in mucosa of colon and upper rectum, 25, 30
as symptom of carcinoma, 112
referred, 25
Palliative treatment of carcinoma, 145, 209
diet, 209
drugs, 210
mechanical measures, 210
surgical procedures, 210
Palpation in diagnosis of carcinoma, 113
Papillary adenoma, *see* Adenoma, papillary.
Papilloma, 33–39
cutaneous warts, 35
description of, 33–35
pathology of, 35
villous, 93
Paracolic lymph nodes, 23, 197
Parasitic cysts, 241
Pathology, gross, of adenoma, 42
of anal wart, 35
of angioma, 239
of carcinoma, 50
of fibroma, 229
of fibrosarcoma, 230
of leiomyoma, 236
of leucemic lymphoma, 228
of lipoblastoma, 235
of lymphoblastoma, 222
of melanosarcoma, 232
of pseudoleucemia, 227
microscopic, of adenoma, 43
of anal wart, 35
of angioma, 239
of carcinoma, 51–56
of fibroma, 230
of fibrosarcoma, 241
of leiomyoma, 237
of leucemic lymphoma, 228
of lipoblastoma, 236
of lymphoblastoma, 222
of melanosarcoma, 233
of pseudoleucemia, 227
Paul's colostomy method, 154
Pelvic fascia, 17
outlet, muscles and fasciae of, 15–19
Peridiverticulitis roentgenologically simulating carcinoma, 132
Peristalsis, 29

Permanency of surgical cure of carcinoma, 214
Physiology of colon and rectum, 28–30
Pigmentation in melanoblastoma, 233
  in polypoid adenoma, 96
  of colon, 50
    associated with adenoma, 96
Piriformis, 19
Plexus, lymphatic, beneath mucosa, 28
  subserous, 28
Polarity of cells in carcinoma, loss of, 52
Polyp, simple, 37
Polypi, in multiple polyposis, 94
  multiple adenomatous, 49, 50
  true multiple adenomata associated with hyperplastic tuberculosis, 50
    with old stricture, 50
    with ulcerative colitis, 50
Polyposis, adenomatous, *see* Adenoma, polypoid.
  multiple, 42, 94
Preliminary colostomy, 146
Preparation of patient for combined operation, 146, 168
    for complete perineal resection of rectum, 158
    for perineal resection, 146, 157
Primary epithelial tumors of the colon and rectum, 33–89
    pathological aspects, 33
  neoplasms, other types of, 221–242
Prognosis in lymphosarcoma, 226
Pseudoleucemia, gastrointestinal, 227
    characteristics of, 227
    microscopical appearance, 227
    pathology of, 227

RADIATION treatment of carcinoma, results of, 215
Radium treatment of carcinoma, 207, 208
    effects, 209
    methods of application, 208, 209
Recovery of tumor fragments in the feces (Felsen), 130
Rectum, abdomino-perineal resection of, 167
  anatomy of, applied, 24–25
    gross, 13–24
      of anal canal, 14–15
    microscopic, 26–28
  as site of neoplastic disease, 3
  carcinoma of, surgical treatment, 157
  coats of, 28
  complete perineal resection of, 157–167
  development of, 4–8
  lower, anatomy of, 14
Rectum, lymphatic supply of, 23, 203
  nerve supply, 30
  palliative treatment of carcinoma of, 209
  perineal resection of, 157
  physiology of, 28–30
Resection of intestine, general considerations, indications for operation, 145
  of rectum, complete perineal, 157–167
      after-treatment in, 164
      anesthetic for, choice of, 157
      hypodermoclysis in, 164
      preliminary preparations for, 158
    Mummery's method, 176
  of sigmoid, 177
Results of various methods of treatment of carcinoma, 213–217
Reticulum cells as cause of tumor, 221, 222
  of lymphosarcoma, 222
Roentgen-ray examination in diagnosis of tumors of colon, 130
  treatment of carcinoma, 207
    effects, 209

SARCOMA, large round-cell, 222
Scirrhous carcinoma, 87
Serosa coat of colon, 27
    of rectum, 28
Sex factor in carcinoma, 106
    in lymphosarcoma, 225
    in melanoblastoma, 232
Sigmoid, carcinoma of, surgical treatment, 177
Sigmoid flexure, gross anatomy of, 12
Sigmoidoscope, electric, in diagnosis of carcinoma, 113
Site of carcinoma, 107
Sphincters, 14
Splenic flexure, carcinoma of, surgical treatment, 177
    gross anatomy of, 12
Squamous-cell carcinoma, 87
Structure of carcinoma of appendix, 53
Submucosal coat of colon, 26
    of rectum, 28
Subserous plexus, 28
Surgical considerations in removal of lymphatic area
    of ileocecal region, 194
    of colon, 200
  cure of carcinoma, permanency of, 214
  procedures in palliative treatment of carcinoma, 210
      colostomy, 210
      curettage, 210

Surgical procedures in palliative treatment of carcinoma, diathermy, 210
results of, 213
mortality, 214
Symptoms of carcinoma, 111
duration of, 106
of lymphosarcoma, 225
of melanoblastoma, 234

THREE-STEP method for combined operation, Tuttle's, 167
Transfusion, method used in preparation for intestinal resection, 164
Transverse colon, carcinoma of, surgical treatment, 184
gross anatomy of, 11
colostomy, 150
Trauma as factor in production of carcinoma, 106
Treatment of adenoma, 145
of anal warts, 145
of benign tumors, 145
of carcinoma, 145–210
curative, 145
non-operative, 207–211
by diathermy, 210
by radium, 207
by roentgen ray, 207
results of, 215
palliative, 209
results of various methods of, 213–217
surgical, results of, 213
of liomyoma, 238
Treatment of lymphosarcoma, 226
of melanoblastoma, 234
of polypoid adenoma, 95
of primary epithelial tumors, 145–188
Triangular ligament, 15
Tuberculosis roentgenologically simulating carcinoma, 132
Tumors, atypical lymphoid, of large intestine, 228
benign, 93–97, 145
of colon, roentgen-ray examination in diagnosis of, 130
of large intestine, classification according to cells of origin, 3–4
primary epithelial, 33–89
treatment of, 145–188
Tuttle's method of inguinal colostomy, 149,150
three-step method for combined operation, 167

VENOUS supply of colon, 21

Villous adenoma, 145
papilloma, 93
tumors, 43
classification of, 34
Virulence of carcinomata, degrees of, 214

WART, anal, 93
treatment of, 145
cutaneous, 35
Wound, closure of colostomy, 154

PAUL B. HOEBER, INC., 67-69 East 59th Street, New York

3 2044 062 561 501

CALL (617) 432-2136 TO RENEW
HAVE ID NUMBER OR BOOK BARCODE
or
email to: librenew@hms.harvard.edu

COUNTWAY LIBRARY
HC 5400 G
3 2044 062 561 501